



## Get Clarity On Generics

Cost-Effective CT & MRI Contrast Agents



FRESENIUS  
KABI

WATCH VIDEO

# AJNR

## **Successful Thrombectomy in Acute Terminal Internal Carotid Occlusion Using a Basket Type Microsnare in Conjunction with Temporary Proximal Occlusion: A Case Report**

This information is current as of August 25, 2025.

Keisuke Imai, Takahisa Mori, Hajime Izumoto and Masaki Watanabe

*AJNR Am J Neuroradiol* 2005, 26 (6) 1395-1398  
<http://www.ajnr.org/content/26/6/1395>

## Successful Thrombectomy in Acute Terminal Internal Carotid Occlusion Using a Basket Type Microsnare in Conjunction with Temporary Proximal Occlusion: A Case Report

Keisuke Imai, Takahisa Mori, Hajime Izumoto, and Masaki Watanabe

**Summary:** Recanalization therapy is controversial in patients with acute stroke due to terminal internal carotid artery (ICA) occlusion. A 78-year-old man underwent successful percutaneous transarterial microsnare-assisted thrombectomy (PMT) for the treatment of acute terminal ICA occlusion, which was recanalized completely. This case report suggests that PMT is a potential treatment for patients with acute embolic occlusion of the terminal ICA.

Thrombolytic therapy is controversial in patients with acute stroke due to terminal internal carotid artery (ICA) occlusion, because the recanalization rate for such treatment is low (1). A few previous studies have described endovascular techniques, such as mechanical clot disruption or endovascular thrombectomy for the treatment of acute embolic stroke (2–7). We report a case of acute embolic occlusion of the terminal ICA treated successfully with percutaneous transarterial microsnare-assisted thrombectomy (PMT) without the use of thrombolytic agents.

### Case Report

A 78-year-old man with uncontrolled atrial fibrillation and hypertension presented with sudden-onset left-sided weakness and difficulty speaking. On physical examination, he was in a somnolent state and had left hemisomatognosia, a rightward gaze preference, left hemiplegia involving the face, and left sensory deficits. His National Institutes of Health Stroke Scale (NIHSS) score was 19. Diffusion-weighted MR images (DWIs) showed mild high-signal intensities extending from the right basal ganglia to the periventricular corona radiata, MR angiograms revealed a right ICA occlusion, and perfusion-weighted MR images demonstrated a decrease of cerebral blood flow on the right hemisphere. Cerebral angiography following the MR examinations confirmed the presence of a terminal right ICA occlusion (Fig 1A) with clot extending from the terminal ICA through the proximal middle cerebral artery (MCA). Both the left ICA angiogram and the left vertebral artery

angiogram showed no filling of the right anterior cerebral artery (ACA) or MCA.

Because pharmacologic thrombolysis and balloon angioplasty of terminal ICA occlusions are controversial, a transarterial clot removal was attempted to achieve recanalization after written informed consent was obtained from his family. Endovascular treatment was started 230 minutes after the onset of symptoms. Systemic anticoagulation was initiated by the intravenous administration of a bolus of heparin to achieve an activated clotting time >250 seconds during the procedure. Transfemoral catheterization was performed after placement of a 9F sheath, and a 9F guiding catheter with coaxial balloon (PATLIVE; Clinical Supply, Gifu, Japan) was placed by exchange-technique in the right ICA. A 2.3F microcatheter (Transit 2; Cordis Endovascular, Johnson & Johnson, New Brunswick, NJ) was then carefully advanced over a 0.016-inch microguidewire (GT wire; Terumo, Tokyo, Japan) across the clot in the terminal ICA to the insular segment of the MCA. A 3-mm-diameter microsnare (Soutenir; Soluton, Kanagawa, Japan) was then placed through the microcatheter and into the clot (Fig 1B).

The coaxial balloon on the guiding catheter was inflated and the proximal ICA was occluded (Fig 2A) while the microsnare basket was partially drawn back into the microcatheter to capture the clots without fragmenting them (Fig 2B, -C). The entire microsnare and microcatheter assembly was withdrawn completely through the guiding catheter. To facilitate removal of the clot, an introducer with a removable valve was used. No clot was captured with the microsnare basket, and the presumed clot in the guiding catheter was aspirated twice with a 20-mL syringe during proximal ICA blockade; however, no clot could be aspirated with the syringe.

A larger, 5-mm-diameter, microsnare was subsequently introduced in an identical fashion. As a result, a small clot was captured with the microsnare basket, and a large clot, >10 mm in length (Fig 3), was aspirated with the syringe. A slow injection of contrast medium during the proximal ICA blockade suggested recanalization of the ICA. The coaxial balloon on the guiding catheter was then deflated.

Carotid angiography showed complete recanalization of the ICA, MCA, and ACA without distal branch occlusion (Fig 1C). No spasm or dissection was seen in any artery. Intravenously administered heparin was discontinued when the procedure was complete, and the patient was monitored closely in the intensive care unit for 24 hours. Cranial CT scans obtained immediately after PMT showed no hemorrhagic transformation, and DWI performed 3 days after PMT revealed small high-signal intensity lesions in the right basal ganglia and periventricular corona radiata, which had not extended significantly compared with those on admission. Echocardiography revealed a dilated left atrium without residual thrombus. The patient improved immediately after the procedure and was discharged 10 days after the procedure with mild disability (NIHSS score of 2 and modified Rankin Scale score of 1).

Received August 13, 2004; accepted after revision September 22.

From the Department of Stroke Treatment (K.I., T.M., H.I.), Shonan Kamakura General Hospital, Kamakura, Japan, and the Department of Neurology (M.W.), Kumamoto University School of Medicine, Kumamoto, Japan.

Address correspondence to Takahisa Mori, MD, PhD, Department of Stroke Treatment, Shonan Kamakura General Hospital, 1202-1 Yamazaki, Kamakura 247-8533 Japan.

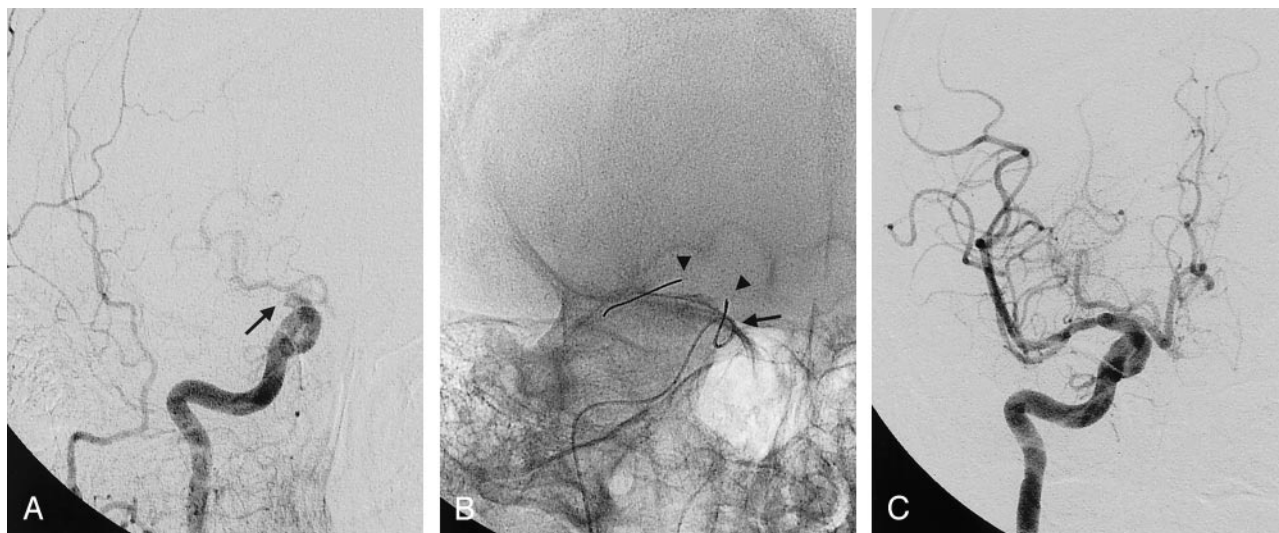


FIG 1. Anteroposterior right carotid angiogram.

A, Angiogram before the procedure showing total occlusion of the terminal internal carotid artery (arrow).

B, Angiogram during the procedure demonstrating the microsnare basket (arrowheads) at the level of the clot, which is protruding from the microcatheter tip (arrow).

C, Angiogram obtained after removal of the microsnare with the microcatheter and deflation of the coaxial proximal balloon showing that the clot has been removed, and normal flow has been reestablished in the previously occluded vessel without distal branch occlusion.

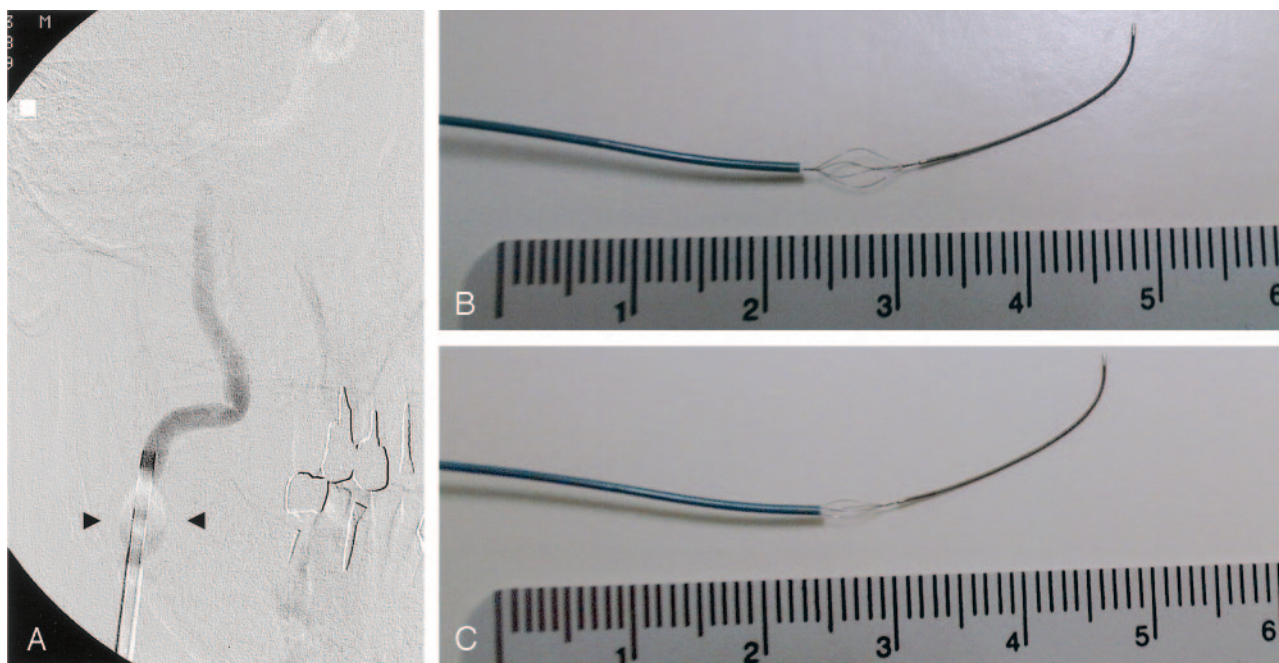


FIG 2. A, Anteroposterior right carotid angiogram showing proximal ICA blockade by inflation of the coaxial balloon (arrowheads) on the guiding catheter.

B and C, The microsnare is visualized after being deployed through the 2.3F microcatheter. The fully extended stainless basket of the microsnare is 5 mm in diameter, when the microsnare is protruded completely from the microcatheter (B) and is closed appropriately when it is partially withdrawn into the microcatheter (C). The scale is in centimeters.

## Discussion

Acute embolic occlusion of the terminal ICA results in a poor outcome in many patients, and it is technically difficult to achieve complete recanalization with intravenous or intraarterial thrombolytic therapy (1). Although a previous study reported that additional mechanical clot disruption with intracra-

nial balloon angioplasty following failed thrombolysis could achieve partial recanalization of the embolic occlusion of the terminal ICA, limited clinical improvement was achieved after the procedure (8). Recanalization might be beneficial in patient with acute ischemic stroke without extended high signal intensity on preprocedural DWI, because the lack of recanali-



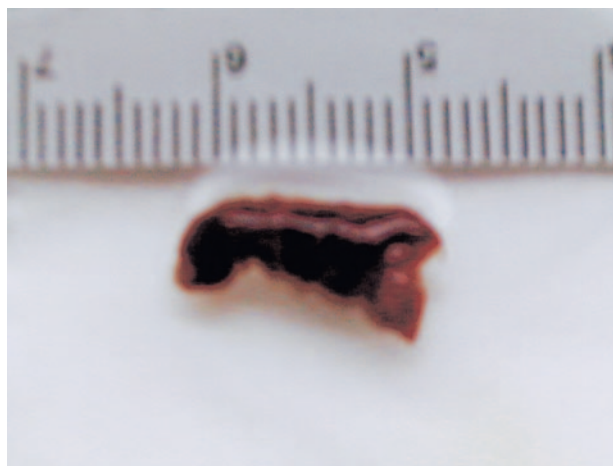


Fig 3. The extracted clot is >10 mm in length. The scale is in centimeters.

zation probably leads to high mortality and morbidity in those patients. Successful recanalization by pharmacologic thrombolysis or intracranial balloon angioplasty depends on the volume and composition of the clot in acute embolic stroke patients. Therefore, previous studies have described clot removal by PMT (3–7) or suction thrombectomy (9) in the treatment of acute ischemic stroke, and these strategies may capture large or partially organized hard clot, which can rarely be disrupted by thrombolysis or balloon angioplasty alone.

Microsnare have been used to retrieve foreign bodies, wires, and coils located inside the blood vessel. Qureshi et al (10) reported the efficacy of these devices to disrupt clots mechanically for the treatment of acute ischemic stroke patients. In the present case, however, the microsnare was used not to disrupt clots, but to retrieve them. Although the benefits of PMT in acute ischemic stroke have been anecdotally reported in previous studies (3–7), the present case may be the first report of successful PMT for embolic occlusion of the terminal ICA without the use of pharmacologic thrombolysis. Excellent clinical outcome is ascribed to the technique of proximal flow blockade to support retrieval of the clot and to avoid migration of captured clots, which was reported by Mayer et al (4) in the treatment of basilar artery embolism. Complete recanalization would not have been achieved in the present case without proximal ICA blockade, because the bulk of the clots were finally aspirated through the guiding catheter while flow in the proximal ICA was blocked, not by mechanical thrombectomy using the microsnare basket. The success rate of transarterial suction thrombectomy using a guiding catheter (9) may increase when the clots are extracted from the region from the terminal ICA to the proximal ICA by microsnare and the clots are near the tip of the guiding catheter. In addition, the technical success of PMT depends on snare type and size. The microsnare used in the present case is based on a stainless basket, not a small lasso, which has been designed to grasp objects by

using the endovascular approach. A basket diameter greater than that of the occluded vessel must be chosen to ensure complete clot entrapment, especially, when a smaller one has failed to capture the clots.

One of the potential advantages of PMT when compared with pharmacologic thrombolysis is the rapidity with which the vessel is opened. In the present case, no additional treatment was required to recanalize distal branch occlusion, and the time for obtaining an angiographic diagnosis and extracting the clots was 45 minutes, which is somewhat longer than that reported by Wikholm (7) because of the time required to prepare the proximal flow blockade system. The other potential advantage of PMT is the theoretically lower risk of symptomatic intracerebral hemorrhage due to the absence of a lytic state, and it can expand the time window for interventional stroke treatment. By contrast, the potential disadvantages of PMT are clot fragmentation with distal embolization, arterial dissection, perforation, or spasm. To avoid distal embolization during retraction of the clots, proximal flow blockade by inflation of the coaxial balloon on the guiding catheter and use of sufficient suction are necessary. Distal embolization often occurs in acute ischemic stroke patients undergoing angioplasty-assisted intraarterial thrombolysis, and, in such treatment, an intraarterial infusion of thrombolytic agents is thought to be useful to soften the clot for mechanical disruption and aid in the delayed thrombolysis of a distal thromboembolism (11). By contrast, primary use of the microsnare before pharmacologic thrombolysis or intracranial balloon angioplasty (4, 7) may be desirable in PMT because it will be difficult to capture soft, small clots arising from thrombolysis or angioplasty. To avoid the potential risk of vessel damage due to dissection, perforation, or spasm, careful and gentle catheter manipulation is essential, and the microcatheter should be navigated up to the distal portion of the clot, and the microsnare should be deployed through the microcatheter with an absolute minimum of manipulation.

## Conclusion

Because many factors—including the presence of collateral flow to the occluded vessel, the time to treatment, and the baseline neurologic severity—may influence clinical outcome in patients undergoing PMT, careful selection of the candidates is essential to obtain good clinical outcomes. Because of the relative rigidity of basket retrieval devices, their use for clot extraction in small cerebral branches may prove to be not feasible. Although the risks and benefits of PMT in the treatment of acute embolic stroke are unknown, the result in the present case suggests that PMT is feasible, safe, and effective in the treatment of patients with acute embolic occlusion of the terminal ICA and indicates a clinical trial in a larger number of patients would be important (12).

## References

1. Jansen O, von Kummer R, Forsting M, et al. **Thrombolytic therapy in acute occlusion of the intracranial internal carotid artery bifurcation.** *AJNR Am J Neuroradiol* 1995;16:1977–1986
2. Kuether TA, Nesbit GM, Barnwell SL. **Other endovascular treatment strategies for acute ischemic stroke.** *Neuroimaging Clin North Am* 1999;9:509–525
3. Chopko BW, Kerber C, Wong W, Georgy B. **Transcatheter snare removal of acute middle cerebral artery thromboembolism: technical case report.** *Neurosurgery* 2000;46:1529–1531
4. Mayer TE, Hamann GF, Brueckmann HJ. **Treatment of basilar artery embolism with a mechanical extraction device: necessity of flow reversal.** *Stroke* 2002;33:2232–2235
5. Kerber CW, Barr JD, Berger RM, Chopko BW. **Snare retrieval of intracranial thrombus in patients with acute stroke.** *J Vasc Interv Radiol* 2002;13:1269–1274
6. Schumacher HC, Meyers PM, Yavagal DR, et al. **Endovascular mechanical thrombectomy of an occluded superior division branch of the left MCA for acute cardioembolic stroke.** *Cardiovasc Intervent Radiol* 2003;26:305–308
7. Wikholm G. **Transarterial embolectomy in acute stroke.** *AJNR Am J Neuroradiol* 2003;24:892–894
8. Watanabe M, Mori T, Imai K, et al. **Intra-arterial fibrinolysis combined with balloon angioplasty in patients with serious symptoms due to acute embolic total occlusion of the carotid artery [Abstract].** *Stroke* 2004;35:298
9. Lutsep HL, Clark WM, Nesbit GM, et al. **Intraarterial suction thrombectomy in acute stroke.** *AJNR Am J Neuroradiol* 2002;23:783–786
10. Qureshi AI, Siddiqui AM, Suri MFK, et al. **Aggressive mechanical clot disruption and low-dose intra-arterial third-generation thrombolytic agent for ischemic stroke: a prospective study.** *Neurosurgery* 2002;51:1319–1329
11. Yoneyama T, Nakano S, Kawano H, et al. **Combined direct percutaneous transluminal angioplasty and low-dose native tissue plasminogen activator therapy for acute embolic middle cerebral artery trunk occlusion.** *AJNR Am J Neuroradiol* 2002;23:277–281
12. The MERCI Investigators. **Results of the combined MERCI I-II (Mechanical Embolus Removal in Cerebral Ischemia) Trials [Abstract].** *Stroke* 2004;35:240