



Providing Choice & Value

Generic CT and MRI Contrast Agents



**FRESENIUS
KABI**

CONTACT REP

AJNR

**Stent-Assisted Angioplasty of Symptomatic
Intracranial Vertebrobasilar Artery Stenosis:
Feasibility and Follow-up Results**

Dong Joon Kim, Byung Hee Lee, Dong Ik Kim, Won Heum Shim, Pyoung Jeon and Tae Hong Lee

This information is current as
of July 30, 2025.

AJNR Am J Neuroradiol 2005, 26 (6) 1381-1388
<http://www.ajnr.org/content/26/6/1381>

Stent-Assisted Angioplasty of Symptomatic Intracranial Vertebrobasilar Artery Stenosis: Feasibility and Follow-up Results

Dong Joon Kim, Byung Hee Lee, Dong Ik Kim, Won Heum Shim, Pyoung Jeon, and
Tae Hong Lee

BACKGROUND AND PURPOSE: The natural history of symptomatic, untreated posterior circulation stenosis is dismal, with many patients experiencing significant morbidity or mortality. The purpose of this study was to evaluate the feasibility and results of stent-assisted angioplasty of symptomatic intracranial vertebrobasilar artery stenosis.

METHODS: We reviewed the imaging findings and medical records of 17 consecutive patients who were treated with stent-assisted angioplasty for medically refractory vertebrobasilar artery stenosis. The location of the lesion, degree of stenosis, procedure-related complications, and clinical and short- and long-term angiographic results were assessed.

RESULTS: The population included 17 cases (10 men, seven women; age range, 51–74 years; mean, 64 years). The locations of the lesions were intracranial vertebral artery ($n = 13$) and basilar artery ($n = 6$). The mean degree of stenosis decreased from $76.1 \pm 14.6\%$ before stent-assisted angioplasty to $1.3 \pm 2.8\%$ ($P < .05$) after the procedure. Acute in-stent thrombosis developed in one case (6%, Mori type B lesion), which was successfully treated with intraarterial abciximab infusion and angioplasty. Another patient (6%, Mori type C lesion) developed immediate postprocedural transient diplopia and ataxia, which gradually resolved. No other patient showed symptoms related to the vertebrobasilar artery lesion at follow-up. No significant restenosis was observed at short-term (five patients; follow-up range, 0.5–6 months; mean, 4.3 months) or long-term (six patients; follow-up range, 12–41 months; mean, 21 months) angiographic follow-up.

CONCLUSION: Stent-assisted angioplasty is a feasible treatment method for vertebrobasilar artery stenosis. The patency of the stent-assisted angioplasty seems to be preserved in the long-term, with good clinical outcome.

The natural history of untreated posterior circulation stenosis is dismal, with many patients experiencing significant morbidity or mortality (1–3). Retrospective data suggest that the annual stroke rates for patients with symptomatic intracranial vertebral or basilar artery stenosis are 7.8% and 10.7%, respectively, despite anticoagulation or antiplatelet therapy (3).

Recently, percutaneous transluminal angioplasty was proposed as a promising alternative treatment for patients with intracranial atherosclerotic stenosis symptoms despite medical therapy. However, percutaneous transluminal angioplasty has had the problems of dissection, elastic recoil, and thrombosis (4, 5). In a series of 42 cases of angioplasty for intracranial stenosis by Mori et al (4), the 1-year angiographic restenosis rate in type A (short, ≤ 5 mm in length, concentric or moderately eccentric lesions not totally occlusive), type B (tubular, 5–10 mm in length, extremely eccentric or totally occluded lesions, < 3 months old), and type C (diffuse, > 10 mm in length, extremely angulated [$> 90^\circ$] lesions with excessive tortuosity of the proximal segment, or totally occluded lesions, and ≥ 3 months old) lesions were 0%, 33%, and 100%, respectively, with cumulative risk of fatal or nonfatal ipsilateral ischemic stroke in 8%, 12%, 56%, respectively, at 1 and 2 years.

Stent-assisted angioplasty has been limited mainly

Received July 31, 2004; accepted after revision November 4.

From the Departments of Radiology (D.J.K., D.I.K.) and Cardiology (W.H.S.), Yonsei University College of Medicine, Seoul, Korea; Department of Radiology, Anyang Metro Hospital, Anyang, Korea (B.H.L.); the Department of Radiology, Ilsan Hospital, Goyang, Korea (P.J.); the Department of Radiology, Pusan National University Hospital, Pusan, Korea (T.H.L.).

Supported in part by Yonsei University Research Fund of 2004.

Address reprint requests to Byung Hee Lee, MD, Department of Radiology, Metro Hospital, 342-105 Anyang-dong, Manan-gu, Anyang-si, Kyunggi-do, 430-720.

by the apprehension concerning the technical feasibility, periprocedural complications, and short- and long-term outcomes (6). Major problems still exist; nonetheless, recent technical advances in instruments used for angioplasty and stent placement have allowed easier trackability through the small and tortuous intracranial vessels. Also, experience from the earlier works of intracranial angioplasty and stent placement has allowed a relatively safe procedure with fewer periprocedural complications (7–14).

We reviewed our experience with stent-assisted angioplasty for medically refractory intracranial vertebral and basilar artery stenoses, including the intra- and periprocedural complications and long-term angiographic and clinical outcomes.

Methods

Patients and Techniques

Between January 2000 and April 2004, 19 intracranial vertebral or basilar arteries in 17 patients were treated by means of stent-assisted angioplasty at our institutions.

The inclusion criteria for stent-assisted angioplasty were 1) recurrent symptoms due to the vertebrobasilar artery stenosis while being treated with optimal dosage of antiplatelet or anticoagulation medication, and 2) angiographically proved significant atherosclerotic stenoses ($>50\%$) that were responsible for the symptoms. All cases that met the inclusion criteria were included, unless the patient had refused treatment. There were no cases of technical failure.

The angiographic findings and medical records were retrospectively reviewed for sex, age, comorbid medical conditions, location of the lesion, degree of stenosis, Mori type, stenosis after stent placement, type of stent, periprocedural complications during admission, clinical follow-up, and short- (<12 months) and long-term (≥ 12 months) angiographic restenosis rates. Significant restenosis was defined as stenosis of greater than 50%. Stenosis rates before and after stent-assisted angioplasty and at follow-up were compared by using a paired Student *t* test. A probability of *P* less than .05 was considered statistically significant. SPSS 10.0 statistical software was used.

Operative Technique

In general, the patients were premedicated with daily doses of 100 mg of aspirin and 75 mg of clopidogrel (Plavix; Sanofi-Synthelabo, Korea) for at least 3 days before the procedure. In most patients, 2850 IU/0.3 mL of low-molecular-weight nadroparin calcium (Fraxiparine; Sanofi-Synthelabo, Korea) was injected subcutaneously two or three times per day during the same period. The patient was fully awake during the procedure, and the electrocardiogram, arterial oxygen saturation, and blood pressure were appropriately monitored. Percutaneous access was obtained via the right femoral artery and a 6F–7F sheath was inserted. Baseline activated clotting time (ACT) was obtained before the procedure. Then patients received systemic heparinization and a bolus injection of 3000–5000 IU of heparin just before starting the therapeutic procedure. A booster of 1000 IU of heparin was administered every hour to provide an ACT of longer than 250 seconds or twice the baseline ACT throughout the entire procedure. A 6F–7F guiding catheter (Envoy; Cordis Endovascular Corporation) was positioned in the distal vertebral artery. After obtaining a preliminary angiogram, the catheter was connected to a continuous saline flush. Preprocedural angiographic images were then obtained in orthogonal planes.

Measurement of the stenosis was performed by the operator. The degree of stenosis was calculated as follows:

$[1 - (\text{stenosis diameter})/\text{normal diameter}] \times 100$. The stenosis diameter was measured at the point of most severe stenosis, and the normal diameter was measured proximal to the stenosis at a point that was judged to be normal. The stenotic segment of the vertebral or basilar artery was then crossed with a 0.014-inch microwire that was navigated to the P2 segment of the posterior cerebral artery to ensure maximal support. Predilatation was not routinely performed owing to concerns of dissection and distal embolization. However, predilatation was considered in severely stenotic cases ($>95\%$ stenosis) or when the diameter of the stenosed segment was considered to be smaller than the profile of the stent catheter. The diameter of the stent was chosen according to the diameter of the normal proximal vessel. No attempt was made to undersize the stent. A wide variety of stents were used in this series because of the introduction of new stents with improved features during the study period of 4 years. In some cases, the limitations in the local availability of the stent contributed to the heterogeneous group of stents.

The coronary stent was advanced over the microwire and positioned across the stenosis with angiographic confirmation. In most cases, stent deployment was performed by using a multistage inflation technique (Fig 1). In this technique, the pressure of the balloon is increased in increments of 1 atmosphere (atm) after the initial deployment of the stent at a subnominal pressure. In other words, the pressure of the balloon is slowly inflated to 4–5 atm, then subsequent angiography is performed after deflating the balloon to identify any gap between the distal end of the stent and the arterial wall. If any gap is suspected at angiography, slow repeat inflation of the balloon is performed until the gap between the distal end of the stent and the parent artery has been eliminated. Then the distal tip of the balloon is retrieved into the distal end of the stent. By using the same technique, balloon inflations are repeated to the point where the gap between the mid to proximal end of the stent and the parent artery is eliminated. Balloon inflation pressures did not exceed the burst pressure of the stent and balloon. After satisfactory deployment of the stent, we waited another 30 minutes to identify possible complications, including acute in-stent thrombosis or vessel rupture. If there were no complications at final angiography, we completed the entire procedure. Immediately after stent placement, complete neurologic examination was performed by a neurologist. After the procedure, patients were medicated daily with 100 mg of aspirin and/or 75 mg of clopidogrel indefinitely. In most patients, 2850 IU of fraxiparine was also administered subcutaneously two or three times per day for at least 3 days. Written informed consent was obtained from all patients or their representatives.

Results

The cases consisted of 10 men and seven women (age range, 51–74 years; mean, 64 years) with 19 lesions. The locations of the lesions were intracranial vertebral artery ($n = 13$) and basilar artery ($n = 6$). The lesion Mori types were A in three, B in seven, and C in nine. The mean preprocedure diameter stenosis was $76.1 \pm 14.6\%$, which decreased significantly to $1.3 \pm 2.8\%$ after stent-assisted angioplasty ($P < .05$). Predilatation was performed in six of 19 lesions. Table 1 summarizes the patient characteristics.

Two partially overlapping stents were used in one lesion (case 15) owing to the long length of the diseased segment. In case eight (Fig 2), two partially overlapping stents had to be used because the stent was trapped at the proximal aspect of the nonpredilated stenotic lesion. Thus, a second stent was deployed, overlapping the distal aspect of the first stent and covering the remainder of the lesion.

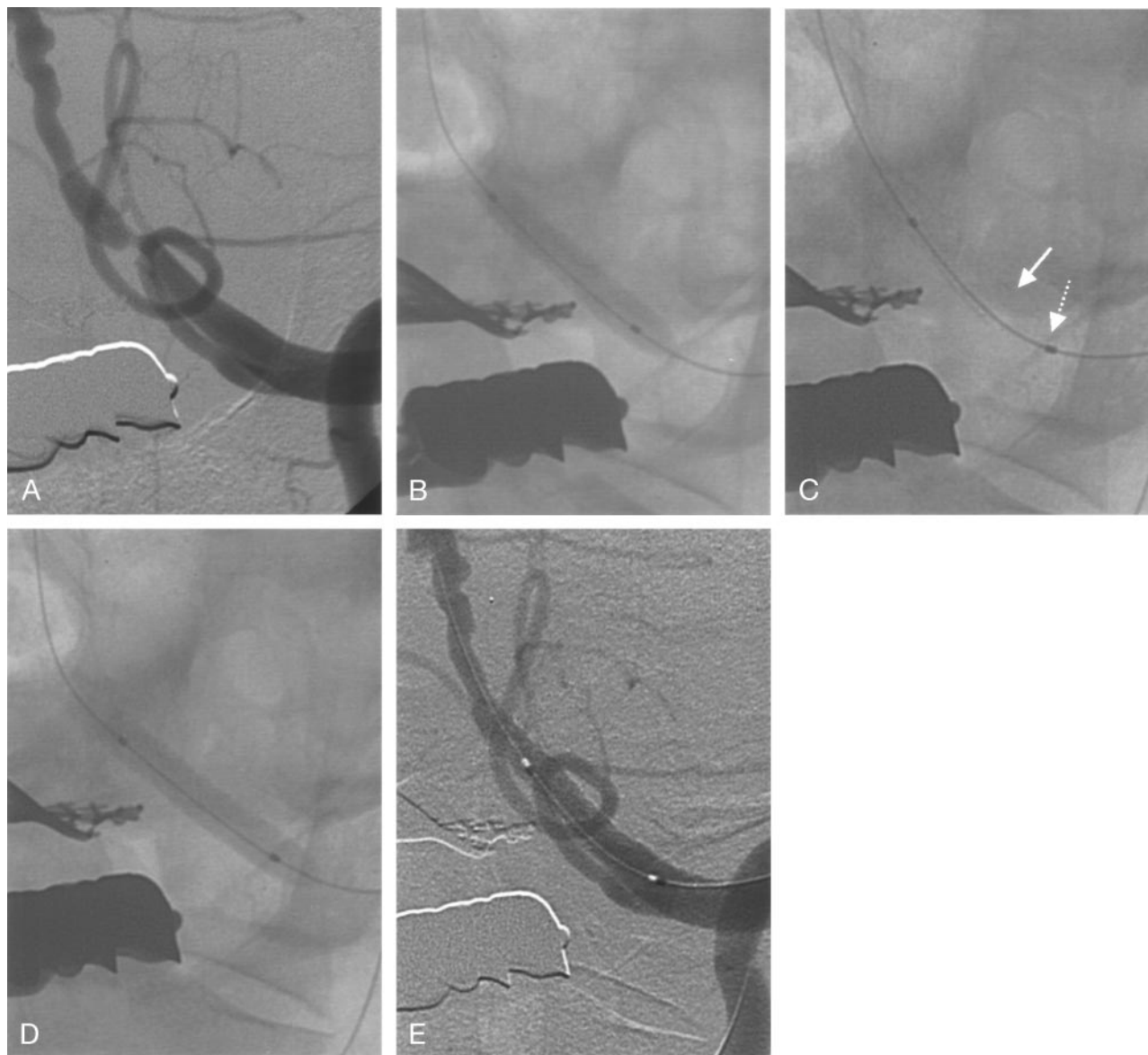


FIG 1. Representative case of multistaged balloon inflation technique in a patient with left distal vertebral artery stenosis.

A, Pretreatment angiogram shows a severely stenosed left distal vertebral artery at the site of posterior inferior cerebellar artery.

B, Angiogram shows the stent placed at the targeted lesion site; slow subnominal inflation (5 atm in this case) of the balloon was performed, with special consideration given to preventing "dog boning" of the proximal and distal ends of the balloon. Angiogram (not shown) was obtained to confirm the absence of a gap at the distal end of the stent.

C, Angiogram shows the balloon is carefully retrieved, with the proximal balloon marker (dotted arrow) placed outside the struts of the proximal end of the stent (solid arrow).

D, The balloon was slowly inflated to or above the nominal pressure, with special consideration given to avoiding any gap in the middle and proximal aspects of the stents. Repeat inflations were performed if any gap was visualized on the angiogram.

E, Final angiogram shows a well-positioned stent without gaps.

Periprocedural Complications

Periprocedural complications occurred in two (12%) of 17 cases. In case 1 (type B lesion), acute in-stent thrombosis developed during the procedure. Immediately after deployment of the stent, thrombus formation within the stent struts was noted, and the patient showed a rise in blood pressure from baseline of 169/82 to 193/106 mm Hg. The patient also developed transient vertigo, nystagmus, and lateral gaze limitations. Abciximab was injected intraarterially (6-mg bolus + 2 mg) and additional postprocedure angioplasty was performed, resulting in complete re-

canalization. The neurologic symptoms subsided after complete recanalization, and the patient did not develop any new symptoms related to the procedure.

In case 4 (type C lesion), the patient developed immediate postprocedural dizziness, diplopia, and ataxia after stent deployment in the basilar artery. Postprocedural MR imaging revealed multiple, newly developed acute ischemic foci in the cerebellar hemispheres. The patient made a gradual recovery of symptoms.

No other patients developed any serious changes in consciousness, blood pressure, pulse rate, electrocar-

TABLE 1: Summary of patient characteristics and treatment

Case No.	Sex	Age	Lesion Location	Comorbidities	Mori Lesion Type	Stenosis (%)		Predilatation (mm)	Stent (mm)	Complication
						Before	After			
1	F	58	BA	H	B	59	0	Maxxum 2.75/12	S660 2.75/18	Acute in-stent thrombosis*
2	F	63	BA	H, D, L	A	65	5		Jo flex 4/16	
			IVA, Lt		C	60	0		S670 3/24	
3	F	65	IVA, Lt	H	B	62	10		S670 3.5/18	Dizziness, ataxia†
4	M	60	BA	H	C	82	0	Maverick 2/12	Cypher 2.5/13	
5	M	51	IVA, Rt	H, D, S	C	95	0	Maestro 1.5/20	Jo flex 2.5/23	
6	M	70	IVA, Lt	H, D, S, C	A	90	0		S670 4/18	S660 2.5/9, 2.5/12‡
7	F	66	IVA, Lt	H, D	B	70	0		Jo flex 4/23	
8	M	55	IVA, Lt	H, D, L, S, C	A	95	0		S660 2.5/9, 2.5/12‡	
9	M	70	IVA, Rt	H, C	C	70	0		Jo bare 5/17	Ranger 2.5/20
10	M	74	IVA, Rt	H, D, S, M	B	69	0		AVE 3.5/12	
11	F	60	BA	H	C	95	0		S670 3/18	
12	M	69	BA	H	B	90	0		Jo flex 3.5/16	Larus 2.5/10
13	M	62	IVA, Lt	H, L	B	74	0		Jo Stent 3.0/12	
14	F	65	BA	H	C	90	5		S670 3.5/24	
			IVA, Lt		B	60	0		S670 4/24	S660 2.5/15, S670 3/19§
15	F	76	IVA, Lt	H, D, L, S	C	80	0		S660 2.5/15, S670 3/19§	
16	M	68	IVA, Lt	H, S, C	C	50	5		S7 4/30	
17	M	60	IVA, Lt	H, L, S	C	90	0	Maestro 1.5/20	Jo flex 3/19	

Note.—IVA indicates intracranial vertebral artery; BA, basilar artery; H, hypertension; D, diabetes mellitus; L, hyperlipidemia; S, smoking; C, coronary artery disease.

* Recanalized after intraarterial abciximab injection.

† Improved during hospitalization.

‡ First stent was trapped by the tight stenosis and had to be deployed proximal to the lesion site; thus, a second stent was used for distal angioplasty.

§ Two stents used for long length of the lesion.

diographic waves, or arterial oxygen saturation rates during the procedure.

Clinical and Angiographic Follow-up

Clinical follow-up was available in all patients and ranged from 6 to 45 months (mean follow-up, 17 months). During the follow-up period, three patients (two type A lesions, one type B lesion) developed transient ischemic attack symptoms (cases 2 and 7) or minor stroke (case 8) at 3, 15, and 19 months after the procedure, respectively. MR examinations revealed newly developed ischemic lesions outside the vertebrobasilar territory, thus the stroke symptoms were regarded to be unassociated with the vertebrobasilar artery lesion. One patient (6%, case 16 with a type C lesion) developed thalamic intracranial hemorrhage 2 months after the procedure. This patient was given warfarin after coronary stent placement for myocardial infarction. Other patients showed improvement of initial symptoms. Table 2 summarizes the follow-up results.

Conventional angiographic follow-up was available in 11 of 17 patients. Short-term angiographic follow-up (range, 0.5–6 months; mean, 4.3 months) was performed in five patients. Long-term angiographic follow-up (range, 12–41 months; mean, 21 months) was performed in six patients. No cases showed significant restenosis of the stent-treated artery at short-term follow-up. Three cases (cases 1, 2, and 3)

showed total patency without restenosis, and two cases (cases 4 and 5) showed mild restenosis (10% and 14%) from intimal hyperplasia. Both of the cases showing mild restenosis were type C lesions. None of the cases showed significant restenosis at long-term follow-up as well. Total patency was observed in four cases (cases 6, 7, 9, and 10) and mild restenosis (5% and 10%) in two cases (cases 8 and 11). The mild restenoses were observed in types A and C lesions, respectively.

Discussion

In the midst of the rapid growing body of knowledge and interest concerning the feasibility of stent-assisted angioplasty for intracranial stenosis, the results of our case series offer further evidence in favor of this new treatment option in patients with symptomatic, medically refractory vertebrobasilar artery stenosis. First, we have shown the feasibility of stent-assisted angioplasty for vertebrobasilar artery stenosis, with low periprocedural complication rates. Second, we followed up these cases and have shown the durability of the treatment outcome on short- and long-term clinical as well as angiographic outcomes.

Previous reports on the results of stent-assisted angioplasty for vertebrobasilar stenosis are relatively limited. Since the initial pioneering case reports on the technical feasibility of intracranial stent placement for vertebrobasilar stenosis, a few case series

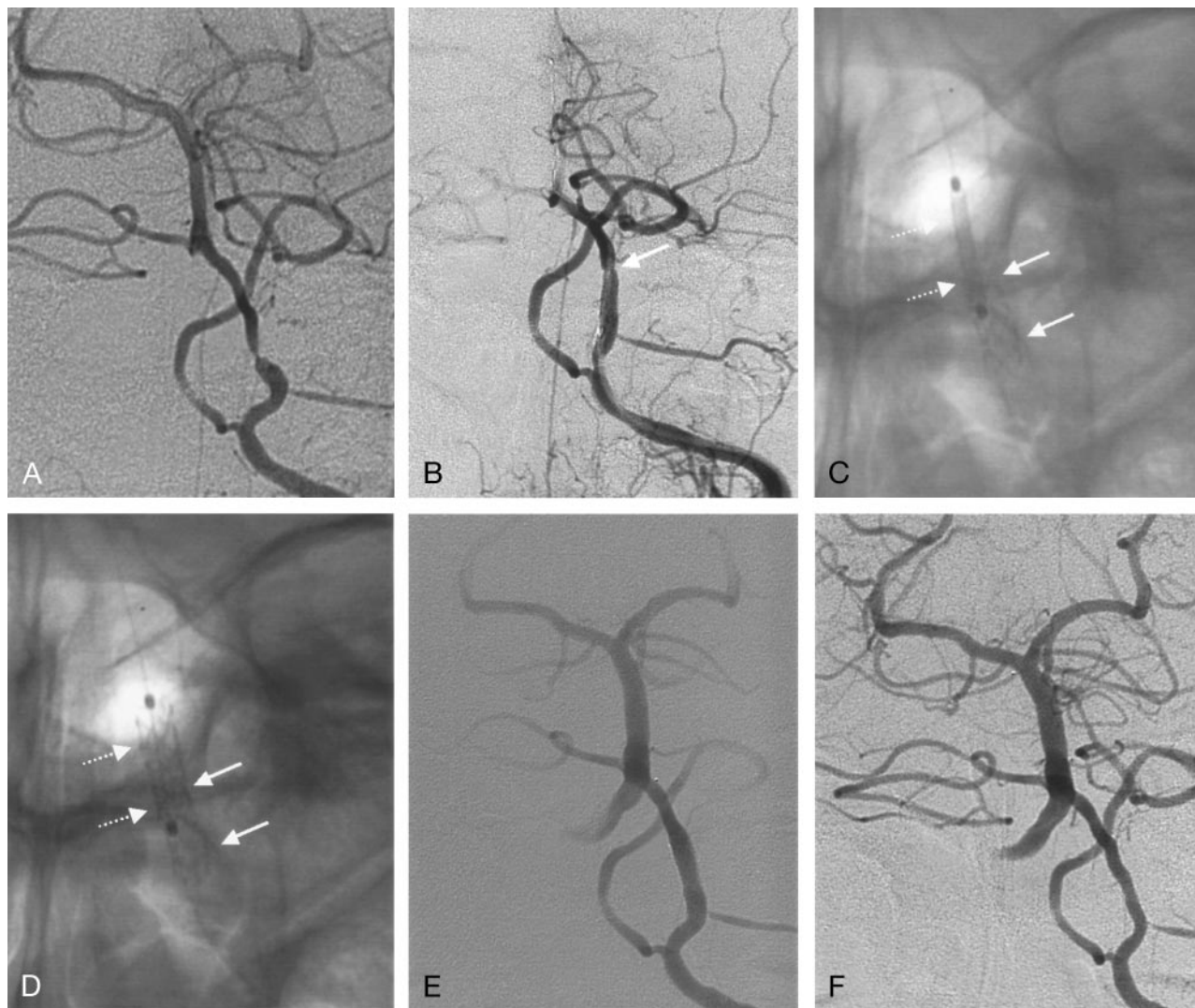


FIG 2. Case 8. A 55-year-old man with transient ischemic attack at presentation.

A, Initial left vertebral artery angiogram shows 95% stenosis of the intracranial vertebral artery.

B, Angiogram shows that the distal vertebral artery is straightened because of the stent-mounted catheter, and the lesion site is displaced more cranially (arrow). Primary stent deployment was attempted with a S660 2.5/9 stent; however, the distal end of the stent could not pass through the lesion site. Stent catheter was not retrieved because of concerns for acute thrombus formation. Notice the compromised flow in the basilar artery due to the trapped stent catheter.

C, Magnified angiographic view. After deployment of the initial stent (solid arrows) and additional careful angioplasty, a second stent-mounted catheter (dotted arrows) was navigated through the initial stent.

D, Magnified angiographic view. The second stent (dotted arrows) was deployed partially overlapping the initial stent (solid arrows) and covering the distal aspect of the lesion.

E, Final angiogram shows no residual stenosis.

F, Seventeen-month follow-up angiogram shows the patent stent site without significant restenosis.

with follow-up results have been reported (10, 12, 14–22).

Gomez et al (16) reported the results of 12 cases of stent-assisted angioplasty for basilar stenosis. The clinical follow-up period ranged from 0.5 to 16 months (mean, 5.9 months). One patient had nonspecific symptoms and another had a transient ischemic attack. All other patients remained asymptomatic. In the series by Mori et al (15), access failure was reported in two of eight cases of intracranial vertebral artery or basilar artery stent placement. Repeat arteriography of vertebrobasilar stent-treated lesions ($n = 6$) showed 6–25% restenosis (mean, 16%) at 3

months. No cerebrovascular event occurred during and after the procedure and during the 8- and 13-month clinical follow-up periods. Rasmussen et al (17) reported their experience with intracranial vertebrobasilar stent placement in eight patients. One patient died on the day of the procedure because of a massive subarachnoid hemorrhage. One patient experienced a transient encephalopathy. All remaining patients were asymptomatic up to 8 months postoperatively.

The early results of direct or conventional stent-assisted angioplasty for intracranial vertebroplasty stenosis by Levy et al (18) seemed somewhat less than

TABLE 2: Clinical and angiographic follow-up results

Case No.	Clinical Follow-up		Angiographic Follow-up	
	Duration (mo)	Clinical Outcome	Duration (mo)	Restenosis (%)
1	10	Improved, residual dizziness	0.5	0
2	12	Improved, unrelated TIA at 3 mo	3	0*
3	11	Improved	6	0
4	10	Improved, residual dizziness	6	14
5	13	Improved	6	10
6	12	Improved	12	0
7	18	Improved, unrelated TIA at 15 mo	15	0
8	23	Improved, unrelated minor stroke at 19 mo	17	5
9	20	Improved	17	0
10	45	Improved, residual dizziness	25	0
11	41	Improved	41	10
12	6	Improved		
13	7	Improved		
14	41	Improved		
15	7	Improved		
16	10	Improved, thalamic ICH at 2 mo		
17	6	Improved		

Note.—TIA indicates transient ischemic attack; ICH, intracranial hemorrhage.

* Includes both vertebral artery and basilar artery lesions.

satisfactory. Four (36%) of 11 patients died of procedure-related complications: two from vessel rupture, one from brain death, and the last case from pontine infarction. The remaining seven patients showed symptom resolution, and angiographic follow-up (mean, 4 months; range, 3 days to 12 months) demonstrated good patency in five cases. One case exhibited minimal intimal hyperplasia and the other case exhibited 40% narrowing of the vessel lumen. In later reports by Levy et al (19, 20), better outcome was achieved by performing a staged stent-assisted angioplasty for patients with vertebrobasilar stenoses. In three patients, long-term angiographic follow-up (23.2, 27, 30 months; mean, 26.7 months) was available. The postprocedure percentages of stenoses at these periods were 24%, 16%, and 22%, respectively (20).

In the recently published results of the Stenting of Symptomatic Atherosclerotic Lesions in the Vertebral or Intracranial Arteries study (22), the technical success rate for stent placement was 95% (58 of 61 cases) for vertebral or intracranial stenoses. Strokes after stent placement occurred in 14% (three of 22 cases) of intracranial vertebrobasilar stenosis during a 1-year follow-up period. Although significant restenosis (> 50% stenosis) occurred in 32.4% (12 of 37 cases) of intracranial arteries and 42.9% (six of 14 cases) of extracranial vertebral arteries at 6-month follow-up angiography, only 39% (seven cases) were symptomatic.

In our series, two cases (12%) of periprocedural complications occurred. Case 1 (type B lesion) developed acute in-stent thrombosis immediately after predilatation and stent deployment. In case 4 (type C lesion), the patient developed dizziness and ataxia immediately after the procedure. The possible causes for these complications are, first, the disruption of the atheromatous plaque from balloon inflation inducing

thrombosis formation; second, dissection of the artery from predilatation or stent deployment; and, third, presence of gap between the stent and arterial wall causing acute or subacute thrombus formation. Perforator occlusion by the stent strut or by “snowplowing effect” from the large-profile devices has been proposed as a possible mechanism for poststent ischemic complications, but this seemed unlikely considering the findings of multiple cerebellar embolic infarct on follow-up MR images in the latter case (20, 23).

The acute in-stent thrombosis in the first case was successfully managed with intraarterial injections (6-mg bolus + 2 mg) of abciximab and with angioplasty. Abciximab is the Fab fragment of a monoclonal antibody directed against the platelet glycoprotein IIb-IIIa receptor acting as a potent platelet inhibitor (24). The most commonly used regimen consists of an intravenous 0.25-mg/kg bolus injection and then a continuous infusion of 0.125 mg/kg/min (maximum 10 mg/min) for 12 hours. The efficacy of abciximab has been extensively documented in experimental as well as clinical studies (25–27). Localized intraarterial infusion of abciximab could theoretically allow a fast recanalization with a small dose as in our case, and such results have recently been reported for endovascular procedures in the cerebral circulation (28, 29).

In terms of follow-up, we are not aware of any large series of intracranial stent-assisted angioplasty cases that include the results of long-term angiographic follow-up. Our results show that the effects of stent-assisted angioplasty for intracranial vertebrobasilar stenosis are preserved in short- and long-term follow-up. All cases showed clinical improvement, and none of the 19 lesions showed significant restenosis on the short- and long-term follow-up angiograms. These results seem better than those of previously published series. Experiences from coronary angioplasty and

stent placement have allowed a considerable body of knowledge concerning the processes of restenosis (30, 31). Mechanisms involved in restenosis are elastic recoil, negative remodeling, early thrombus formation, and neointimal hyperplasia with vascular smooth muscle cells. With stent-assisted angioplasty, elastic recoil and negative remodeling are virtually eliminated as causes of restenosis. Restenosis in stents is largely due to neointimal proliferation, which has a strong tendency to occur in patients with diabetes mellitus and in cases of small reference vessel diameter and long stent length (30, 31).

Experience from coronary stent placement has shown that the amount of initial luminal gain within the stent-treated segment was a major determinant for long-term luminal patency and also seemed to be inversely correlated to the frequency of stent thrombosis (32, 33). Intravascular sonography in patients who underwent coronary stent placement procedures by using the traditional inflation techniques have demonstrated a high frequency of incompletely expanded stents despite an acceptable angiographic appearance (34). Thus, high-pressure inflation is often performed in coronary stent placement to optimize the stent apposition to the arterial wall (35). In the case of intracranial vessels, the potential risk of rupture from high-pressure inflations may be greater due to a lack of surrounding supportive tissue in the subarachnoid space. However, according to the coronary experience, the stent-treated artery is believed to be relatively immune from subsequent angioplasties by the scaffolding properties of the previously deployed stent. In the series by Alfonso et al (36), the risk of arterial perforation from high-pressure inflations (≥ 14 atm) within the stent-treated segment of the coronary arteries was very low, with a rate of 1.7% (three of 170 cases).

In our series, we used a multistaged high-inflation technique for stent deployment to optimize stent expansion and reduce the frequency of in-stent thrombosis and the restenosis rate. Regarding the discrepancy between the proximal and distal diameters of arteries and the irregular nature of the atherosclerotic vessel, a single nominal pressure inflation may not be sufficient in achieving an optimal stent apposition. Thus, multistaged balloon inflations were performed with the intention of optimally conforming the stent configuration to the vascular anatomy. After initial deployment of the stent, multistaged location-adjusted slow balloon inflations, with multiple interim angiograms, were performed to eliminate gaps, thus resulting in a tailored apposition of the stent to the arterial anatomy. The initial target for gap elimination was the distal end of the stent, and after achieving satisfactory apposition at the distal end, the balloon was slightly retrieved into the stent. The reason for such multistaged, location-adjusted inflations was that the distal vessel diameter is usually smaller than the proximal vessel diameter, and multiple inflations disregarding the discrepancy could be the cause of dissection or perforation, especially at the distal end. Inflations were always performed in a very slow man-

ner to prevent dissection from the "dog-bone" phenomenon at the distal and proximal ends of the balloon. Balloon inflation pressures not exceeding the burst pressure of the balloon and stent and preparation of extra balloons and stents for emergent arterial hemostasis in case of rupture were also necessary for a safer procedure. These technical innovations may have been key to the favorable periprocedural and long-term follow up results.

Predilatation was not routinely performed in our series (direct stent placement in 13 of 19 lesions), because it carries a higher risk of dissection and distal emboli from plaque disruption (21). This caused a problem in one case (Fig 2, case 8), in which the stent was trapped by the tight stenosis (95%) and could not cross the stenosed segment. A second stent had to be deployed, overlapping the initial stent; the patient did not develop any neurologic deficits associated with the procedure. These results seem to contradict the finding of Levy et al in which direct stent placement was associated with dense quadriplegia in two of four cases, as mentioned above. They explained that the high rates of complications were due to embolic shower or the "snowplowing effect" of the high-profile stents. Their recommendations were to perform a staged submaximal angioplasty followed by a second session stent placement to augment the lumen of the parent vessel while minimizing the risk of plaque rupture, and also to afford protection against distal embolization of plaque debris, especially for unstable (recently symptomatic), ulcerated, or high-grade stenosis (20). In view of our favorable results, however, we believe that direct or conventional stent placement with a multistaged inflation technique is a feasible treatment option. It may be more advantageous compared with the multistaged sessions in terms of time and cost.

The outcomes of stent-assisted angioplasty for the Mori type C lesions ($n = 9$) in our series were also satisfactory, with only one case showing periprocedural complications (case 4). Nevertheless, three of the four cases of mild restenosis were type C lesions. For this type of lesion, an optimal treatment method in terms of equipment and technique should be sought and further emphasis on follow-up should be considered.

Conclusion

Stent-assisted angioplasty for symptomatic, medically refractory intracranial vertebrobasilar stenosis is a technically feasible treatment option with a relatively low complication rate. Also, the treatment results seem to be sustained in the long-term clinical and angiographic follow-up studies. Randomized controlled trials are necessary to further validate this treatment option.

References

1. Moufarrij NA, Little JR, Furlan AJ, Leatherman JR, Williams GW. Basilar and distal vertebral artery stenosis: long-term follow-up. *Stroke* 1986;17:938-942

2. Ausman JJ, Shrontz CE, Pearce JE, Diaz FG, Crecelius JL. **Vertebrobasilar insufficiency: a review.** *Arch Neurol* 1985;42:803–808
3. The Warfarin-Aspirin Symptomatic Intracranial Disease (WASID) Study Group. **Prognosis of patients with symptomatic vertebral or basilar artery stenosis.** *Stroke* 1998;29:1389–1392
4. Mori T, Fukuoka M, Kazita K, Mori K. **Follow-up study after intracranial percutaneous transluminal cerebral balloon angioplasty.** *AJNR Am J Neuroradiol* 1998;19:1525–1533
5. Connors JJ 3rd, Wojak JC. **Percutaneous transluminal angioplasty for intracranial atherosclerotic lesions: evolution of technique and short-term results.** *J Neurosurg* 1999;91:415–423
6. Marks MP, Do HM. *Endovascular and Percutaneous Therapy of the Brain and Spine.* Philadelphia: Lippincott Williams & Wilkins, 2002
7. Sundt TM Jr, Smith HC, Campbell JK, Vlietstra RE, Cucchiara RF, Stanson AW. **Transluminal angioplasty for basilar artery stenosis.** *Mayo Clin Proc* 1980;55:673–680
8. Higashida RT, Hieshima GB, Tsai FY, Halbach VV, Norman D, Newton TH. **Transluminal angioplasty of the vertebral and basilar artery.** *AJNR Am J Neuroradiol* 1987;8:745–749
9. Purdy PD, Devous MD Sr, Unwin DH, Giller CA, Batjer HH. **Angioplasty of an atherosclerotic middle cerebral artery associated with improvement in regional cerebral blood flow.** *AJNR Am J Neuroradiol* 1990;11:878–880
10. Mori T, Kazita K, Mori K. **Cerebral angioplasty and stenting for intracranial vertebral atherosclerotic stenosis.** *AJNR Am J Neuroradiol* 1999;20:787–789
11. Morris PP, Martin EM, Regan J, Braden G. **Intracranial deployment of coronary stents for symptomatic atherosclerotic disease.** *AJNR Am J Neuroradiol* 1999;20:1688–1694
12. Horowitz MB, Pride GL, Graybeal DF, Purdy PD. **Percutaneous transluminal angioplasty and stenting of midbasilar stenoses: three technical case reports and literature review.** *Neurosurgery* 1999;45:925–930; discussion 930–921
13. Gomez CR, Misra VK, Campbell MS, Soto RD. **Elective stenting of symptomatic middle cerebral artery stenosis.** *AJNR Am J Neuroradiol* 2000;21:971–973
14. Lanzino G, Fessler RD, Miletich RS, Guterman LR, Hopkins LN. **Angioplasty and stenting of basilar artery stenosis: technical case report.** *Neurosurgery* 1999;45:404–407; discussion 407–408
15. Mori T, Kazita K, Chokyu K, Mima T, Mori K. **Short-term arteriographic and clinical outcome after cerebral angioplasty and stenting for intracranial vertebrobasilar and carotid atherosclerotic occlusive disease.** *AJNR Am J Neuroradiol* 2000;21:249–254
16. Gomez CR, Misra VK, Liu MW, et al. **Elective stenting of symptomatic basilar artery stenosis.** *Stroke* 2000;31:95–99
17. Rasmussen PA, Perl J 2nd, Barr JD, et al. **Stent-assisted angioplasty of intracranial vertebrobasilar atherosclerosis: an initial experience.** *J Neurosurg* 2000;92:771–778
18. Levy EI, Horowitz MB, Koebe CJ, et al. **Transluminal stent-assisted angioplasty of the intracranial vertebrobasilar system for medically refractory, posterior circulation ischemia: early results.** *Neurosurgery* 2001;48:1215–1221; discussion 1221–1213
19. Levy EI, Hanel RA, Bendok BR, et al. **Staged stent-assisted angioplasty for symptomatic intracranial vertebrobasilar artery stenosis.** *J Neurosurg* 2002;97:1294–1301
20. Levy EI, Hanel RA, Boulos AS, et al. **Comparison of periprocedure complications resulting from direct stent placement compared with those due to conventional and staged stent placement in the basilar artery.** *J Neurosurg* 2003;99:653–660
21. Piotin M, Blanc R, Kothimbakam R, Martin D, Ross IB, Moret J. **Primary basilar artery stenting: immediate and long-term results in one patient.** *AJR Am J Roentgenol* 2000;175:1367–1369
22. SSYLVA Study Investigators. **Stenting of symptomatic atherosclerotic lesions in the vertebral or intracranial arteries (SSYLVA): study results.** *Stroke* 2004;35:1388–1392
23. Lincoff AM. **Stent scrutiny.** *JAMA* 2000;284:1839–1841
24. Collier BS. **Platelet GPIIb/IIIa antagonists: the first anti-integrin receptor therapeutics.** *J Clin Invest* 1997;99:1467–1471
25. The EPIC Investigation. **Use of a monoclonal antibody directed against the platelet glycoprotein IIb/IIIa receptor in high-risk coronary angioplasty.** *N Engl J Med* 1994;330:956–961
26. Reverter JC, Beguin S, Kessels H, Kumar R, Hemker HC, Collier BS. **Inhibition of platelet-mediated, tissue factor-induced thrombin generation by the mouse/human chimeric 7E3 antibody: potential implications for the effect of c7E3 Fab treatment on acute thrombosis and “clinical restenosis”.** *J Clin Invest* 1996;98:863–874
27. Antman EM, Giugliano RP, Gibson CM, et al. **Abciximab facilitates the rate and extent of thrombolysis: results of the thrombolysis in myocardial infarction (TIMI) 14 trial. The TIMI 14 Investigators.** *Circulation* 1999;99:2720–2732
28. Kwon OK, Lee KJ, Han MH, Oh CW, Han DH, Koh YC. **Intraarterially administered abciximab as an adjuvant thrombolytic therapy: report of three cases.** *AJNR Am J Neuroradiol* 2002;23:447–451
29. Mounayer C, Piotin M, Baldi S, Spelle L, Moret J. **Intraarterial administration of abciximab for thromboembolic events occurring during aneurysm coil placement.** *AJNR Am J Neuroradiol* 2003;24:2039–2043
30. Bhargava B, Karthikeyan G, Abizaid AS, Mehran R. **New approaches to preventing restenosis.** *BMJ* 2003;327:274–279
31. Holmes DR Jr. **In-stent restenosis.** *Rev Cardiovasc Med* 2001;2:115–119
32. Haude M, Erbel R, Issa H, et al. **Subacute thrombotic complications after intracoronary implantation of Palmaz-Schatz stents.** *Am Heart J* 1993;126:15–22
33. Mudra H, Klauss V, Blasini R, et al. **Ultrasound guidance of Palmaz-Schatz intracoronary stenting with a combined intravascular ultrasound balloon catheter.** *Circulation* 1994;90:1252–1261
34. Moussa I, Di Mario C, Di Francesco L, Reimers B, Blengino S, Colombo A. **Subacute stent thrombosis and the anticoagulation controversy: changes in drug therapy, operator technique, and the impact of intravascular ultrasound.** *Am J Cardiol* 1996;78:13–17
35. Holmes DR Jr, Hirshfeld J Jr, Faxon D, Vlietstra RE, Jacobs A, King SB 3rd. **ACC expert consensus document on coronary artery stents: document of the American College of Cardiology.** *J Am Coll Cardiol* 1998;32:1471–1482
36. Alfonso F, Goicolea J, Hernandez R, et al. **Arterial perforation during optimization of coronary stents using high-pressure balloon inflations.** *Am J Cardiol* 1996;78:1169–1172