



Get Clarity On Generics

Cost-Effective CT & MRI Contrast Agents



FRESENIUS
KABI

WATCH VIDEO

AJNR

Neuroimaging Clinics of North America: Epilepsy. Vol. 14, no. 3, August 2004.

AJNR Am J Neuroradiol 2005, 26 (3) 681-682
<http://www.ajnr.org/content/26/3/681>

This information is current as
of August 14, 2025.

Neuroimaging Clinics of North America: Epilepsy. Vol. 14, no. 3, August 2004.

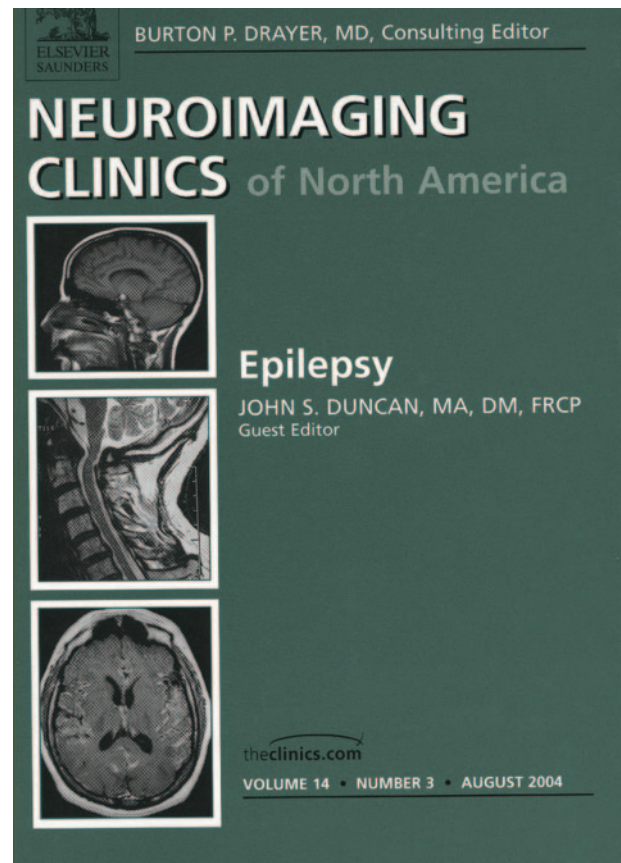
John S. Duncan, ed. Philadelphia: Elsevier Saunders; 2004. 577 pages.

Recent advances in neuroimaging are transforming clinical and experimental epileptology. This transformation has occurred over a remarkably short period of time and has affected the care and treatment of epilepsy patients in many startling ways. The greatest beneficiaries have been patients referred for surgical treatment, as the positive identification of a discrete region of signal intensity abnormality indicative of an epileptogenic lesion facilitates case selection and improves long-term postoperative prognosis. Cases previously rejected for surgery because of "nonlesional" epilepsy may become candidates through the neuroimaging of subtle lesions. Functional imaging adds complementary data by demonstrating regions of eloquent cortex that need to be spared. These advances have also diminished the need to implant intracranial EEG electrodes and perform Wada testing to lateralize language and memory function.

From an experimental standpoint, neuroimaging data has contributed significant new information regarding the deleterious effects of single seizures and chronic epilepsy, the neuroembryology of cortical malformations, biochemical changes that accompany epileptic seizures and anomalies of functional brain representation. These data are often pivotal in shaping our views concerning the basic mechanisms of the epilepsies and ultimately assisting in the search for new ways to prevent and cure epilepsy.

With the high level of worldwide interest and activity surrounding the application of neuroimaging techniques to the field of epilepsy, the recent volume of the Neuroimaging Clinics of North America devoted to epilepsy comes at a particularly auspicious moment. Edited by John S. Duncan ("Neuroimaging Clinics of the North Atlantic"?), this book was produced "to take stock of the current status of neuroimaging of epilepsy and to consider future areas of clinical application." To achieve these goals, Professor Duncan has assembled a distinguished group of authors who are recognized authorities in their respective fields, including neuroradiology, nuclear medicine, physics, neurology, neurosurgery, and epileptology. The result is a scholarly work that provides in-depth coverage of the field that is not otherwise available in such a concise format.

Following brief introductory remarks about the overall role of neuroimaging, the first chapter focuses on the neuroimaging features of the substrates of focal epilepsy. Cryptogenic and symptomatic etiologies are covered systematically; the authors provide helpful illustrations of technical approaches that maximize yield. A useful approach for interpreting MR images in epilepsy is provided, as well as coverage of the ways to avoid pitfalls in diagnosis. The authors provide a checklist of recommended imaging se-



quences. Although institutions may differ with regard to their protocols, the recommendations serve as a useful framework. Quantitative MR imaging of the neocortex is covered in a separate chapter that provides an overview of current techniques to detect subtle lesions that might otherwise be overlooked.

Two separate chapters are devoted to a review of the neuroimaging features of hippocampal sclerosis and cortical malformations. This emphasis is in accord with the important role of these lesions in the genesis of epileptic seizures. The orientation of the chapters differs, however, in that the hippocampal sclerosis chapter emphasizes techniques to diagnose and quantify hippocampal sclerosis, whereas the malformation chapter is organized along the lines of neuroembryology.

Chapters devoted to novel MR contrast techniques and functional MR imaging review technical advances with considerable future potential. Information from diffusion-weighted imaging, tractography, and T2 mapping are increasingly being included in epilepsy surgical protocols and is reviewed in detail; functional MR imaging of sensorimotor, language, and memory is covered from the perspective of theoretical frame-

work, clinical applications, and results. There is no coverage of functional MR imaging of visual cortex. While patients with occipital epilepsy are a minority of surgical candidates, inclusion of this subject would have been clinically useful. A separate chapter is devoted to the relationship of electroencephalography and functional MR imaging for the detection of paroxysmal epileptiform transients. Although this application currently resides within the research domain, its inclusion is a strong point, because this application is likely to grow in clinical relevance.

I particularly appreciated the chapter devoted to serial brain imaging studies. The occurrence of secondary brain damage from epilepsy has been difficult to document in human epilepsy. Serial MR imaging studies are now providing definitive proof of the widespread occurrence and the magnitude of structural damage caused by status epilepticus and recurrent seizures. One has the feeling that the surface of this field has only been scratched. Neuroimaging data already constitutes a strong rationale for advocating more aggressive treatment of the epilepsies and a

means to assess the efficacy of neuroprotective interventions.

The organizational sequence of the book is logical, the chapters are subdivided appropriately, and the references are comprehensive and up to date. The chapters are well written and share an overall evenness of style and content that makes for an easy read. The inclusion of good quality color figures, in addition to the monochromatic images, enhances the text. The figure legends are descriptive. The inclusion of more tables within each chapter might have assisted the reader in organizing the information. This is a minor criticism that in no way detracts from the many strengths of this slim volume. It is recommended reading for all neuroradiologists, but will be especially valuable to anyone with an interest in epilepsy and epilepsy surgery. Epileptologists, as well as neurologists and neurosurgeons working with epilepsy patients will also find the information in this book highly relevant. It is difficult to imagine evaluating an epilepsy patient for surgery without a working knowledge of the material presented in this fine volume.