



Get Clarity On Generics

Cost-Effective CT & MRI Contrast Agents



FRESENIUS
KABI

WATCH VIDEO

AJNR

Dynamic Upper Airway Soft-Tissue and Caliber Changes in Healthy Subjects and Snoring Patients

Hüseyin Akan, Tolga Aksöz, Ümit Belet and Teoman Sesen

AJNR Am J Neuroradiol 2004, 25 (10) 1846-1850

<http://www.ajnr.org/content/25/10/1846>

This information is current as
of August 18, 2025.

Dynamic Upper Airway Soft-Tissue and Caliber Changes in Healthy Subjects and Snoring Patients

Hüseyin Akan, Tolga Aksöz, Ümit Belet, and Teoman Şeşen

BACKGROUND AND PURPOSE: The oropharyngeal airways are smaller in those who snore than in those who do not. We sought to determine which soft-tissue component surrounding the airways contributes to upper airway narrowing in those who snore.

METHODS: Ten control subjects and 19 snoring patients underwent CT, with 2-mm-thick axial sections obtained every 0.6 seconds during the respiration cycle at the same oropharyngeal level. We selected two sections with the widest and narrowest parts of the oropharyngeal airway to measure the anteroposterior and lateral dimensions of the airway and the thickness of the bilateral parapharyngeal fat pads, pterygoid muscles, and parapharyngeal muscles. Mean values were calculated for each phase. For each subject, differences between the values in narrowest phase from those in the widest phase were calculated by subtracting the

RESULTS: Changes in airway dimension ($P < .01$) were significantly different from changes in parapharyngeal wall thickness and pterygoid muscle thickness ($P < .01$). Changes in airway dimension were significantly related ($P < .01$) to changes in parapharyngeal wall thickness and pterygoid muscle thickness.

CONCLUSION: Airway dimension in people who snore. Changes in airway dimension were significantly different from changes in parapharyngeal wall thickness and pterygoid muscle thickness. Changes in airway dimension were significantly related to changes in parapharyngeal wall thickness and pterygoid muscle thickness. Changes in airway dimension were significantly related to changes in parapharyngeal wall thickness and pterygoid muscle thickness.

Snoring is a noisy condition produced by vibrations and partial obstruction of the oropharynx. Some structural abnormalities can be associated with snoring (1). Snoring is not only an uncomfortable condition but also one of clinical importance. Snoring is closely linked with sleep apnea, and both conditions are risk factors for cardiovascular and cerebrovascular diseases (1, 2). Obesity, male sex, older age, smoking, alcohol, and some drugs (tranquillizers or muscle relaxants) are important risk factors for snoring (3, 4).

Some have reported that people who snore have oropharyngeal airways smaller than those of individuals who do not (5–8). Because dynamic airway changes during respiratory cycle can be demonstrated on cine CT, we have examined the upper airway with

cine CT, as the other investigators did (8–12). In this study, we sought to detect which soft-tissue component surrounding the airways plays the most important role in this narrowing.

Methods

Nineteen snoring patients who were followed up by the otolaryngology department for snoring and 10 control subjects were evaluated. The volunteer control subjects had regular sleeping partners who were able to confirm that they did not habitually snore. A detailed medical and snoring history was taken. Snorers had a nightly snoring frequency and no episodes of cessation of breathing. Three patients had one or more symptoms of fatigue, tiredness, or sleepiness. The remaining 16 were symptom free.

Patients and control subjects who were found to have nasal, oral, or pharyngeal variations or diseases on CT scans were excluded. Their weights and heights were measured, and body mass indices (BMIs) were calculated by dividing their mass in kilograms by the square of their height in meters. The control group was not weight matched, as simply weight-matching subjects (i.e., those with the same BMI) may not be an appropriate control because fat distribution may still differ between groups (12).

Received November 14, 2003; accepted after revision March 25, 2004.

From the Departments of Radiology (H.A., T.A., U.B.) and Otolaryngology (T.S.), Ondokuz Mayıs University Faculty of Medicine, Samsun, Turkey.

Address reprint requests to Professor Dr Hüseyin Akan, Ondokuz Mayıs University Faculty of Medicine, Radiology Department, 55139 Samsun, Turkey.

© American Society of Neuroradiology

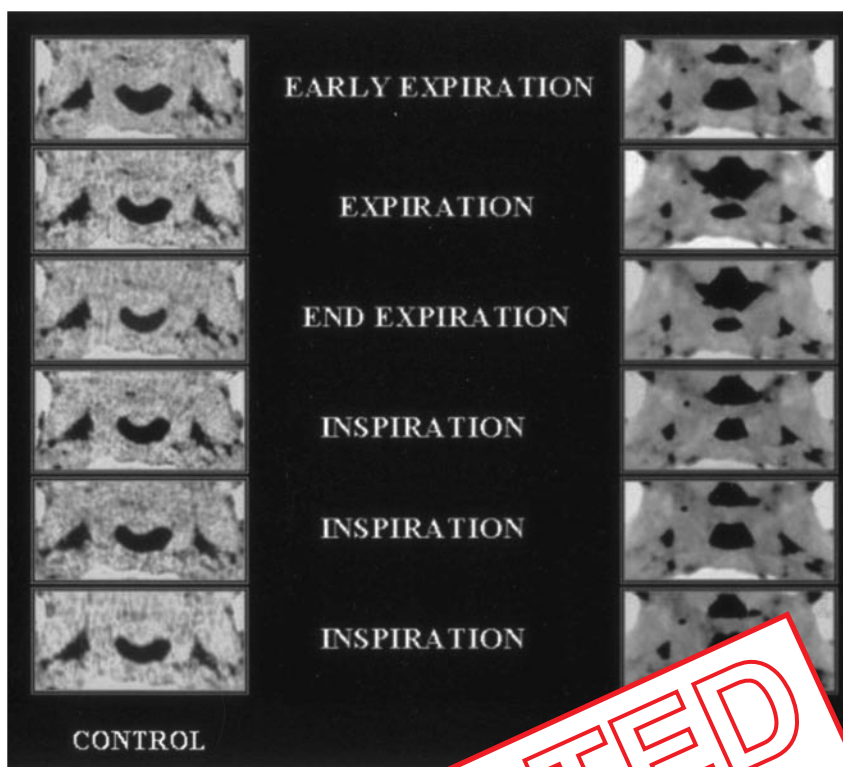


FIG 1. Axial cine CT scans show dynamic oropharyngeal airway changes in snoring patients and healthy control subjects.

CT Examination

An Xpress spiral CT (Toshiba, Toshiba-Ken, All subjects were positioned with their head in the supine position. The plane was perpendicular to the axis of the airway to breathe exclusively through the nose or talk during scanning. The CT scans were obtained from the nasion to the epiglottis level, or pharyngeal variations or diseases and the oropharyngeal (retropalatal) anatomic level. Subsequently, 24 scans were obtained at the same oropharyngeal level in approximately four full respiratory cycles while subjects were breathing through the nose. Each of the CT sections were obtained with 2-mm thickness in 0.6 seconds without table increment. This technique provided cross-sectional dynamic viewing of the airway during various phases of respiration. A fixed window level of 50 H and window width of 350 H was used for standardization of all scans.

Measurements

Axial images were played back in a closed-loop movie format so that real-time changes in cross-sectional area could be displayed (Fig 1). Two sections were chosen: one at the beginning of expiration, which had the widest airway area, and a second at the end of expiration and the beginning of the inspiration, where the narrowest airway area was demonstrated (12). On these two sections, anteroposterior and lateral dimensions of the airway and the thicknesses of left and right parapharyngeal fat pad, left and right pterygoid muscles, and left and right parapharyngeal walls were measured, and mean values were calculated for each section (Fig 2). For each subject, the difference of values in the widest and narrowest phases of the airway were calculated and used for statistical analysis.

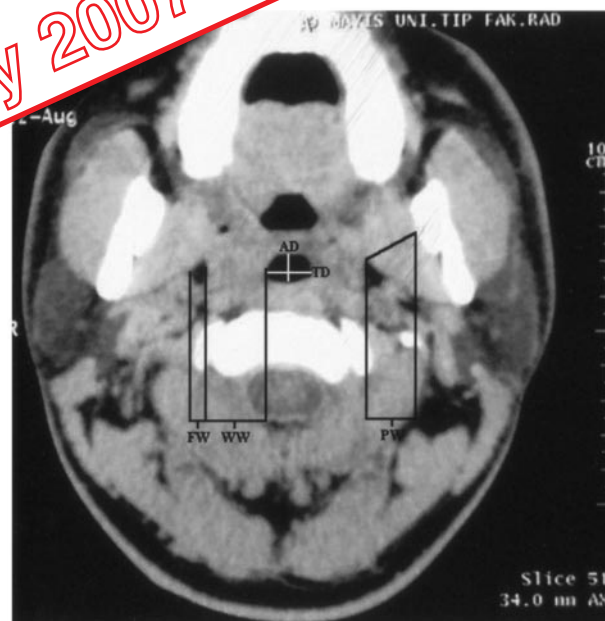


FIG 2. Axial CT image shows measurements at the oropharyngeal level. AD indicates anteroposterior airway diameter; FW, parapharyngeal fat pad width; PW, pterygoid muscle width; TD, transverse airway diameter; and WW, pharyngeal wall width.

Statistical Analysis

The paired *t* test was used to compare variables in the two groups. Pearson coefficients (*r*) were calculated to determine the relationship between variables.

greater than that of healthy individuals (18). With weight loss, upper-airway volume significantly increases while the volume of the lateral pharyngeal walls is reduced (19). However, to display the upper airway at the beginning, mid, and end of both expiration and inspiration, each section must be obtained in at least 0.4–0.6 second at the same level. Thus, volumetric analysis is not possible on dynamic cross-sectional imaging. On the other hand, volumetric and dimensional measurements are correlated. Since the dimensions of the pharyngeal airway change during the respiratory cycle, we performed dynamic scanning at the same anatomic level. Many investigators have shown that the oropharyngeal level is the most-affected part of the pharynx (7, 12, 20); therefore, we performed our scanning at this level.

Few studies of dynamic width changes at the parapharyngeal space are reported in the literature. In the present study, we found that the airway narrowing in snorers is predominantly in the lateral dimension, similar to the findings of Schwab et al (21). Two important soft-tissue components seen lateral to the airway are the parapharyngeal fat pads and the parapharyngeal walls. Investigators have noted that the fat pads play an important role in airway configuration. The fat pads are wider in snorers and apneic people than in others; therefore, the pads are closer to the airway and compress the airway laterally (18, 22–25). However, we did not find any important narrowing of the parapharyngeal fat pads in narrowing of the airway, as Schwab et al noted (21). Our study was similar to previous studies (18, 22–25), ours showed that the parapharyngeal fat pad was thicker in snorers (Fig 1, cine CT images). The fat pads could easily compress the airway rather than the fat pads compress the parapharyngeal walls into the airway.

Obesity is a known cause of sleep-disordered breathing, and weight loss is associated with improvements in the degree of the disorder (24, 26). None of our patients or control subjects was obese, and this may be the reason why we did not find narrowing of airways by the parapharyngeal fat pads in this study. Possibly, the mechanism between obesity and sleep-disordered breathing may have an alternative explanation, as Schwab et al offered (21). In addition, our patients with normal body habitus did not have this cause of pharyngeal narrowing. Rather, they had poor musculature dilatory mechanisms in the pharyngeal wall, as previous authors proposed. Some have noted that weight loss results in decreased muscle mass and a reduction in the size of the lateral pharyngeal walls (21).

The lateral pharyngeal wall has a complex structure made up of lymphoid tissue pharyngeal mucosa, and numerous muscles (hyoglossus, styloglossus, stylohyoid, stylopharyngeus, palatoglossus, palatopharyngeus, and pharyngeal constrictors) with varying functions. Although the changes in anteroposterior dimension were important in airway narrowing, the most significant airway changes occurred in the trans-

verse dimension. Both of these diameter changes were more prominent in snorers than in control subjects. Decreased lateral dimension of the airways can be explained by the significant increase in width of the pharyngeal walls during the respiratory cycle in snorers; however, this dimensional change was not clear in the control subjects. Hudgel (27) speculated that edema or inflammation of the pharyngeal tissues might narrow the upper airway. If his presumption is valid, wall thickening and upper-airway narrowing should persist in snorers during all phases of the respiratory cycle, since the thickness of inflamed and edematous walls should not change significantly from beginning to end of the expirium. In contrary to his suggestion (20), our results showed that the lateral pharyngeal walls in snorers were thinner than or nearly equal to the lateral pharyngeal walls in control subjects at the largest phase, whereas they become larger at the end of the expirium, the narrowest phase of respiration (Table 1). The changes of thickness of the lateral pharyngeal wall between the beginning and the end of expirium in snorers (4.14 mm) were significantly higher than the changes in control subjects (0.66 mm).

Our study showed that the lateral pharyngeal wall did not have sufficient widening of the airway at the end of the expiration. The narrowing of the lateral pharyngeal wall may be caused by hypertrophy of the lateral pharyngeal wall, the collapse from intraluminal pressure, or the negative inspiratory pressure, increased pulmonary resistance, prolonged inspiratory time, and inspiratory flow limitation are normal consequences of sleep (2). Snorers have higher negative inspiratory pressure, greater pulmonary resistance, prolonged inspiratory time, and flow limitation than others (28, 29). Moreover, some authors found that critical pressures required to collapse the upper airway vary from markedly negative in healthy people to less negative in nonapneic snorers to slightly positive in subjects with frank sleep apnea (30, 31). Smirne et al (32) demonstrated that snorers have an increased percentage of hypertrophic type IIa fibers in their medium pharyngeal constrictor muscle. Postural muscle tone is highest in wakefulness, decreased in non-REM sleep, and minimal or absent in REM sleep (33). Obstruction occurring in REM is likely to be more severe because of a loss of muscle tone, and it may last longer because of impaired arousal mechanisms (34). Although upper airway muscle tone decreases dramatically in REM sleep, airway resistance does not increase beyond the levels found in non-REM sleep (27). Greater muscle laxity in snorers or an increase in muscle mass due to weight gain or the exercise of overcoming apnea might explain the increase in the size of the lateral soft tissues (35).

Positive intraluminal pressure that expands in early expiration abates toward the end of expiration with resultant narrowing of the airway. Mahadevia et al (36) have demonstrated that expiratory positive air-

RETRACTED
16 July 2007

way pressure alone can effectively treat obstructive apneas. Snore sounds at the end of the expirium result from narrowing of the airway, which is caused by less positive pressure due to respiratory parameters such as low tidal volume or increased muscle mass in its inactive phase. Snore sounds at the phase of early inspirium occur due to gradual forceful opening of the closed airway caused by the aforementioned factors. In early inspirium, increased negative pressure and prolonged pharyngeal muscles laxity due to reduced strength and increased latency of the reflex muscle activity (15) cause a delay in adequate opening of the narrowed or obstructed airway; therefore, snore sounds occur.

Changes in the width of the pterygoid muscles were not significantly different between the two groups. We suggest that this tonus insufficiency did not affect this muscle group, and these muscles did not affect the airways.

Conclusion

In our study, changes in the thickness of the lateral pharyngeal wall was significantly related to airway diameter in snorers, whereas there was no notable change in the parapharyngeal fat pads. Narrowing of upper-airway area at the end of the expirium and the beginning of the inspirium, thought to be the cause of snoring, occurs because of augmented muscle activity and prolonged laxity rather than inadequate contraction of the pharyngeal dilating muscles.

1. Palomaki H, Partinen M. Obstructive sleep apnea syndrome, and snoring. *Am Rev Respir Dis* 1993;148:1385-1400
2. Hoffstein V. Snoring. *Am Rev Respir Dis* 1993;148:1385-1400
3. Block AJ, Boysen PG, et al. Pharyngeal fat, hypopnea and oxygen desaturation in a strong male population. *N Engl J Med* 1994;331:1327-1331
4. Wetter DW, Young TB, et al. Smoking as a risk factor for sleep-disordered breathing. *Arch Intern Med* 1994;154:2219-2224
5. Galvin JR, Rooholamini SA, Stanford W. Obstructive sleep apnea: diagnosis with ultra fast CT. *Radiology* 1989;171:775-778
6. Green DA, Block AJ, Collop AN, Hellard DW. Pharyngeal volume in asymptomatic snorers compared with nonsnoring volunteers. *Chest* 1991;99:49-53
7. Haponik EF, Smith PL, Bohlman ME, Allen RP, Goldman SM, Bleecker ER. Computerized tomography in obstructive sleep apnea. Correlation of airway size with physiology during sleep and wakefulness. *Am Rev Respir Dis* 1983;127:221-226
8. Bradley TD, Brown IG, Grossman RF, et al. Pharyngeal size in snorers, nonsnorers, and patients with obstructive sleep apnea. *N Engl J Med* 1986;315:1327-1331
9. Stein MG, Gamsu G, de Greer G, Golden JA, Crumley RL, Webb WR. Cine CT in obstructive sleep apnea. *AJR Am J Roentgenol* 1987;148:1069-1074
10. Schwab RJ, Gefter WB, Pack AL, Hoffman EA. Dynamic imaging of the upper airway during respiration in normal subjects. *J Appl Physiol* 1993;74:1504-1514
11. Ell SR, Jolles H, Galvin JR. Cine CT demonstration of nonfixed upper airway obstruction. *AJR Am J Roentgenol* 1986;146:669-677
12. Schwab RJ, Gefter WB, Hoffman EA, Gupta KB, Pack AL. Dynamic upper airway imaging during awake respiration in normal

- subjects and patients with sleep disordered breathing. *Am Rev Respir Dis* 1993;148:1385-1400
13. Beck R, Odeh M, Oliven A, Gavriely N. The acoustic properties of snores. *Eur Respir J* 1995;8:2120-2128
14. Sovijarvi ARA, Malmberg LP, Charnonneau G, et al. Characteristics of breath sounds and adventitious respiratory sounds. *Eur Respir Rev* 2000;10:77:591-596
15. Huang L, Williams JEF. Neuromechanical interaction in human snoring and upper airway obstruction. *J Appl Physiol* 1999;86:1759-1763
16. Hudgel DW, Hendricks C. Palate and hypopharynx-sites of inspiratory narrowing of the upper airway during sleep. *Am Rev Respir Dis* 1988;138:1542-1547
17. Arens R, McDonough JM, Costantino AT, et al. Magnetic resonance imaging of the upper airway structure of children with obstructive sleep apnea syndrome. *Am J Respir Crit Care Med* 2001;164:698-703
18. Shelton KE, Woodson H, Gay S, Suratt PM. Pharyngeal fat in obstructive sleep apnea. *Am Rev Respir Dis* 1993;148:462-466
19. Welch KC, Foster GD, Ritter CT, et al. A novel volumetric magnetic resonance imaging paradigm to study upper airway anatomy. *Sleep* 2002;25:532-542
20. Rivlin J, Hoffstein V, Kalbfleisch J, McNicholas W, Zamel H, Bryan AC. Upper airway morphology in patients with idiopathic obstructive sleep apnea. *Am Rev Respir Dis* 1984;129:355-360
21. Schwab RJ, Gupta KB, Gefter WB, Metzger LJ, Hoffman EA, Pack AL. Upper airway and soft tissue anatomy in normal subjects and patients with sleep-disordered breathing: significance of the lateral pharyngeal walls. *Am J Respir Crit Care Med* 1995;152:1673-1689
22. Horner RL, Mohsenifar V, Mateika JK, et al. Sites and sizes of fat deposits in the upper airway of obese patients with obstructive sleep apnea. *Eur Respir J* 1999;12:107-114
23. Smith PL, Gold AR, Meyers DA, Haponik EF, Bleecker ER. Weight loss in mildly to moderately obese patients with obstructive sleep apnea. *Ann Intern Med* 1985;103:850-855
27. Hudgel DW. Mechanisms of obstructive sleep apnea. *Chest* 1992;101:541-549
28. Stoohs R, Guilleminault C. Snoring during NREM sleep: respiratory timing, esophageal pressure and EEG arousal. *Respir Physiol* 1991;85:151-167
29. Skatrud JB, Dempsey JA. Airway resistance and respiratory muscle function in snorers during NREM sleep. *J Appl Physiol* 1985;59:328-335
30. Gledhill IG, Schwartz AR, Schubert N, et al. Upper airway collapsibility in snorers and in patients with obstructive hypopnea and apnea. *Am Rev Respir Dis* 1991;143:1300-1303
31. Schwartz AR, Smith PL, Gold AR, et al. Induction of upper airway occlusion in sleeping normal humans. *J Appl Physiol* 1988;64:535-542
32. Smirne S, Iannaccone S, Ferini-Strambi L, et al. Muscle fiber type and habitual snoring. *Lancet* 1991;337:597-599
33. Thompson SR, Ackermann U, Horner RL. Sleep as a teaching tool for integrating respiratory physiology and motor control. *Adv Physiol Educ* 2001;25:29-44
34. Phillipson EA, Kozar LF, Rebuck AS, Murphy E. Ventilatory and waking responses to CO₂ in sleeping dogs. *Am Rev Respir Dis* 1977;115:251-259
35. Ayappa I, Rapoport DM. The upper airway in sleep: physiology of the pharynx. *Sleep Medicine Reviews* 2003;7:9-33
36. Mahadevia AK, Onal E, Lopata M. Effects of expiratory positive airway pressure on sleep-induced respiratory abnormalities in patients with hypersomnia-sleep apnea syndrome. *Am Rev Respir Dis* 1983;128:708-711

RETRACTED

16 July 2007