



## Get Clarity On Generics

Cost-Effective CT & MRI Contrast Agents



FRESENIUS  
KABI

WATCH VIDEO

# AJNR

## Parent Vessel Occlusion for Vertebrobasilar Fusiform and Dissecting Aneurysms

R. Leibowitz, H.M. Do, M.L. Marcellus, S.D. Chang, G.K. Steinberg and M.P. Marks

*AJNR Am J Neuroradiol* 2003, 24 (5) 902-907

<http://www.ajnr.org/content/24/5/902>

This information is current as  
of August 7, 2025.

## Parent Vessel Occlusion for Vertebrobasilar Fusiform and Dissecting Aneurysms

R. Leibowitz, H.M. Do, M.L. Marcellus, S.D. Chang, G.K. Steinberg, and M.P. Marks

**BACKGROUND AND PURPOSE:** Previous reports of outcome with permanent vessel occlusion (PVO) for large, giant, or fusiform aneurysms in the posterior circulation have been limited. We undertook this study to evaluate the perioperative (within 30 days) and follow-up outcomes for patients treated with permanent occlusion of the vertebral artery for vertebrobasilar fusiform and dissecting aneurysms.

**METHODS:** Thirteen consecutive patients were studied. Two groups were defined for the study. Group I patients underwent PVO to achieve complete thrombosis of the aneurysm. Group II patients underwent PVO to reduce flow to the aneurysm where complete thrombosis was not desirable. Modified Rankin scores were obtained at presentation and at follow-up (follow-up range, 1–76 months; mean, 22.0 months).

**RESULTS:** All group I aneurysms were shown to be thrombosed on the angiograms obtained at the immediate follow-up examinations. Improvement in outcome scores was achieved by all group I patients. Improvement in Rankin scores after endovascular treatment was statistically significant ( $P = .026$ ). All group II patients had complete occlusion of the vertebral artery; however, continued filling of the fusiform aneurysm was still observed. Four patients in group II died during the follow-up period. Two of these deaths were attributable to the aneurysms. Of the remaining three patients, two experienced clinical worsening and one remained stable.

**CONCLUSION:** In this series, PVO for chronic fusiform and acute dissecting aneurysms of the vertebrobasilar system proved to be a useful therapeutic endovascular technique. Long-term outcomes suggest that patients with aneurysms involving only one vertebral artery, where complete thrombosis can be achieved, have better clinical outcomes than those who have aneurysms involving the basilar artery or both vertebral arteries, where complete thrombosis cannot be achieved by using PVO.

Nonsaccular aneurysms of the posterior circulation constitute a relatively uncommon subgroup of aneurysms. These aneurysms are difficult to treat because of their location and their morphology. Surgical access can be problematic (1), and the lack of a defined neck limits the therapeutic options available for endovascular or surgical occlusion. Patients harboring aneurysms with fusiform morphology encompass two groups with different clinical courses. One group is comprised of those with acute dissecting aneurysms, which involve a disruption of the internal elastic lamina and intramural hemorrhage. These dissecting aneurysms typically present with subarachnoid hemorrhage (SAH) or ischemia secondary to compromise of

the vessel lumen. The second group is comprised of those with chronic fusiform aneurysms, which may arise from various vascular abnormalities that cause a defect in the arterial media (2). These gradually enlarging aneurysms may result from congenital, acquired, or iatrogenic causes, and it is thought that atherosclerosis and hypertension may play a role in their development (3). Chronic fusiform aneurysms typically involve the posterior circulation (4, 5). Patients most often present with symptoms related to mass effect or intraluminal thrombosis and cerebral infarction, with SAH as a more rare presentation (4).

Sacrifice of the parent artery from which the aneurysm arises, a deconstructive procedure, has become a widely accepted approach to treatment of posterior circulation fusiform aneurysms. This can be performed surgically or with an endovascular approach. Advantages of endovascular treatment include the ability to monitor the neurologic status of an awake patient, to angiographically assess the adequacy of collateral flow, and to evaluate any residual flow after permanent occlusion has been performed. A review

---

Received July 26, 2002; accepted after revision November 26.  
From Stanford University Medical Center, Stanford, CA.

Address reprint requests to Michael P. Marks, MD, Associate Professor of Radiology and Neurosurgery, Department of Radiology, Room S.047, Stanford University Medical Center, Stanford, CA 94305.

of neurointerventional series using balloon occlusion for permanent vessel sacrifice suggests there is a lower rate of transient neurologic deficits and permanent deficits as compared with morbidity rates associated with surgical carotid occlusion therapy (4). Limited series that address the clinical outcome of patients treated with permanent vessel occlusion (PVO) for fusiform aneurysm of the vertebrobasilar system have been presented. The purpose of this retrospective study was to evaluate the periprocedural and follow-up outcomes of patients undergoing PVO of the vertebral artery for treatment of fusiform aneurysms.

## Methods

All consecutive patients treated at our institution between September 1997 and June 2000 for fusiform (either acute dissecting or chronic fusiform type) aneurysms of the posterior circulation were included in this study. Thirteen patients ranging in age from 45 to 78 years (mean, 61 years  $\pm$  12 SD), with a 2:11 ratio of women to men, were included. Three (23%) of the 13 patients presented with symptoms of mass effect, and the remaining 10 (77%) presented with SAH.

For the purposes of this study, patients were divided into two groups. Group I was comprised of patients in whom PVO was performed to achieve complete thrombosis of the aneurysm. Group I patients had aneurysms of the distal vertebral artery. Group II consisted of patients undergoing PVO for whom complete thrombosis was not desirable. Patients were allocated to group II most often for fusiform aneurysms at the vertebrobasilar junction or involving both vertebral arteries, in which sacrifice of both vertebral arteries would have been necessary for complete thrombosis of the aneurysm or aneurysms present.

Group I consisted of six patients (four men and two women; age range, 46–76 years; mean age, 58 years). Four patients were treated for fusiform aneurysms of the distal vertebral artery (two right and two left). Two patients were treated for dissecting aneurysms of the distal vertebral artery (one right and one left). In each case, the aneurysm was in a location at which complete thrombosis was possible.

Group II consisted of seven patients (seven men; age range, 45–78 years; mean age, 64 years). Five patients were treated for fusiform aneurysms of the distal vertebral artery and basilar artery (one involving the right and four involving the left vertebral artery). One patient was treated for a dissecting aneurysm involving the distal left vertebral artery and a fusiform aneurysm of the basilar artery, and one patient had bilateral traumatic distal vertebral artery dissections with a large dissecting aneurysm of the left vertebral artery and a small pseudoaneurysm of the left vertebral artery.

All patients underwent four-vessel angiography in advance of endovascular treatment. Patients were then evaluated by test occlusion for 20 to 30 min by using a nondetachable silicone balloon. At the time of test occlusion, neurologic evaluation was conducted by a neurologist and simultaneous electrophysiological monitoring was also performed.

Somatosensory evoked potentials and brain stem auditory evoked potentials were used to monitor cerebral ischemia in the posterior circulation during the procedure. This technique has been shown to be useful in surgical, as well as endovascular, aneurysm occlusion procedures (6, 7). Permanent occlusion was achieved by using detachable silicone balloons and/or GDCs (Target Therapeutics, Boston Scientific, Fremont, CA). Patients underwent anticoagulation during the procedure with a bolus of 5000 U of heparin and then 1000 U administered every hour if needed.

Clinical outcomes were assessed by using the modified Rankin Scale. The Wilcoxon signed rank test, a nonparametric test for paired samples, was used to evaluate statistical significance for any change in Rankin score.

Because intentional parent vessel occlusion was performed, patients did not undergo routine long-term angiographic surveillance. They were instead followed by clinical symptoms. Cross-sectional imaging was used in a few of the patients, as indicated by change in clinical symptoms. Six of the patients underwent follow-up MR imaging at 3 weeks to 28 months after treatment. The final clinical outcome of the patient was assessed by telephone interview, either with the patient or a primary caregiver, with a mean follow-up duration of 22.0 months (range, 1–76 months). A change in clinical status occurring within 30 days of the procedure was considered to be a perioperative complication.

## Results

All patients in this series passed provocative clinical and electrophysiological testing with temporary balloon occlusion. Table 1 shows the results of treatment. Five patients underwent primary balloon occlusion. One of these patients had the occlusion augmented by coils placed proximal to the balloon. Eight patients underwent primary occlusion with the use of platinum coils. All group I aneurysms showed no filling based on the immediate follow-up angiograms (Fig 1). In all group II patients, complete occlusion of the vertebral artery was achieved, but continued filling of the fusiform aneurysms was observed (Fig 2).

Clinical follow-up duration was a mean of 22.0 months (range, 1–76 months) for the 13 patients treated. Overall, two patients (15.4%) had Rankin scores between 0 and 2 at the time of treatment, with one of these patients in group I and one in group II. At the time of follow-up, three (50%) of six of the group I patients had good to excellent outcomes (Rankin scores, 0–2). All group I patients achieved improvement in their Rankin scores by the time of follow-up examination. The median Rankin score improved 2 points during post-treatment follow-up. This improvement in Rankin score after endovascular treatment was statistically significant (Wilcoxon signed rank test,  $P = .026$ ).

In contrast, only one (14.3%) of the patients in group II had achieved a good outcome by the time of follow-up examination, and that patient had a good Rankin score before treatment. Four deaths occurred in this group. Two of the deaths seemed to be related to continued mass effect on the brain stem from the aneurysm. Two patients died as a result of unrelated causes: one patient died as a result of complications of coronary artery disease and congestive heart failure, and the other suffered cardiac arrest. In the entire series, pretreatment modified Rankin scores ranged from 1 to 5, with a mean of 3.8. Follow-up modified Rankin scores ranged from 0 to 6, with a mean of 3.5.

One patient in group I developed recanalization of the aneurysmal segment, revealed by follow-up angiography. That patient presented with SAH and suffered subsequent SAH 2 weeks after PVO. Initial balloon occlusion had been performed in a proximal

TABLE 1: Clinical outcomes for patients undergoing parent vessel occlusion of the vertebral artery

	Age (y)/Sex	Group	Aneurysm Location and Type	Mode of Presentation	Method of Embolization	Months of Follow-up	Clinical Presentation (Modified Rankin Score)	Clinical Outcome (Modified Rankin Score)
1	48/F	I	R VA dis	SAH	Coil	2	4	2
2	56/M	I	L VA fus	SAH	Coil	14	5	4
3	46/M	I	R VA fus	SAH	Coil	10	1	0
4	52/M	I	L VA dis	SAH	Balloon	23	5	1
5	67/F	I	R VA fus	SAH	Coil	72	5	3
6	76/M	I	L VA fus	SAH	Coil	76	5	3
Mean	58					25.3		
7	52/M	II	L VB fus	SAH	Balloon	14	3	4
8	45/M	II	B VA dis	SAH	Coil	12	5	4
			L VA pa					
9	78/M	II	L VB fus	Mass effect	Coil	30	3	6
10	61/M	II	BA fus	SAH	Balloon + coil	1*	5	6
			L VA dis					
11	71/M	II	L VB fus	Mass effect	Coil	19	1	1
12	66/M	II	L VB fus	Mass effect	Coil	9	4	6
13	78/M	II	R VB fus	Mass effect	Balloon	4**	3	6
Mean	64					12.7		
Overall mean	61					22.0		

Note.—I indicates parent vessel occlusion for angiographic cure; II, parent vessel occlusion for angiographic palliation; R, right; L, left; VA, vertebral artery; dis, acute dissecting aneurysm; fus, chronic fusiform aneurysm; VB, vertebrobasilar; pa, pseudoaneurysm; SAH, subarachnoid hemorrhage.

\* Deceased at 1 month after procedure.

\*\* Deceased at 4 months after procedure; died in sleep.

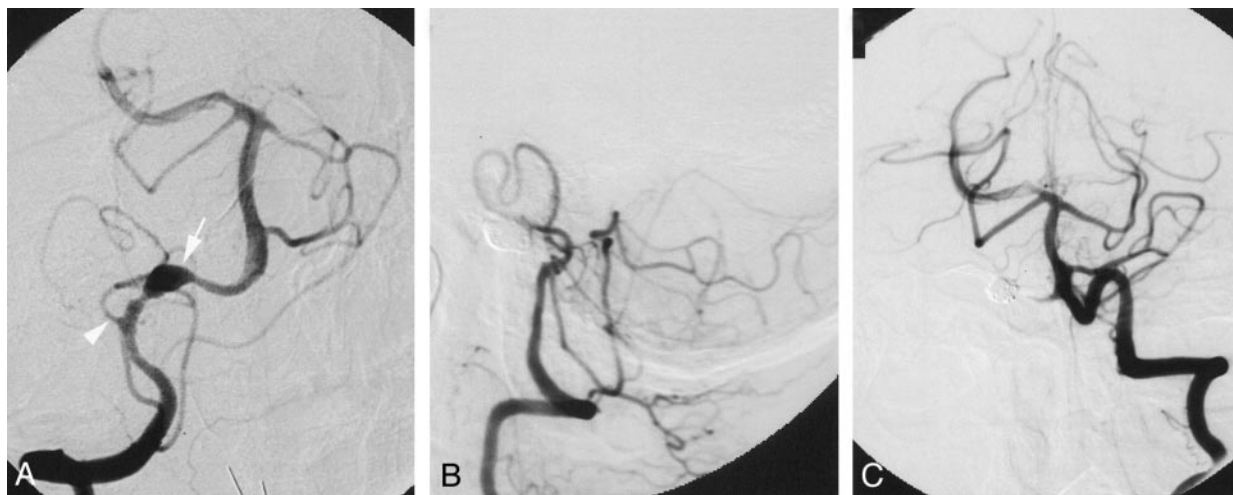


FIG 1. Images from the case of a 46-year-old man (patient 3 in group I) who suffered SAH from a fusiform aneurysm of the distal intracranial right vertebral artery.

A, Anteroposterior projection angiogram of the right vertebral artery disclosed a fusiform aneurysm of the distal intracranial portion (arrow) that is proximal to the vertebrobasilar junction and distal to the right posterior-inferior cerebellar artery (PICA, arrowhead).

B, Aneurysm and distal vertebral artery were embolized with coils. Lateral projection control angiogram of the right vertebral artery, obtained after embolization, shows preservation of flow to the right posterior-inferior cerebellar and basilar arteries.

C, Anteroposterior projection angiogram of the left vertebral artery shows preservation of flow to the right posterior-inferior cerebellar and basilar arteries. The patient achieved complete recovery and remained neurologically normal.

location, and the aneurysm had recanalized via collateral supply. The recanalized aneurysm required additional coil embolization that was performed by accessing the aneurysm through collateral vessels (Fig 1). The patient experienced no further events.

Two perioperative complications occurred in group I, and two occurred in group II. One patient in group II suffered a minor stroke 5 days after the procedure.

The patient had dysarthria. MR imaging revealed a small brain stem stroke. The patient achieved complete recovery from this event. Another group II patient died 1 month after the procedure, secondary to continued mass effect on the brain stem by the basilar aneurysm that was partially thrombosed. One patient in group I suffered a minor stroke the day after the procedure. MR imaging revealed a small left cerebel-



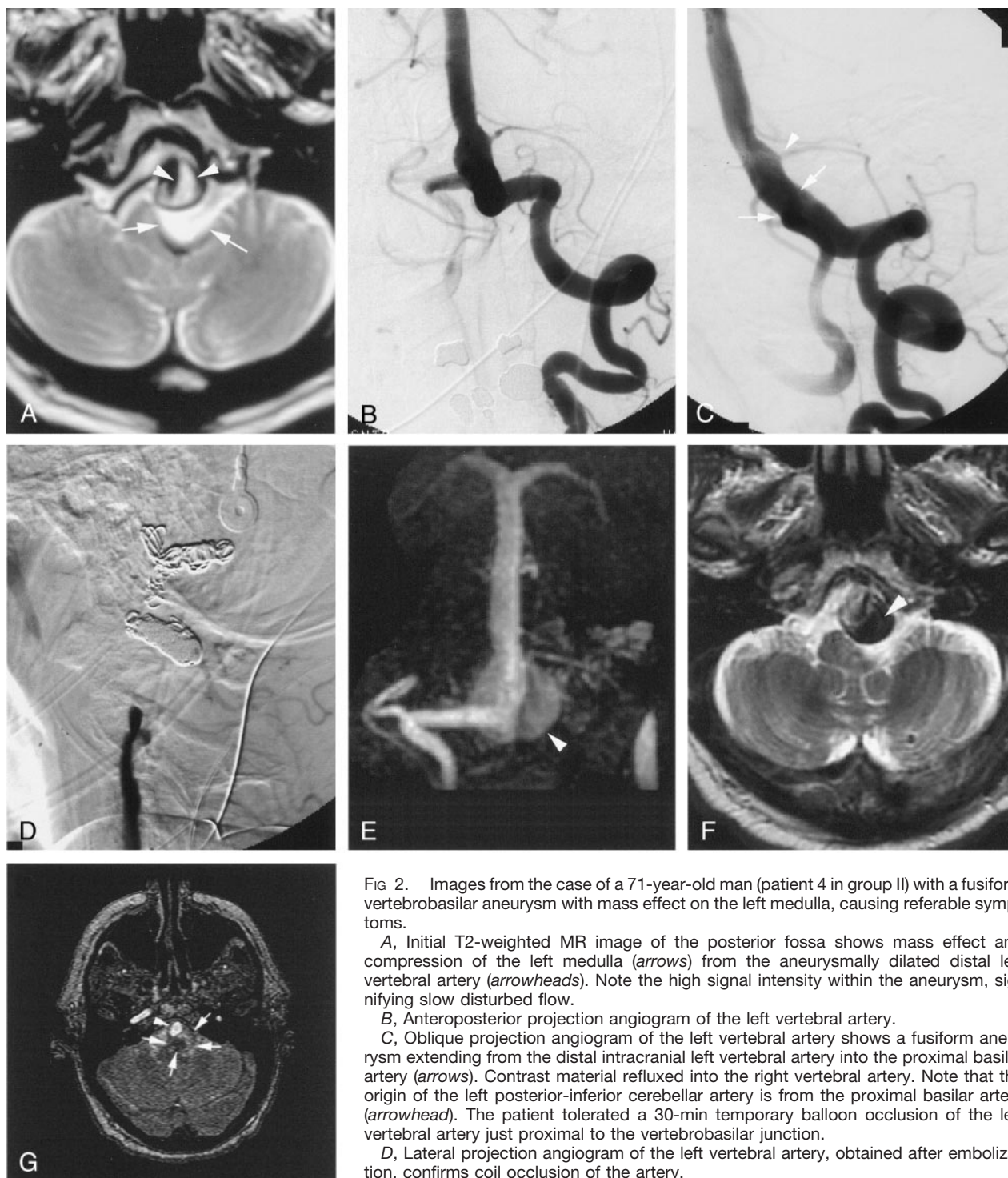


FIG 2. Images from the case of a 71-year-old man (patient 4 in group II) with a fusiform vertebrobasilar aneurysm with mass effect on the left medulla, causing referable symptoms.

A, Initial T2-weighted MR image of the posterior fossa shows mass effect and compression of the left medulla (arrows) from the aneurysmally dilated distal left vertebral artery (arrowheads). Note the high signal intensity within the aneurysm, signifying slow disturbed flow.

B, Anteroposterior projection angiogram of the left vertebral artery.

C, Oblique projection angiogram of the left vertebral artery shows a fusiform aneurysm extending from the distal intracranial left vertebral artery into the proximal basilar artery (arrows). Contrast material refluxed into the right vertebral artery. Note that the origin of the left posterior-inferior cerebellar artery is from the proximal basilar artery (arrowhead). The patient tolerated a 30-min temporary balloon occlusion of the left vertebral artery just proximal to the vertebrobasilar junction.

D, Lateral projection angiogram of the left vertebral artery, obtained after embolization, confirms coil occlusion of the artery.

E, Follow-up MR angiogram, obtained at 24 hr, shows preservation of blood flow to

the posterior fossa via the right vertebral artery with high signal intensity slow flow and/or thrombus within the distal left vertebral aneurysm (arrowhead).

F, Patient's symptoms improved after embolization. Axial view T2-weighted MR image obtained 18 months after embolization shows thrombosis of the proximal aneurysmal sac, as evidenced by low signal intensity (arrowhead).

G, MR angiogram obtained 18 months after embolization shows thrombosis of the proximal aneurysmal sac, as evidenced by lack of flow-related enhancement (arrows). Continued flow-related enhancement can be seen in the basilar artery (arrowhead).

lar stroke. Another patient developed recanalization and SAH, as discussed. None of these patients had a change in their Rankin scores as result of these complications.

## Discussion

Fusiform and dissecting aneurysms in the posterior circulation typically have a poor prognosis if left un-

treated. Rebleeding of ruptured dissecting aneurysms of the vertebral artery has been previously estimated to be between 24% and 30%; however, a retrospective study of patients with aneurysmal SAH occurring between 1985 and 1993, conducted at Tokyo University Hospital by Mizutani et al (8), reported a re-rupture rate of dissecting vertebrobasilar aneurysms as high as 71.4%. Twenty-nine of 30 of these aneurysms were in an "unsecured state" at the time of re-rupture, which means they either had not yet been surgically treated or they were being conservatively managed. Fifty-six and seven-tenths percent of the re-rupture events occurred within the first 24 hr after initial SAH, and 80% occurred within the first week after SAH.

One of the few treatment options available to these patients is PVO, either surgical or endovascular. The goal of PVO for the treatment of fusiform aneurysms is intra-aneurysmal thrombosis and involution of the aneurysm (9, 10). Endovascular PVO can be achieved with detachable balloons or coils or with a combination of the two. Studies reporting patient outcomes after PVO for treatment of fusiform aneurysms of the vertebrobasilar circulation have been limited.

A few series have reported the results of PVO in the posterior circulation, although not exclusively for intracranial fusiform aneurysms. A series presented by Aymard et al (9) examined the long-term outcomes for 21 patients with unclippable posterior circulation aneurysms treated with either unilateral or bilateral PVO of the vertebral artery, with a mean follow-up of 2 years (range, 6 months to 6 years). Six of the patients had fusiform aneurysms, and the remaining 15 had aneurysms that were of saccular morphology. All occlusions in this series were performed by using latex balloons. Thirteen (61.9%) of 21 patients achieved good outcomes, including angiographic cure and clinical improvement. Twenty-eight and six-tenths percent of the patients had partial thrombosis of their aneurysm. One death and one treatment failure occurred.

Halbach et al (10) reviewed the cases of 16 patients with vertebral artery dissections treated endovascularly between 1987 and 1992 at the University of California, San Francisco. Twelve of the cases involved intradural portions of the artery (and were therefore similar to the cases reported herein), and four involved the extradural segment of the artery. Fifteen patients were treated with PVO, and one patient underwent occlusion of a traumatic pseudoaneurysm with preservation of the parent artery. Two perioperative complications occurred. Balloons, coils, or a combination of both were used for endovascular occlusion. Of the 15 patients treated with a deconstructive approach, complete occlusion was documented on late follow-up angiograms for 14.

When the aneurysm is located at the vertebrobasilar junction or in the basilar trunk, PVO of the involved or dominant vertebral artery is performed to decrease blood flow and facilitate shrinkage of the aneurysm. The goal is to decrease the risk of rupture and minimize symptoms of mass effect (11). We

found a significant difference in outcomes for these patients, with relatively poor clinical recovery as compared with the subset of patients treated for angiographic cure. Although complete thrombosis of the sacrificed vertebral artery was achieved in these patients, residual filling of the aneurysm was noted on postprocedural angiography due to retrograde flow from the patent vertebral artery. Although the patient sample size in this retrospective study is too small from which to draw definitive conclusions, our data suggest that patients who undergo PVO for angiographic palliation do not fare as well as patients who achieve angiographic cure (see Table 1). This may indicate a need to evaluate an alternative approach to treating aneurysms that are not angiographically obliterated with unilateral vertebral PVO. One recent study reported the results for six patients with large vertebrobasilar aneurysms treated by using bilateral vertebral artery occlusion (12). Unfortunately, the outcomes in this small series were also not highly successful. Three (50%) of six showed good functional recovery, but the other three (50%) died. Two died as a result of documented complications associated with the aneurysms. For one who died during sleep, the cause of death could not be documented.

Our results indicate that patients who undergo PVO to decrease flow to the aneurysm without complete thrombosis fare worse than patients achieving cure. This finding is consistent with results presented by Steinberg et al (13), who reported that late neurologic complications occurred in only 4% of the patients with complete or virtually complete thrombosis, as compared with 45% of the patient subset that had incompletely thrombosed aneurysms when treated by surgical parent vessel occlusion. Eighty-five percent of the late neurologic complications in the subset with incomplete aneurysm thrombosis were fatal. These data suggest that the lack of complete thrombosis in these aneurysms represents a serious impediment to effective treatment.

Relatively new therapies are currently being investigated that may be applicable for the treatment of the population of patients addressed in this series. The use of intracranial stents in the treatment of aneurysms seems to be a promising technique, and it may be that stents will offer a better therapeutic approach when aneurysm occlusion cannot be achieved.

A recent report by Phatouros et al (14) shows the successful use of stent-supported coil embolization in the treatment of fusiform and wide neck aneurysms. The stent mesh allows for attenuated packing of the aneurysm with less concern for herniation of coils into the parent artery. Phatouros et al reported technical success in six of the seven patients treated, with 0% 30-day periprocedural morbidity and mortality. After a mean follow-up of 14.5 months, all the patients treated with stent-supported coil embolization were at their neurologic baseline or had improved. The authors acknowledged the current limitations of this therapy, including the concern for occluding small but important perforators with the struts of the stent.

In conclusion, the results of our study indicate that PVO with complete aneurysmal thrombosis for fusiform aneurysms of the posterior circulation is a good therapeutic option. This generally occurs when the aneurysm being treated involves one vertebral artery. PVO does not seem to be an effective therapy, however, when complete thrombosis cannot be achieved, as in the setting of aneurysmal involvement of the basilar artery or both vertebral arteries. Further investigation of treatment options for this subset of patients in whom PVO cannot achieve complete thrombosis is indicated.

## References

1. Kassell NF, Torner JC, Haley EC Jr, Jane JA, Adams HP, Kongable GL. **The International Cooperative Study on the Timing of Aneurysm Surgery: part 1. overall management results.** *J Neurosurg* 1990;73:18–36
2. Nakatomi H, Segawa H, Kurata A. **Clinicopathological study of intracranial fusiform and dolichoectatic aneurysms: insight on the mechanism of growth.** *Stroke* 2000;31:896–900
3. Schnee CL, Flamm ES. **Unusual aneurysms.** *Neuroimaging Clin N Am* 1997;7:803–818
4. Shokunbi MT, Vinters KV, Kaufmann JC. **Fusiform intracranial aneurysms: clinicopathologic features.** *Surg Neurol* 1988;29:263–270
5. Zager E. **Surgical treatment of intracranial aneurysms.** *Neuroimaging Clin N Am* 1997;7:763–782
6. Lopez JR, Chang S, Steinberg GK. **The use of electrophysiological monitoring in the intraoperative management of intracranial aneurysms.** *J Neurol Neurosurg Psychiatry* 1999;66:189–196
7. Liu A, Lopez JR, Cockroft KM, Steinberg GK, Do HM, Marks MP. **Neurophysiologic monitoring in the endovascular treatment of cerebral aneurysms.** Presented at the joint meeting of the AANS/CNS Section on Cerebrovascular Surgery and ASITN, New Orleans, February 2000
8. Mizutani T, Aruga T, Kirino T, Miki Y, Saito I, Tusuchida T. **Recurrent subarachnoid hemorrhage from untreated ruptured vertebrobasilar dissecting aneurysms.** *Neurosurgery* 1995;36:905–913
9. Aymard A, Gobin YP, Hodes J, et al. **Endovascular occlusion of vertebral arteries in the treatment of unclippable vertebrobasilar aneurysms.** *J Neurosurg* 1991;74:393–398
10. Halbach VV, Higashida RT, Dowd CF, et al. **Endovascular treatment of vertebral artery dissections and pseudoaneurysms.** *J Neurosurg* 1993;79:183–191
11. Byrne J, Guglielmi G. **Results of endovascular treatment.** In: *Endovascular Treatment of Intracranial Aneurysms*. Berlin: Springer-Verlag; 1998:208–233
12. Sluzewski M, Bilstra EH, van Rooij WJ, Tulleken CA, Rinkel GH. **Bilateral vertebral artery balloon occlusion for giant vertebrobasilar aneurysms.** *Neuroradiology* 2001;43:336–341
13. Steinberg GK, Drake CG, Peerless SJ. **Deliberate basilar or vertebral artery occlusion in the treatment of intracranial aneurysms: immediate results and long-term outcome in 201 patients.** *J Neurosurg* 1993;79:161–173
14. Phatouros CC, Sasaki TY, Higashida RT, et al. **Stent-supported coil embolization: the treatment of fusiform and wide-neck aneurysms and pseudoaneurysms.** *Neurosurgery* 2000; 47:107–115