



Get Clarity On Generics

Cost-Effective CT & MRI Contrast Agents



FRESENIUS
KABI

WATCH VIDEO

AJNR

Postmortem MR Imaging of the Fetal and Stillborn Central Nervous System

Paul D. Griffiths, Dick Variend, Margaret Evans, Angharad Jones, Iain D. Wilkinson, Martyn N. J. Paley and Elspeth Whitby

This information is current as of August 2, 2025.

AJNR Am J Neuroradiol 2003, 24 (1) 22-27
<http://www.ajnr.org/content/24/1/22>

Postmortem MR Imaging of the Fetal and Stillborn Central Nervous System

Paul D. Griffiths, Dick Variend, Margaret Evans, Angharad Jones, Iain D. Wilkinson, Martyn N. J. Paley, and Elspeth Whitby

BACKGROUND AND PURPOSE: Changes in the public perception of postmortem procedures in the United Kingdom have led to reduced numbers of autopsies being performed in the fetus and neonate. When autopsy is performed in this group, the brain is now usually studied without being formalin-fixed, which limits the available information. We evaluated the diagnostic accuracy of postmortem MR imaging of the fetal brain and spine when compared with the reference standard, autopsy.

METHODS: We obtained high-spatial-resolution T2-weighted images (in-plane resolution approximately 0.4 mm) of the brain and spine in 40 fetuses and stillborn neonates (14–42 weeks gestational age) who were referred for autopsy. The MR findings were compared with those of autopsy, the reference standard, which had been performed independently.

RESULTS: In eight cases, the autopsy did not provide structural information of the brain or spine, because assessment of the unfixed tissue was impossible. There was agreement between MR and autopsy findings in 31 (97%) of 32 cases in which comparison could be made. Eleven cases showed normal brain, and 20 cases showed a wide range of developmental and acquired abnormalities. The sensitivity of MR was 100%, specificity 92%, positive predictive value 95%, and negative predictive value 100%.

CONCLUSION: MR imaging has a useful role in providing structural information of the central nervous system in fetuses and stillborn neonates.

The loss of a fetus or baby soon after birth presents many parents with a difficult dilemma. Many parents would like to know why their child died and if there is an increased risk of abnormalities in future pregnancies. At this time, the accepted method of providing this information is by autopsy, which is sometimes supplemented by chromosomal and/or genetic studies. There are several, well-publicized difficulties that have developed recently in the United Kingdom in relation to alleged organ retention without formal consent from parents. This has led to a substantial reduction in the number of parents agreeing to autopsy in our practice, which has decreased the amount of information that can be used for counseling, for giving advice for future pregnancies, and for clinical audit. These problems have been highlighted by the UK chief medical officer in two recent publications (1, 2).

Even if autopsy is performed, alterations to the

autopsy procedure, brought about by pressure from nonmedical sources, has reduced the amount of information available from autopsy. Until recently, usual practice has been to remove and fix the brain before dissection, a process that can take up to 3 weeks. The situation at our institution is that parents must specifically consent to organ removal and fixation, and most do not agree to this. Parents now frequently request that all organs must be replaced before burial, which makes adequate fixation impossible. This means that the brain must be investigated unfixed in many cases, a state that makes interpretation of the brain difficult, particularly when the brain is immature. This is compounded in the presence of autolysis, which is common after a period of in utero retention after death. Autolysis usually affects the fetus after an interuterine fetal death or stillborn baby most severely but is also seen in termination of pregnancy for fetal abnormality, as death frequently occurs before delivery.

Investigation of the spinal cord is an essential part of the fetal autopsy process, but the immature cord is difficult to examine, because dissection of the spine causes structural disruption. These problems are compounded when dealing with unfixed tissue.

The UK chief medical officer has recommended

Received April 25, 2002; accepted after revision August 15.

From the Section of Academic Radiology, University of Sheffield (P.D.G., A.J., I.D.W., M.N.J.P., E.W.), and the Department of Pathology, Sheffield Children's Hospital (D.V., M.E.), Sheffield, UK.

Address reprint requests to Paul D Griffiths, M.D., Section of Academic Radiology, University of Sheffield, Floor C, Royal Hallamshire Hospital, Glossop Rd, Sheffield S10 2JF, UK

that modern imaging methods should be evaluated as an alternative to autopsy (2, recommendation no. 17). Imaging has been used for many years in the study of postmortem abnormalities of fetuses and neonates, but this has been limited to conventional radiology, usually to assess the chest or bones. The purpose of this study was to evaluate the findings of postmortem MR imaging of the central nervous system in fetuses and stillborn neonates and to compare these findings with those of autopsy.

Methods

This study was performed under the guidance and with the consent of the South Sheffield, UK, local ethics committee (SSLREC 00/239).

Case Recruitment

Cases were recruited from the pediatric pathology department based at our institution in Sheffield, UK. This is the subregional referral center for fetal and pediatric autopsies, and approximately 200 fetal and neonatal autopsies are performed per year. The 40 cases evaluated in this study were recruited over a period of 8 months (March 2000 to October 2000). These were not consecutive cases, as limited time with the MR imager resulted in some of the referred cases not undergoing MR imaging. The parents consented to both formal autopsy and MR imaging. No parents refused the addition of MR imaging to the routine autopsy procedure.

Procedures

All examinations were performed with a 1.5-T superconducting system (Eclipse; Philips Medical Systems, Best, the Netherlands). Brain imaging consisted of high-spatial-resolution imaging in the three orthogonal planes by using fast spin-echo methods to produce T2-weighted images. We have found these to be optimal in our pilot studies owing to the absence of myelin at this stage of development (see Discussion). The sequences consisted of fast spin-echo (echo train length, 32) T2-weighted images (15,662/92 ms [TR/TE]) with a bandwidth of 20.8 kHz and four acquisitions. A wrist or knee coil was used with a field of view 14 cm, matrix size of 256×256 (giving an in-plane resolution of 0.5 mm), and 2-mm-thick sections (no intersection gap) of the whole brain in the three natural orthogonal planes. The spine was imaged by using comparable sequences in the sagittal plane and either axial or coronal plane depending on the expected or demonstrated abnormality. The

bodies were stored in a standard refrigerated environment before imaging.

Brain and spine images were reviewed by a pediatric neuroradiologist (P.D.G.) and a neonatal radiologist (E.W.). Comparison was made with the autopsy findings as described below.

Autopsy was performed by one of two experienced pediatric pathologists (M.E. or D.V.) who did not know the results of the MR examination at the time of preparing the autopsy report. The autopsy was performed the same day or the day after MR imaging by using what are considered to be standard methods in the United Kingdom at present. The brain and spine were examined in an unfixed state that consisted of external macroscopic inspection and weighing. The brain stem and cerebellum were separated, and the cerebral hemispheres divided to assess the medial contours. Tissue samples were taken from one cerebral hemisphere, the brain stem, and cerebellum. These samples were fixed before histologic studies were performed. The organs were then returned to the body for burial or cremation according to the parents' wishes.

The MR findings were compared with the findings from autopsy and in most cases could be grouped into one of four categories, by using autopsy as the reference standard: true-positive, abnormal brain or spine with comparable information from imaging and autopsy; true-negative, normal brain or spine as shown on MR images and confirmed at autopsy; false-positive, brain or spine incorrectly reported as abnormal on MR images; false-negative, brain or spine incorrectly reported as normal on MR images. In the remaining cases, a definitive answer could not be obtained from autopsy. This occurred in cases when the unfixed brain could not be assessed adequately because of the poor physical state of the unfixed brain.

Patient Demographics

Among the 40 cases, there were 20 male and 20 female fetuses or stillborn neonates. The gestational age was estimated by a combination of the woman's last menstrual period and the assessments made at sonography around 20 weeks after the last menstrual period. The mean gestational age was 24 weeks (range, 14–42 weeks; interquartile range, 18–29 weeks); the later-gestational-age cases were all dead at birth. The mean postmortem delay to MR imaging was 5 days (range, 1–14 days; interquartile range, 3–7 days), and these figures include the period of time that the fetus had demised in utero, where appropriate. The autopsy was performed on the same day or the day after MR imaging in all cases.

Results

In 32 (80%) of the 40 cases, the MR study was subjectively rated as good or excellent quality (Fig 1).

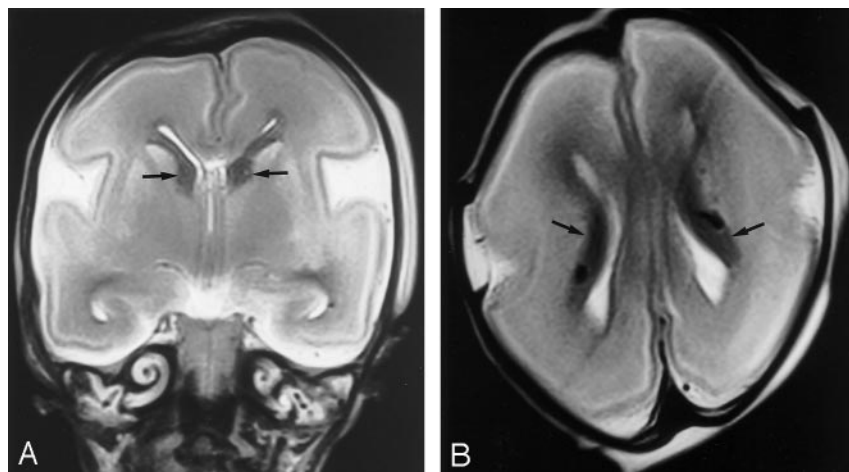


FIG 1. A, Coronal and B, axial brain MR images in a spontaneously aborted 22-week fetus. The image quality was assessed as excellent and findings reported as normal, which agreed with the autopsy report. The dark structures (arrows) in the immediate periventricular regions are the germinal matrices. Migrating neurons are shown in cerebral hemispheres as gray matter signal intensity against the high signal intensity of the white matter.

TABLE 1: Results of Eight MR Examinations in Which No Structural Information Was Obtained from Autopsy Because of the Physical State of the Brain

Abnormality	No. of Cases
Normal	2
Agenesis of corpus callosum	2
Agenesis of corpus callosum and rhombencephalosynapsis	1
Holoprosencephaly (see Fig 2)	1
Germinal matrix hemorrhage	1
Hypoxic or ischemic damage	1

Eight were rated as poor-quality examinations, and in all but one of the eight cases, the fetuses were at 14–17 weeks' gestation.

In eight (20%) of 40 cases, the condition of the unfixed brain was such that no autopsy information could be gathered; therefore, formal comparison between MR and autopsy findings could be made in only 32 cases. The MR findings of those eight cases are shown in Table 1, with an example is shown in Figure 2. In 28 (88%) of 32 cases, there was complete agreement between MR and autopsy findings at the first assessment. These consisted of normal brains (11) and a wide range of developmental and acquired abnormalities (17); the abnormalities are listed in Table 2, with examples shown in Figures 3 and 4. In four cases, there was disagreement between the MR and autopsy results on the initial assessment. These cases were subjected to consensus review by a pediatric neuroradiologist (P.D.G.) and a pediatric pathologist (D.V.) and are listed in Table 3. In three cases, review confirmed the MR findings, and in one case the MR interpretation incorrectly reported colpocephaly (selective dilatation of the trigones and

occipital horns of the lateral ventricles). The overall sensitivity of MR imaging was 100%, specificity 92%, positive predictive value 95%, and negative predictive value 100%.

Discussion

Events in children's hospitals across the United Kingdom have caused the search for methods to assist formal autopsy (1, 2). We present our experience with using high-spatial-resolution MR imaging of the brain and spine of fetuses and a smaller number of stillborn neonates before autopsy. The brain and spine were chosen in this initial evaluation for a number of reasons, both practical and theoretical. Developmental abnormalities of the central nervous system are common, and our group has particular imaging expertise in this field. In addition, there are major practical problems associated in performing autopsy on central nervous system structures without formalin fixation. The fetal or stillborn brain is difficult to handle even with adequate fixation, even after modest postmortem delay (3, 4). This is due, in part, to the high water content of the immature brain compared with that of the adult brain. Parental concerns about organ retention have resulted in requests of not removing the brain for fixation (which can take weeks); therefore, many brain studies are being performed on nonfixed tissue. This makes structural analysis difficult, as shown by the 20% failure rate found in this study. Similar problems are found with the spinal cord, but these are compounded by the small size of the cord and disruption often caused by removal from the bony canal. The considerable delays between fetal demise and autopsy probably contribute to the difficulty in handling the brain, as autolysis makes the tissue even more fluidlike. It should be noted, how-

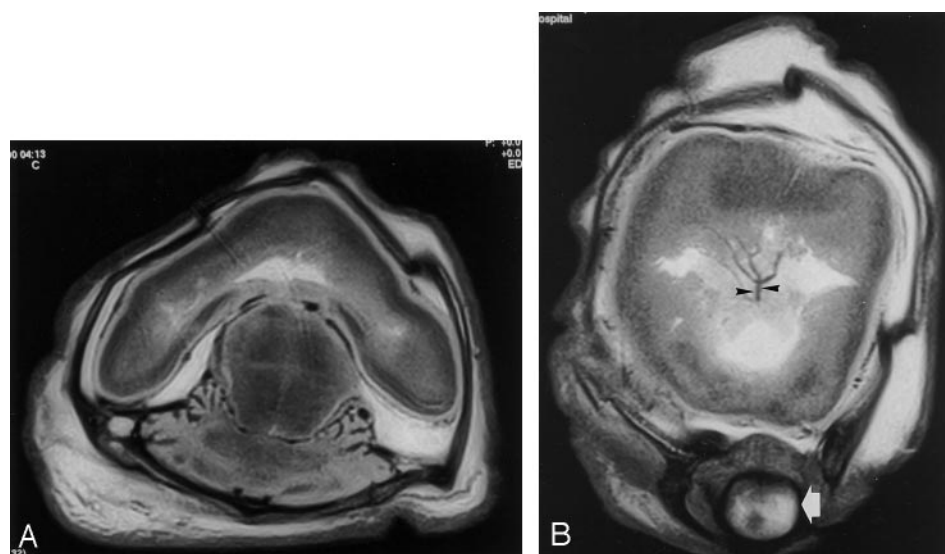


FIG 2. MR images of a fetus after therapeutic abortion at 18 weeks because of a sonographic diagnosis of alobar holoprosencephaly. Autopsy could not provide any information because of the poor state of the unfixed brain.

A, Axial and B, coronal brain MR images confirm the typical features of alobar holoprosencephaly: nonseparated cerebral hemispheres, holoventricle, and fused thalami. Note the single, poorly formed orbit (cyclopia) (arrow) and an azygous anterior cerebral artery (arrowheads).

TABLE 2: Results of 17 Cases in Which MR Imaging and Autopsy Agreed on the Nature of Abnormal Findings on First Analysis

Abnormality	No. of Cases
Isolated ventriculomegaly	4
Myelomeningocele and Chiari II malformation (see Fig 3)	4
Dandy-Walker malformation	3
Holoprosencephaly	2
Germinal matrix hemorrhage	1
Hypoxic or ischemic damage	1
Ruptured arteriovenous malformation	1
Diastematomyelia	1

ever, that the inclusion of MR imaging in the process did not account for the delay.

MR imaging has been used as an alternative to autopsy in adults; the technique is described in a letter to the *British Medical Journal* (5), but the authors did not present comparative data. There are several reports of using MR imaging to study the formalin-fixed fetus post mortem. These have usually been performed on fetuses in museum collections and were designed to study aspects of brain development rather than the assessment of abnormalities in a clinical environment. One of our group (I.D.W.), along with colleagues from the Middlesex Hospital in London, previously reported on 3D MR imaging of the fetus post mortem (6), and the same group performed an MR versus autopsy study in 1996 (7). That article described 20 aborted or stillborn cases in which MR imaging was used to perform whole-body imaging. MR imaging was performed in situ and, presumably, on unfixed tissue. Technical details of the autopsy were not published but held by the editor-in-chief of *The Lancet*. The authors found agreement between MR imaging and autopsy findings in eight of 20 cases, and in four of 20 cases, MR imaging provided more

information when compared with autopsy. In the remaining eight cases, autopsy provided more information than MR imaging. The overall sensitivity for MR imaging in the detection of abnormalities in that study was 60% compared with 100% in the cases in our study. This is probably because we studied only the central nervous system and there has been a considerable improvement in the quality of MR imaging over the last few years. Woodward et al (8) describe the results of 26 postmortem MR examinations on intact, nonfixed fetuses; they compared the findings with autopsy results, although the authors do not specify if fixed tissue was used. Their cases consisted mainly of body abnormalities as opposed to the central nervous system; however, they commented that MR imaging was particularly useful for assessing central nervous system structures. In that study, 37 (79%) of 47 major abnormalities were shown on MR images but only one of 11 minor abnormalities.

The choice of sequence parameters was important for this study and required empirical experimentation in earlier pilot studies. MR imaging of the type described in this study has advantages and disadvantages when compared with MR imaging in a living, adult patient. MR imaging is exquisitely sensitive to patient movement, which imposes limits on the image acquisition time. This is not an issue when imaging post mortem, and long acquisitions with improved signal-to-noise ratios can be obtained. The major disadvantages, both theoretical and practical, are explained by the chemical differences between the brains of fetuses or stillborns and those of adults, and it is necessary to review the issue of resolution in brain imaging at this point. Anatomic resolution (the smallest objects that can be resolved as separate) is dependent on the field of view and matrix size, and MR imaging and CT are broadly comparable in this respect. One of the major advantages of MR over CT,

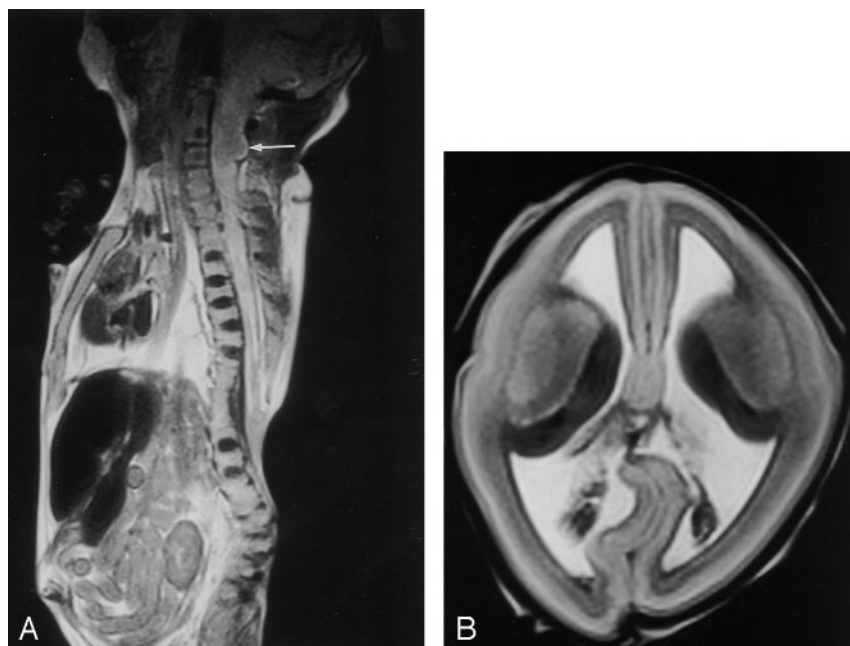


FIG 3. A, Sagittal spine and B, axial brain MR images in a 20-week fetus after a therapeutic abortion because of a sonographic diagnosis of myelomeningocele and Chiari II malformation. These findings were confirmed with postmortem MR imaging and autopsy. The spine MR image (A) shows a low thoracic myelomeningocele with an adjacent complicated fusion defect of the lower thoracic-upper lumbar vertebral bodies. There is also extensive syringohydromyelia. The cerebellar tonsils (arrow) are abnormally low (at C3), indicating a Chiari II abnormality, and images of the brain (not shown) confirmed the presence of a small posterior fossa. This brain MR image (B) shows ventriculomegaly and the "lemon-shaped" deformity recognized on sonograms in cases such as these.

FIG 4. A, Axial and B, right parasagittal MR images in a 21-week fetus after therapeutic abortion performed on the basis of a parietal meningocele on sonograms. This was reported as such at autopsy. MR images show that there is also brain and ventricle in the abnormality (therefore, technically a meningoencephalocystocele). In addition, the MR images show an area of cortical dysplasia (arrow) in the right frontal lobe that was not reported at sonography or autopsy. This was confirmed at consensus review. Note the generalized reduction in volume of migrating neurons in the right cerebral hemisphere.

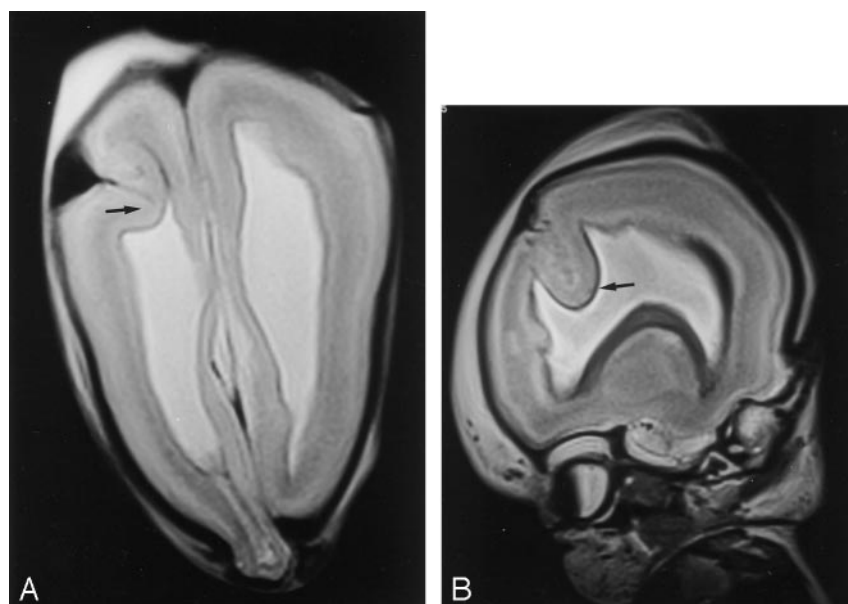


TABLE 3: Consensus Reports of Four Cases in Which MR and Autopsy Findings Disagreed on the Initial Assessment

MR Findings	Autopsy Findings	Consensus Report
Parietal encephalocele, frontal cortical dysplasia (see Fig 4)	Parietal meningocele	Parietal encephalocele, frontal cortical dysplasia
Ventriculomegaly due to aqueduct stenosis	Dandy-Walker malformation	Ventriculomegaly due to aqueduct stenosis
Dandy-Walker malformation	Normal	Dandy-Walker malformation
Colpocephaly	Normal	Normal

however, is that the improved tissue contrast between the chemical differences of gray matter and white matter can be exploited. MR images rely on hydrogen nuclei, and the most abundant forms in the body are water and lipids. There is approximately 82% water in gray matter and 72% water in myelinated white matter (9). There is far more lipid in myelinated white matter when compared with gray matter (54.9% vs 32.7%) (10). These two factors account for the superb gray matter–white matter distinction on MR images, particularly on T1-weighted images in the adult, fully myelinated brain.

The major difference in the brains of fetuses or stillborns when compared with that of the adult is the virtual complete absence of myelin. This means that the water content and lipid content of gray and “white” matter are very similar. In this situation, it would be expected that the tissue contrast should be poor, and this is borne out on T1-weighted images. Some contrast is present on T2-weighted images, but this is modest. Conditions present in the fetal brain greatly improve tissue contrast above that expected. The second trimester is an exceptionally active period of neuronal proliferation and migration. The developing neurons are situated in the immediate, periventricular germinal matrices, which were shown to have low signal intensity in our studies. We have shown that MR imaging can also depict a complicated internal structure that appears to correspond to the waves of migrating neurons shown on histologic studies

(11). This set of circumstances produces the high tissue contrast in postmortem fetal studies, and similar findings have been observed in our work with the in utero fetal brain (12). The only major difference we see between postmortem and in utero fetal brains, allowing for the different techniques used, is in the size of the extraaxial spaces. These are smaller in the postmortem brain, presumably because of loss of CSF pressure. Similarly, this is the only major difference we see between live neonates and stillborn babies of the same maturity.

We have described our experience with MR imaging to provide structural information of the brain and spine in fetuses and stillborn neonates that is usually obtained from autopsy. We have shown that MR imaging is as accurate as autopsy, as it is performed in our department currently when providing macroscopic detail of brain and spine anomalies. In some situations, we have shown MR imaging to be superior to autopsy of an unfixed brain; the ability to image the brain in situ is a particular advantage. The demonstration of an abnormality in the extraaxial compartment is, theoretically, a major advantage of MR imaging over autopsy. The results of our more recent work appear to confirm this with the demonstration of abnormality at that site with a surprisingly high frequency that was not reported at all on autopsy.

We have described a group of cases with a relatively high prevalence of central nervous system abnormalities (20 [63%] of 32). It is not likely that this

high figure was introduced by selection bias at the time of MR imaging, because the expected diagnosis on prenatal images (normal or otherwise) was not known until the fetus or stillborn neonate arrived in the MR department. It is more likely that any selection bias in our study was produced by the parents' knowledge of a structural abnormality. That is, we would predict that parents are more likely to consent to autopsy if a central nervous system abnormality is suspected than if no abnormality is expected.

We have already outlined the changes in attitude to fetal and neonatal autopsy in the United Kingdom and the changes in autopsy procedures that have been brought about. Our early work is encouraging, but several points remain to be answered. Formal autopsy evaluates the whole body, whereas we have studied only the brain and spine. We believe that MR imaging will be good at evaluating body structures on the basis of the detail we have seen in the thorax and abdomen during spine imaging, although we have not assessed this formally. In the few cases we have seen with neural and body malformations, MR imaging has shown the abnormalities. It is possible that MR and CT in combination will be a powerful method of performing imaging-based autopsy procedures.

The disadvantage of MR imaging is that histologic examinations cannot be performed. Microscopy is carried out to assess causation and to answer questions such as determination of gestational age and time of death. One solution to this problem is to extend the use of postmortem imaging to direct a minimally invasive "biopsy-type" procedure. However, limited sampling of tissue is likely to be a considerable disadvantage to such an approach, and if this method comes into widespread use parents would have to understand that some information could be missed.

Conclusion

We describe our early experience with performing postmortem MR imaging of the fetus and stillborn neonate. We have shown a close relationship between the diagnoses made with MR imaging and the reference standard, the autopsy.

References

1. The Chief Medical Officer. **Report of a census of organs and tissues retained by pathology services in England.** London, England: The Stationery Office, Department of Health, 2000
2. The Chief Medical Officer. **The removal, retention and use of human organs and tissues from post mortem examination.** London, England: The Stationery Office, Department of Health, 2001
3. Cartledge PHT, Dawson AT, Stewart JH, Vujanic GM. **Value and quality of perinatal and infant post mortem examinations: cohort analysis of 400 consecutive cases.** *BMJ* 1995;310:155-158
4. Vujanic GM, Cartledge PHT, Stewart JH, Dawson AT. **Perinatal and infant post mortem examinations: how well are we doing?** *J Clin Pathol* 1995;48:998-1001
5. Bissett R. **Magnetic Resonance Imaging may be an alternative to necroscopy (letter).** *BMJ* 1998;317:1450
6. Brookes JAS, Deng J, Wilkinson ID, Lees WR. **Three-dimensional imaging of the postmortem fetus by MRI: early experience.** *Fetal Diagn Ther* 1999;14:166-171
7. Brookes JAS, Hall-Craggs MA, Lees WR, Sama VR. **Non-invasive perinatal necroscopy by magnetic resonance imaging.** *Lancet* 1996;348:1139-1141
8. Woodward PJ, Sohaey R, Jackson DP, Klatt EC, Alexander AL, Kennedy A. **Post mortem MR imaging: Comparison with findings at autopsy.** *AJR Am J Roentgenol* 1997;168:41-46
9. Van der Knaap MS, Valk J. **Myelin and white matter.** In: Van der Knaap MS, Valk J, eds. *Magnetic resonance of myelin, myelination and myelin disorders.* 2nd ed. Berlin: Springer-Verlag; 1995:1-17
10. Norton WT, Cammer W. **Isolation and characterization of myelin.** In: Morrel P, ed. *Myelin.* New York: Plenum; 1984:147-195
11. Feess-Higgins A, Larroche JC. In: Feess-Higgins A, Larroche J-C, eds. *Development of the human foetal brain: an anatomical atlas.* Paris, INSERM CNRS, 1987:13-189
12. Whitby E, Paley MN, Davies N, Sprigg A, Griffiths PD. **Ultrafast MR assessment of CNS abnormalities in third trimester pregnancy: methodology and early experience.** *Br J Obstet Gynaecol* 2001;108:519-526