



**Providing Choice & Value**  
Generic CT and MRI Contrast Agents

**FRESENIUS  
KABI**

**CONTACT REP**

# AJNR

## Erratum

*AJNR Am J Neuroradiol* 2002, 23 (4) 742  
<http://www.ajnr.org/content/23/4/742.2>

This information is current as  
of July 23, 2025.

## Erratum

In the article **Effect of Guglielmi Detachable Coils on Intraaneurysmal Flow: Experimental Study in Canines**, Sorteberg A, Sorteberg W, Rappe A, and Strother CM; AJNR 23:288–294, February 2002, several figure legends were transposed. The legend for Figure 3 should have appeared with Figure 5; the legend for Figure 4 should have appeared with Figure 3; and the legend for Figure 5 should have appeared with Figure 4. The correct legend placement is shown below.

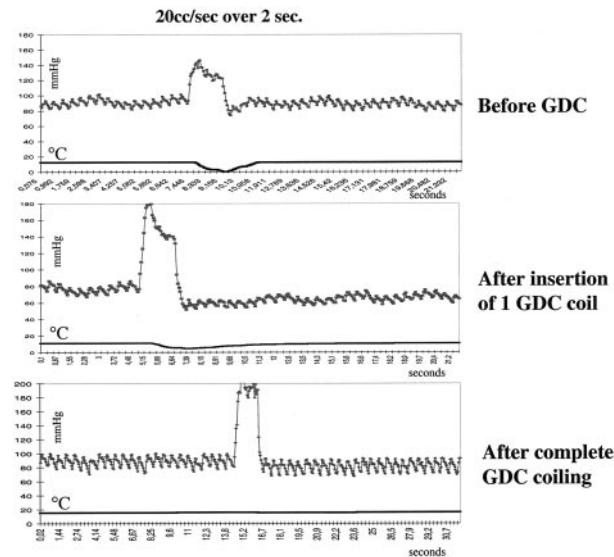


FIG 3. Pressure-thermodilution tracings of injections of 20 mL/s sodium chloride solution over 2 seconds in the dome of the aneurysm before, during, and after complete GDC placement. The thermodilution trace is markedly flattened; this finding corresponds to a cessation of local blood flow. Pressure is not attenuated. This result illustrates that insertion of only a single coil can dramatically change flow within the aneurysm. Further coil placement in this aneurysm completely interrupted flow in the aneurysm.

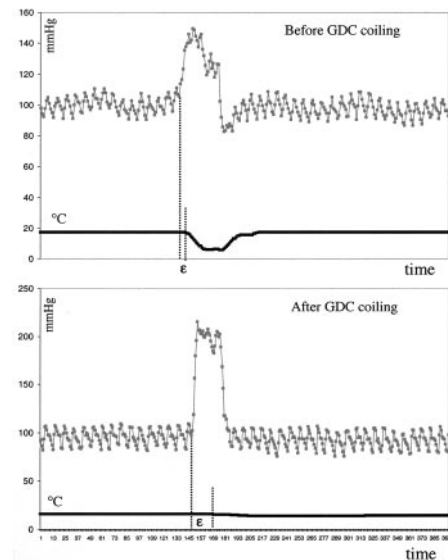


FIG 4. Pressure-thermodilution tracings of injections of 20 mL/s sodium chloride solution over 2 seconds in the dome of the aneurysm before and after complete GDC placement demonstrate the resulting dissociation of pressure and flow. Compare the interval between the injection and change in temperature before coil placement to that observed after coil placement.

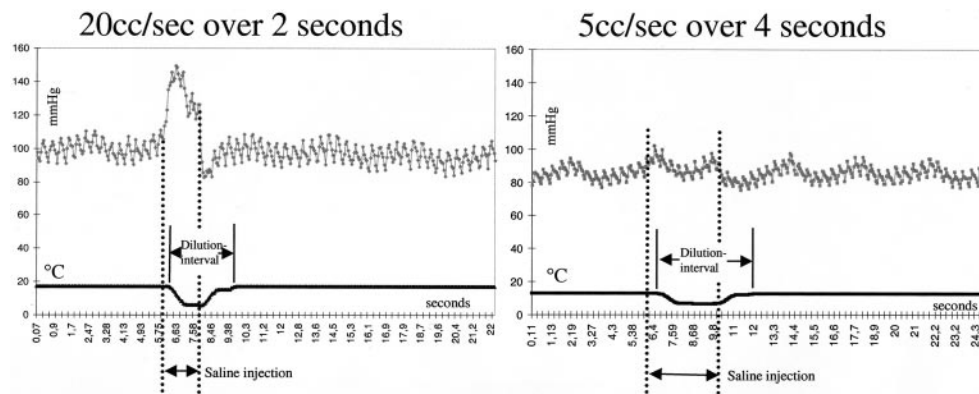


FIG 5. Pressure-thermodilution tracings of injections of sodium chloride solution over 2 seconds (20 mL/s) and 4 seconds (5 mL/s). Higher volumes create larger increases in pressure but similar decreases in temperature. The length of the dilution interval and pressure increase is dependent on the duration of injection. This finding illustrates the ability to assess flow by using only an injection of 5 mL/s.

## Erratum

In the article **The Middle Interhemispheric Variant of Holoprosencephaly**, Simon EM, Hevner RF, Pinter JD, Clegg NJ, Delgado M, Kinsman SL, Hahn JS, and Barkovich AJ, AJNR 23:151–155, January 2002, the following error occurred: In the “Results” paragraph of the abstract, the sentence “(2) The caudate nuclei were separated by the cerebral ventricles in 17 (89%) of the 17 patients . . .” should read “(2) The caudate nuclei were separated by the cerebral ventricles in 17 (89%) of the **19 patients** . . .” [emphasis added]; in the “Results” section of the abstract, sentence “(4) Three (18%) of the 16 patients in whom the mesencephalon . . .” should read “(4) Three (18%) of the **17 patients** . . .” [emphasis added].

## Erratum

In the article **Temporal Lobe Morphology in Normal Aging and Traumatic Brain Injury**, Bigler ED, Anderson CV, and Blatter DD; AJNR 23: 255–266, February 2002, an author’s name was misspelled as Carol V. Andersob. The correct name is Carol V. Anderson.