



**Get Clarity On Generics**

Cost-Effective CT & MRI Contrast Agents

**FRESENIUS  
KABI**

**WATCH VIDEO**

**AJNR**

This information is current as  
of August 12, 2025.

**Prospective Evaluation of the Brain in  
Asymptomatic Children with  
Neurofibromatosis Type 1: Relationship of  
Macrocephaly to T1 Relaxation Changes and  
Structural Brain Abnormalities**

R. Grant Steen, June S. Taylor, James W. Langston, John O.  
Glass, Vickie R. Brewer, Wilburn E. Reddick, Roy Mages  
and Eniko K. Pivnick

*AJNR Am J Neuroradiol* 2001, 22 (5) 810-817  
<http://www.ajnr.org/content/22/5/810>

# Prospective Evaluation of the Brain in Asymptomatic Children with Neurofibromatosis Type 1: Relationship of Macrocephaly to T1 Relaxation Changes and Structural Brain Abnormalities

R. Grant Steen, June S. Taylor, James W. Langston, John O. Glass, Vickie R. Brewer, Wilburn E. Reddick, Roy Mages, and Eniko K. Pivnick

**BACKGROUND AND PURPOSE:** Mutation of the neurofibromatosis type 1 (NF-1) gene may be associated with abnormal growth control in the brain. Because macrocephaly could be a sign of abnormal brain development and because 30% to 50% of children with NF-1 display macrocephaly in the absence of hydrocephalus, we sought to determine the relationship between macrocephaly and other brain abnormalities in young subjects with NF-1. These subjects were free of brain tumor, epilepsy, or other obvious neurologic problems.

**METHODS:** We prospectively screened 18 neurologically asymptomatic subjects with NF-1, ages 6 to 16 years, using clinical measures, psychometric testing, conventional MR imaging, and quantitative MR imaging to measure T1.

**RESULTS:** Cranial circumference was 2 or more SDs above the age norm in seven (39%) of 18 subjects, a frequency of macrocephaly 17-fold higher than normal. Conventional MR imaging showed abnormalities in all 18 children, although there were more extensive abnormalities in subjects with macrocephaly. Macrocephaly in NF-1 was associated with enlargement of multiple brain structures, and brain T1 in macrocephalic subjects was reduced with respect to controls in the genu, frontal white matter, caudate, putamen, thalamus, and cortex. In normocephalic subjects, T1 was reduced only in the genu and splenium. Volumetric analysis showed that macrocephaly was associated specifically with enlargement of white matter volume.

**CONCLUSION:** Neurologically asymptomatic children with NF-1 showed macrocephaly, cognitive deficit, enlarged brain structures, and abnormally low brain T1. Macrocephaly in children with NF-1 may be associated with characteristic alterations in brain development, marked by more widespread and significant changes in T1, greater enlargement of midline structures, and greater volume of white matter.

Neurofibromatosis type 1 (NF-1) is one of the most common autosomal dominant genetic disorders, with a rate of occurrence of about one in 3000 (1, 2). Because the protein product of the NF-1 gene, neurofibromin, has the potential to act as a tumor suppressor (3), and because patients with NF-1 are prone to a range of tumors (4, 5), it has been well

accepted that the NF-1 gene functions as a tumor suppressor. However, a role for the NF-1 gene has also been postulated in the regulation of cellular growth in the developing brain (6). Developmental regulation of a neuron-specific isoform of neurofibromin has been reported, and this isoform has been hypothesized to play a role in synaptogenesis

Received May 26, 2000; accepted after revision November 6.

Supported by a research grant from Neurofibromatosis Inc, Mass Bay Area, the National Cancer Institute through a Cancer Center Support (CORE) grant (P30-CA21765), and the American Lebanese Syrian Associated Charities (ALSAC).

Presented in part at the International Society for Magnetic Resonance in Medicine, May 1999, Philadelphia, PA.

From the Department of Diagnostic Imaging, St. Jude Children's Research Hospital, Memphis, TN (R.G.S., J.S.T.,

J.W.L., J.O.G., W.E.R., R.M.); the Departments of Pediatrics (R.G.S., V.R.B., E.K.P.), Radiology (R.G.S., J.S.T., J.W.L.), Biomedical Engineering (R.G.S.), and Ophthalmology (E.K.P.), University of Tennessee School of Medicine, Memphis; the Center for Pediatric Neuropsychology, LeBonheur Children's Medical Center, Memphis (V.R.B.); and the Departments of Psychology (V.R.B.), Biomedical Engineering (W.E.R.), and Electrical Engineering (W.E.R.), University of Memphis, TN.

Address reprint requests to June S. Taylor, PhD, Department of Diagnostic Imaging, St. Jude Children's Research Hospital, 332 N Lauderdale, Memphis, TN 38105.

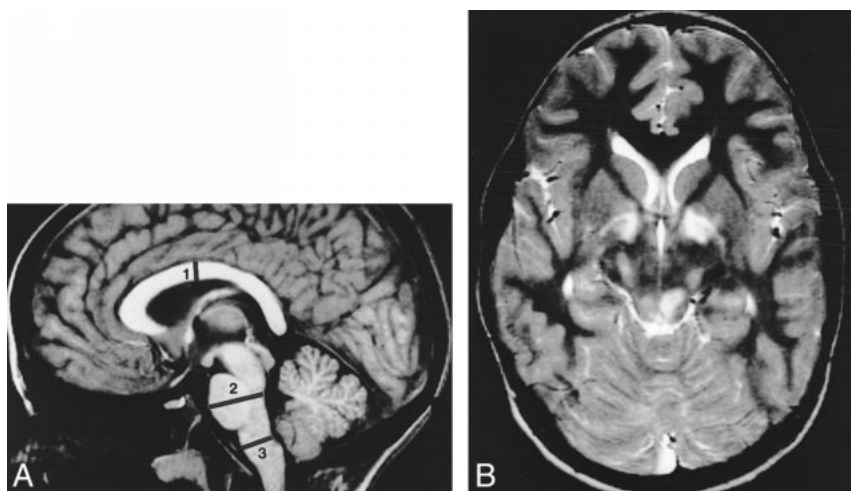


FIG 1. A, T1-weighted sagittal midline image (266/6/3) in an 11-year old boy with NF-1 and macrocephaly shows where the measurements of midline structures were made (see Table 2). This boy had thickening of the corpus callosum and enlargement of the anteroposterior diameter of the pons and medulla.

B, T2-weighted transverse image (3500/93/1) in an 8-year old girl shows bilateral lesions in the globus pallidus and tectum.

and neuronal differentiation (7). Thus, mutation of the NF-1 gene may be associated with abnormal growth control in the brain (8).

Abnormal brain development in NF-1 patients is suggested by the observation that 40% to 60% of children with NF-1 have a learning disability (5, 9–12). Abnormal brain development is also suggested by the finding that patients can have characteristic lesions, called regional signal hyperintensities (RSHs), which are visible by conventional MR imaging. Such lesions, which have also been called unidentified bright objects, or UBOs, are observed on T2-weighted MR imaging studies in 40% to 93% of children with NF-1 (5, 13–21). If the NF-1 gene is indeed involved in normal brain development, then one might expect CNS abnormalities even in NF-1 patients free of brain tumor.

Many studies have reported that children with NF-1 have a high rate of macrocephaly, without hydrocephaly (1, 4, 5). Published studies of children with NF-1 have not analyzed whether there is a relationship between macrocephaly and any other neuroimaging abnormality (8–10, 15, 21). Because macrocephaly in NF-1 could be a sign of abnormal brain development (1), we postulated that brain abnormality will be more common or more extensive among those NF-1 subjects with macrocephaly.

To avoid any ascertainment bias, we studied subjects with NF-1 who had no brain tumor, epilepsy, or other obvious neurologic problems. We used both conventional and quantitative MR imaging measures with the potential to detect developmentally related abnormalities. The T1 quantitative MR imaging method, which has been developed and extensively validated in our laboratory (22–27), measures spin-lattice relaxation time (T1) of brain tissue. Tissue T1 is a physical property of the water molecule, which has a strong effect on the ability to visualize brain structures by conventional MR imaging, and T1 may be sensitive to subtle structural changes below the sensitivity of current conventional MR methods (26, 27). Prior work in our laboratory has also shown that changes in T1 may

be associated with maturation of the normal human brain (24, 25).

Our hypothesis was that macrocephaly is associated with other subtle abnormalities of brain structure in neurologically asymptomatic subjects with NF-1. We report a study in which 18 asymptomatic children and adolescents with NF-1 were screened prospectively, using both conventional and quantitative MR imaging methods.

## Methods

### *Research Subjects and Controls*

The imaging protocol for research subjects who had NF-1 (hereinafter called “subjects”) and controls was reviewed and approved by the St. Jude Institutional Review Board. Parents or guardians of all children signed an informed consent after being given a detailed description of the protocol. Neither subjects nor controls received sedation, and no contrast injection was used in this study. Subjects under age 6 were not imaged because our IRB would not permit us to sedate healthy children for the study, and we believed that many young children would be unlikely to complete the imaging protocol.

Children with NF-1 were recruited to the study and were examined by a clinical geneticist, who directs the NF Clinic at the University of Tennessee at Memphis. Study enrollment required that subjects fulfill clinical criteria of the 1987 NIH Consensus Development Conference for NF-1 (28). To ensure that all subjects had sufficient visual acuity to perform well on psychometric tests, visual function was tested to verify that corrected visual acuity was better than 20/40, with no central scotomas or visual field defects present. Subjects with poor vision, or with a history of neurologic problems, such as epilepsy or other disorders, were excluded from the study. A total of 18 subjects were imaged. Ages ranged from 6.2 to 14.7 years; 78% were white, 22% were black, 67% were male, and 33% were female.

A total of 60 controls were imaged with quantitative MR imaging, all of whom were either the healthy siblings of St. Jude patients or the healthy children of hospital personnel. All controls were free of health problems by parental report, and many of the controls had participated in previous studies from our laboratory (24–27). Of these controls, nine were excluded from further study to obtain a better age match between controls and subjects; age match is important, as age is a major confounder in quantitative MR imaging studies (23–25). A total of 51 controls were fully analyzed. These children ranged

in age from 4.5 to 16.1 years; 53% were white, 47% were black, 53% were male, and 47% were female. There was no significant difference in mean age between subjects and controls ( $P = .973$ ).

#### *Cranial Measurements*

Direct measurement of occipitofrontal circumference was made by a single investigator using a tape measure. The measurement was recorded in centimeters, from a point above the glabella to a point near the top of the occipital bone, and values were compared with age- and sex-matched normative data (29). Children were judged macrocephalic if head circumference was 2 or more SDs above normal for age and sex.

#### *Psychometric Testing*

All subjects received psychometric screening with the Wechsler Intelligence Scale for Children-III (WISC-III), a standard test instrument (30). Subjects were tested by a state-licensed neuropsychologist, who had no knowledge of MR imaging findings. The primary outcome measures used were full-scale intelligence quotient (FSIQ), verbal IQ, and performance IQ.

#### *Conventional MR Imaging*

All MR imaging was performed on a 1.5-T Magnetom SP63 or Vision MR imager, using standard quadrature head coils. The conventional MR imaging examination included T1-weighted gradient-echo MR images acquired in the sagittal and transverse planes with parameters of 266/6/3 (TR/TE/excitations), 23-cm field of view, 90° flip angle, 192 × 256 matrix, and 19 slices with a 5-mm slice thickness. These images were used to select a slice for the quantitative MR imaging examination. In addition, T2- and proton density-weighted turbo spin-echo transverse images were acquired in a single sequence with parameters of 3500/19.93/1 (three echoes per TR for each effective TE), 23-cm field of view; 192 × 256 matrix, and 19 slices with a 5-mm slice thickness. The total acquisition time for the conventional MR images was about 9 minutes.

All films were reviewed by a neuroradiologist to screen for brain tumor. No subjects were excluded on this basis, and conventional MR imaging results are not reported in detail. However, the number of RSHs was tabulated, and it was noted whether lesions were in one hemisphere only (unilateral) or whether they were either on the midline or bilateral and roughly symmetrical.

#### *Morphometry from Conventional MR Images*

Macrocephaly in children with NF-1 has been associated with an increased volume of cerebral white matter (8). We prospectively measured the midsagittal diameter of the corpus callosum in our patients to determine whether this large white matter tract was enlarged in children with NF-1 and macrocephaly. Also, asymptomatic enlargement of the brain stem can occur in some patients with NF-1 and optic pathway glioma (32). This raised the question of whether brain stem enlargement occurred in children with NF-1 who are free of brain tumors. Therefore, we prospectively measured the midsagittal diameter of the pons and medulla to ascertain whether asymptomatic enlargement of these structures might be related to macrocephaly. The anteroposterior diameter of the pons and medulla was measured on films by the neuroradiologist, who used calipers and the scale bar printed on the films (Fig 1A). These measures were compared with normative values derived from 174 healthy subjects (33), and comparisons were made with age-similar controls. In addition, the thickness of the midbody of the corpus callosum was measured (34) and compared with published normative values from 150 healthy subjects

(35). We assumed that a callosal thickness that exceeds the adult mean by 2 SDs is abnormal.

#### *Quantitative MR Imaging*

Quantitative T1 imaging was done with a precise and accurate inversion-recovery (PAIR) method (22–27, 36). A single transverse slice through the basal ganglia was selected to show the same structures for all subjects and controls (22). This slice level was imaged with either a sign-sensitive PAIR sequence, which requires an imaging time of less than 14 minutes (22–27), or with a new turbo-PAIR sequence, which requires only 4 minutes. Results from the PAIR method and the turbo-PAIR method were comparable, as demonstrated by a study of 12 volunteers imaged with both methods (36). The new turbo-PAIR sequence was used to image three subjects and two controls in this study.

#### *Measurement of T1*

After acquisition, PAIR or turbo-PAIR images were transferred to an Indy work station (Silicon Graphics Inc., Mountain View, CA), for further analysis. Pixels identified as noise were excluded by statistical criteria (37) and T1 values for each remaining pixel were analyzed as previously described (37, 38). The T1 values were used to produce a parametric T1 map, wherein pixel gray scale value is equivalent to the relaxation time in milliseconds. The T1 of different anatomic structures was measured by identifying regions of interest (ROIs) on the TI = 500 base image, using criteria described in detail previously (22), and by then applying those ROIs to the parametric T1 map. Mean T1 was measured in ROIs manually placed in each of 10 different brain structures. During placement of the ROI, areas of abnormality seen by conventional MR imaging (eg, RSHs on T2-weighted sequences) were carefully avoided, since the question of interest was whether quantitative MR imaging could detect abnormality in brain areas that appeared normal by conventional MR imaging.

#### *Volumetry from Quantitative MR Images*

The quantitative MR images were further analyzed using a fully automated neural network algorithm (39) to segment and classify tissue as gray matter, white matter, CSF, partial volume of gray and white matter, partial volume of gray matter and CSF, or background (39–41). The segmentation algorithm used the four PAIR base images as input to a single-layer Kohonen self-organizing map, as described previously (40). After segmentation was completed, pixels in the segmented image were classified by a fully automated classification technique, and a pseudocolor image of the brain was created (40) to verify tissue classifications.

The segmented maps were then processed with a linear interpolation of relaxivity to eliminate partial volume regions by determining the proportion of gray matter, white matter, or CSF in each region (39). After all partial volumes were redistributed, the total volume of gray matter, white matter, and CSF was measured for each subject and control.

#### *Statistical Tests*

All statistical analyses relied on the SPSS 6.1 statistical package (SPSS Inc, Chicago, IL), running on a PowerCenter Pro 180 (Power Computing, Round Rock, TX). To minimize the potential repeated measures problem, only  $P$  values of .01 or less were considered significant.

## **Results**

#### *Cranial Measurements*

Of the 18 subjects in this study, seven (39%) had a cranial circumference 2 or more SDs above age-



**Table 1: Summary of WISC-III data in asymptomatic NF-1 subjects**

Comparison	Psychometric Test Scores				P Value (One-Tailed t-Test)
	Mean	±SD	Range	z Score	
Full-scale IQ	83.9	±15.6	65–129	−4.55	<.0001
Verbal IQ	86.9	±15.0	69–125	−3.61	.0002
Performance IQ	84.2	±17.5	62–129	−4.33	<.0001

Note.—Mean psychometric test scores (±SD) from the Wechsler Intelligence Scale in Children-III (WISC-III) for 18 neurologically asymptomatic children with NF-1. The full-scale IQ averages 15% lower than normative data for full-scale IQ, verbal IQ, and performance IQ, for which the mean and SD are  $100 \pm 15$ . The z score is the standardized deviate score, which normalizes the sample mean to a population mean, using the population SD. There was no significant difference in psychometric test scores between subjects with or without macrocephaly.

and sex-matched normative data (29), which defines a condition of macrocephaly. This rate of occurrence of macrocephaly was approximately 17-fold higher than expected in a population of well children ( $P < .001$ ). This finding is consistent with that reported in other studies of NF-1 patients (42, 43), and it cannot be explained by large body size. Furthermore, none of our subjects had hydrocephaly; in all cases, the brain appeared to be normal by conventional MR imaging, except for the presence of RSHs.

#### Psychometric Test Findings

The mean FSIQ among our subjects was 83.9 (Table 1), more than 16% lower ( $P < .0001$ ) than the normative data published with the WISC-III (30). About 11% (2/18) of the subjects were more than 2 SDs below the mean of normative data (FSIQ < 70), and another 50% (9/18) were 1 to 2 SDs below the mean of normative data. Overall, 89% of NF-1 subjects were below average in general aptitude (FSIQ), even though subjects were neurologically asymptomatic. Similarly, the verbal IQ and the performance IQ scores were significantly lower than normal ( $P < .0002$ ). No significant differences in neuropsychometric test scores were seen in comparing normocephalic with macrocephalic subjects.

#### Conventional MR Imaging Findings

Structural enlargements and RSHs were visualized by conventional MR imaging in every NF-1 patient, even though all subjects were free of obvious neurologic symptoms or brain tumor (Fig 1). Structural enlargements were present in 39% (7/18) of subjects and every subject had at least two RSHs. Findings are summarized, with macrocephalic subjects separated from normocephalic subjects, in Table 2. Subjects with enlargement of one structure tended to show enlargement of multiple

**Table 2: Summary of findings from conventional MR imaging**

Comparison	Normocephalic (n = 11)	Macrocephalic (n = 7)
Bilateral or midline lesions	30	28
Unilateral lesions	16	2
No. of enlarged midline structures*	3	12

Note.—Summary of lesions (regional signal hyperintensities) and enlarged brain structures observed by conventional MR examination of 18 NF-1 subjects. Bilateral lesions were significantly more common in macrocephalic subjects than normocephalic subjects, according to a  $2 \times 2 \chi^2$  analysis of these data ( $\chi^2 = 6.46$ ;  $P < .02$ ). Macrocephalic subjects were also significantly more likely to have multiple brain structures enlarged with respect to normal ( $\chi^2 = 12.47$ ;  $P < .001$ ).

\* A total of three midline structures (corpus callosum, pons, medulla) were evaluated per subject.

brain structures and tended to have more RSHs (data not shown).

The most common finding for all children with NF-1 was a variable number of bilateral or midline lesions (Fig 1B); in all, 58 such lesions were seen among 18 subjects (Table 2). Unilateral lesions were less common than bilateral or midline lesions, as only 18 such lesions were seen. Lesions did not exert a noticeable mass effect, had no surrounding edema, and occurred most commonly in the basal ganglia and optic pathways.

Bilateral lesions appear to be a hallmark of NF-1, as 94% of our subjects had them (Fig 1B). Overall, 91% (10/11) of normocephalic subjects had bilateral lesions, whereas 100% of macrocephalic subjects had bilateral lesions. By contrast, unilateral lesions were seen almost exclusively in normocephalic subjects. Overall, 73% (8/11) of normocephalic subjects had unilateral lesions, whereas only 14% (1/7) of macrocephalic subjects had unilateral lesions. A  $2 \times 2 \chi^2$  analysis based on the distribution of lesions (Table 2) showed that macrocephalic subjects were less likely than normocephalic subjects to have unilateral lesions ( $\chi^2 = 6.46$ ;  $P < .02$ ).

#### Morphometry from Conventional MR Images

The anteroposterior distance in the pons and/or medulla was abnormally large in 71% (5/7) of macrocephalic subjects, as compared with published normative data (33). The midbody of the corpus callosum was abnormally thick in 43% (3/7) of macrocephalic subjects, compared with normative data (35). By contrast, only 18% (2/11) of normocephalic subjects had an enlarged pons or medulla, and none had an enlarged corpus callosum. Overall, macrocephalic subjects were significantly more likely than normocephalic subjects to have enlargement of midline structures ( $\chi^2 = 12.47$ ;  $P < .001$ ).

#### Quantitative MR Imaging Findings

Measurements of the T1 relaxation time of brain parenchyma were made in 10 brain regions, in all

**Table 3: Mean T1 values in healthy controls and in all NF-1 subjects combined, or in NF-1 subjects with normocephaly or macrocephaly.**

Comparison		Healthy Controls (n = 51)	NF-1 Subjects			<i>P</i> Value ( <i>t</i> -Test) for Controls × All NF-1 Subjects
			All NF-1 (n = 18)	Normocephalic (n = 11)	Macrocephalic (n = 7)	
Age (yr)	Mean	10.3	10.3	10.1	10.6	NS
	SD	3.1	2.5	2.9	1.7	
White Matter Structures						
Genu T1 (msec)	Mean	625	592	597*	584*	<.001
	SD	31	27	31	17	
Splenium T1 (msec)	Mean	651	601	596*	613	.002
	SD	47	42	45	39	
Frontal T1 (msec)	Mean	658	647	657	631*	NS
	SD	27	26	26	19	
Optic rad. T1 (msec)	Mean	669	649	653	643	NS
	SD	31	28	30	26	
Occipital T1 (msec)	Mean	661	649	652	644	NS
	SD	22	28	31	26	
Gray Matter Structures						
Caudate T1 (msec)	Mean	1097	1059	1071	1039*	.005
	SD	49	45	42	46	
Putamen T1 (msec)	Mean	964	934	962	895*	NS
	SD	64	71	48	83	
Thalamus T1 (msec)	Mean	889	860	867	849*	.001
	SD	33	26	26	25	
Nucleus T1 (msec)	Mean	968	959	957	962	NS
	SD	49	29	23	38	
Cortical gray T1 (msec)	Mean	1196	1148	1155	1137*	.004
	SD	55	71	68	80	

Note.—In 10 of 10 comparisons, subjects with NF-1 had lower T1 than age-similar controls ( $1/2^{10}$ ;  $P < .001$ ).

\* All statistical comparisons were done with an independent-samples *t*-test ( $P \leq .01$  for comparison of normo- and macrocephalic NF-1 subjects versus controls).

18 subjects and in 51 controls (Table 3). In every tissue evaluated, average T1 of subjects was lower than average T1 of controls (odds are  $1/2^{10}$ ;  $P < .001$ ). Overall, patient T1 was significantly lower than control T1 in the genu ( $P < .001$ ), splenium ( $P < .002$ ), caudate ( $P < .005$ ), anterior thalamus ( $P < .001$ ), and cortical gray matter ( $P < .004$ ). There was a significant relationship between T1 and psychometric findings among NF-1 subjects (Fig 2). The T1 in the nucleus pulvinaris was correlated with FSIQ ( $r = .58$ ;  $P = .01$  by ANOVA) and with performance IQ ( $r = .59$ ;  $P = .01$  by ANOVA).

The T1 values for normocephalic and macrocephalic subjects were compared separately with control values using a *t*-test statistic (Table 3). Among subjects with normocephaly, T1 was significantly lower only in the genu and splenium. By contrast, among subjects with macrocephaly, T1 was significantly lower in the genu, frontal white matter, caudate, putamen, thalamus, and cortex. Finally, T1 values for subjects with any abnormal enlargement of the brain (Table 2) were compared with T1 values of subjects without such enlargement. Subjects with any enlarged brain structure had significantly lower T1 in the frontal white matter ( $P < .005$ ) and caudate ( $P < .001$ ).

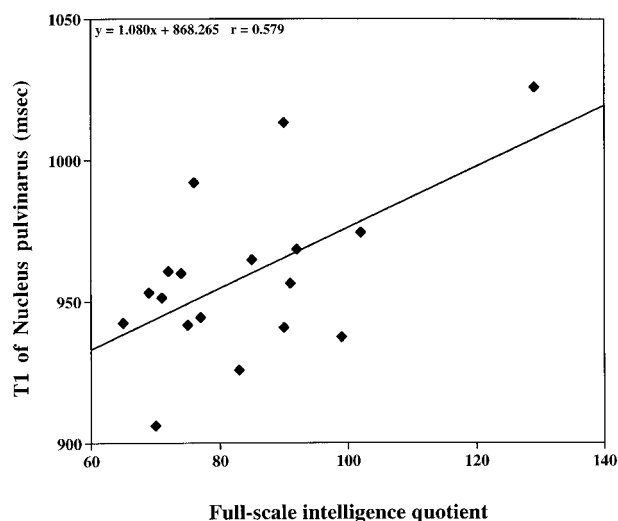


FIG 2. Scatterplot of quantitative tissue T1 in the nucleus pulvinaris versus FSIQ in children with NF-1 ( $r = .58$ ;  $P = .012$  by ANOVA).

#### Volumetry from Quantitative MR Images

Findings from an analysis of the volume of white and gray matter in the segmented T1 map are summarized in Table 4. While these measurements are based on a single slice, prior work has shown that

**Table 4: Brain volume in asymptomatic NF-1 patients and controls**

Comparison		Healthy Controls (n = 46)	NF-1 Subjects			P Value (t-Test)		
			All NF-1 (n = 18)	Normocephalic (n = 11)	Macrocephalic (n = 7)	1 × 2	1 × 3	1 × 4
Age (yr)	Mean	10.1	10.3	10.1	10.6	NS	NS	NS
	SD	2.9	2.5	2.9	1.7			
Intracranial volume (cm <sup>3</sup> )	Mean	82.8	87.8	84.6	92.9	.001	NS	<.001
	SD	4.3	7.1	5.8	6.2			
Brain volume (cm <sup>3</sup> )	Mean	75.4	79.9	77.1	84.2	.001	NS	<.001
	SD	4.0	6.3	4.8	6.0			
White matter (cm <sup>3</sup> )	Mean	25.7	27.9	25.7	31.3	NS	NS	.001
	SD	4.0	4.9	4.3	3.8			
Gray matter (cm <sup>3</sup> )	Mean	49.7	52.0	51.4	52.9	NS	NS	NS
	SD	4.4	4.6	4.4	5.1			
Ventricles (cm <sup>3</sup> )	Mean	7.1	6.1	5.8	6.5	NS	NS	NS
	SD	2.5	3.1	3.3	2.9			

Note.—Comparison of (single-slice) brain volume in healthy controls and in all NF-1 subjects, or in NF-1 subjects with normocephaly or macrocephaly. Brain volume is simply the sum of white matter volume and gray matter volume, with the ventricular volume excluded.

the volume of white and gray matter in this slice is representative of the volume of white and gray matter throughout the brain (39). In subjects, both the volume of the cranium and the volume of the brain were significantly larger than that in controls (for both,  $P < .001$ ). When subjects were partitioned into those with normocephaly (group 3) versus those with macrocephaly (group 4), it became apparent that only macrocephalic subjects were significantly different from controls.

Macrocephaly was associated with a significant increase in both cranial volume and brain volume (for both,  $P < .001$ ), whereas brain volume in normocephalic subjects did not differ from that in controls (Table 4). Macrocephaly specifically was associated with enlargement of white matter volume, as macrocephalic subjects showed a 22% increase in white matter volume ( $P < .001$ ), with no significant change in gray matter or ventricular volume. There was also a trend for gray matter volume to be greater in macrocephalics than in controls.

### Discussion

Children and adults with NF-1 often show relative macrocephaly. This macrocephaly might be an indication of a global abnormality in brain development. However, macrocephaly also occurs in healthy individuals in the absence of any brain or cognitive abnormalities. To our knowledge, there is no previous report of an association between this macrocephaly and underlying structural abnormalities.

We sought to determine whether structural brain abnormality is associated with macrocephaly in neurologically asymptomatic children with NF-1. Part of our impetus was the RSHs that have been noted in NF-1 patients (5, 12–17, 19–27, 44). Such lesions are thought to represent either developmental dysregulation that is global in nature (7, 8, 12) or a more focal process, such as low-grade neoplasm, hamartoma, or heterotopia (14, 15). We rea-

soned that if RSHs are a sign of global dysregulation of brain development, then there might be diffuse abnormality elsewhere in the brain. By contrast, if RSHs are a focal process, one would not expect to see diffuse brain abnormalities. We therefore tested a hypothesis that NF-1 is associated with diffuse abnormality in apparently normal brain. The null hypothesis was that abnormality would be limited to the RSHs.

Our results show that subtle and diffuse abnormalities are present throughout the brain in children with NF-1 who are lacking in neurologic symptoms. These abnormalities can include enlargement of some midline brain structures, multiple RSHs, and abnormally low T1. Using conventional MR imaging, we observed RSHs or other abnormalities in every subject, suggesting that abnormal development of the brain may be more common than previously thought in NF-1. These asymptomatic subjects with NF-1 also showed striking cognitive deficits unrelated to the presence of tumor. The FSIQ we report ( $83.9 \pm 15.6$ ) is 16% less than normal ( $P < .0001$ ), but consistent with FSIQ decrements reported for other children with NF-1 who were free of tumor or other abnormalities (42). Our findings confirm that cognitive deficits noted in NF-1 patients cannot always be attributed to brain tumor (10, 45).

Macrocephaly, defined as a head size 2 or more SDs above an age- and sex-matched mean, is present in up to 50% of children with NF-1 (4, 5, 43, 46, 47). We found that macrocephaly results from megencephaly, defined as enlargement of brain tissue. Volumetric analysis of the T1 map slice suggests that macrocephalics show enlargement of white matter volume specifically, consistent with hypertrophy or hyperplasia of myelinated tracts. White matter volume in the corpus callosum was also increased, and the size of the brain stem was large for patient age. Enlargement of midline structures was predominantly, but not exclusively, present in those subjects with macrocephaly.

Two prior studies have applied quantitative morphometric analysis of MR images to populations of children with NF-1, and both reported an increased volume of brain tissue. The earlier study (8) reported a significant increase (20% to 50%) in white matter volume, with a much smaller gray matter increase (3% to 8%). The more recent study (21), which evaluated the cerebellum as well as the cerebrum, found no significant difference in white matter volume, but reported an increased gray matter volume. The later study also reported an increase in cross-sectional area at the mid-body of the corpus callosum. However, 31% of the children in this study (21) had prior treatment for brain tumor (surgery and/or chemotherapy), so this patient population is quite different from the earlier study (8) or the present study. It is also unclear whether the segmentation algorithm used may have classified RSHs as gray matter (21). Neither prior study addressed the relationship between macrocephaly and volumetric enlargement.

Although there are major methodologic differences between our study and these earlier investigations (8, 21), there are also important points of agreement. None of the studies reported an association between white matter volume change and neuropsychometric measures (8, 21), and all the studies found a correlation between gray matter properties and neuropsychometric measures (8, 21). For example, a relationship was reported between right hemisphere gray matter volume and visuospatial function (8), and greater gray matter volume was associated with a greater degree of learning disability in NF-1 (21). We found a correlation between FSIQ and quantitative T1 in the nucleus pulvinus ( $P = .01$ ). It is noteworthy that learning disability in children with NF-1 has previously been linked to abnormalities in the thalamus (9).

Our findings are consistent with the conclusion that macrocephaly in NF-1 may be associated with abnormal development of both white and gray matter in the brain. Evidence consistent with dysplasia of white matter is clear-cut, because macrocephaly is associated with expansion of white matter tracts, possibly due to hypertrophy or hyperplasia, as well as with T1 reduction in the genu and frontal white matter. Evidence consistent with dysplasia of gray matter is perhaps not as clear-cut, but macrocephalic NF-1 subjects showed a significant reduction of T1 in four of five gray matter structures, whereas normocephalic NF-1 subjects did not show a reduction of T1 in any gray matter structure (Table 3). The reduction in cortical T1 that we report may mean that there is dysplasia of those myelinated fibers that traverse gray matter. Because myelinated tissue has a T1 that is roughly half that of unmyelinated tissue (23), dysplastic myelination of gray matter could cause a substantial shortening of T1 with respect to normal. The finding that macrocephalic patients have proportionally more bilateral lesions than normocephalic patients also suggests that macrocephalics show a pervasive disturbance

of brain development. Therefore, we hypothesize that dysplastic myelination of white matter tracts is present throughout the brain in macrocephalic children with NF. Our results thus suggest that a simple measurement of head circumference may be an adequate clinical marker of abnormal brain development in this subset of children with NF-1.

It may be noteworthy that we report large differences from normal in the T1 of cortical gray matter, thalamus, and caudate of subjects (Table 3). In a recent investigation of children with NF-1 (48), the cortex and the head of the caudate were shown to have an abnormally low metabolic rate on positron emission tomography studies used to measure uptake of  $^{18}\text{F}$ -fluorodeoxyglucose (FDG). The metabolic rate of the thalamus was 36% lower in patients than in healthy controls ( $P < .00003$ ) and FDG uptake in the cortex was also generally lower than normal (48). Other researchers, using MR spectroscopy to characterize gray matter in children with NF-1 (49), reported that patients had significantly less *N*-acetylaspartate (NAA) in the thalamus and significantly less creatine in the occipital gray matter than did healthy controls (49). It may be particularly noteworthy that we also report a relationship between thalamic abnormality and cognitive impairment (Fig 2).

Our results are further consistent with the conclusion that enlargement of cerebral white matter tracts and midline structures is characteristic of NF-1 children with macrocephaly. For macrocephalic children with NF-1, abnormalities in T1 were observed in gray matter regions that were apparently normal on conventional MR images. These subtle abnormalities of gray matter are worthy of further exploration.

### Acknowledgments

We are indebted to the NF-1 subjects and their families for their cooperation in this research, and we gratefully acknowledge the help of Natalie Kerr, MD, who performed the ophthalmologic testing, and Marcella Lawrence, RN, MSN, who helped coordinate the patient studies. We also thank the families of St. Jude Children's Research Hospital, who contributed their time and effort to help us obtain control data.

### References

1. Riccardi VM. *Neurofibromatosis: Phenotype, Natural History, and Pathogenesis*, 2nd ed. Baltimore: Johns Hopkins University Press; 1992
2. Gutmann DH. Recent insights into neurofibromatosis type 1: clear genetic progress. *Arch Neurol* 1998;55:778-780
3. Basu TN, Gutmann DH, Fletcher JA, Glover TW, Collins FS, Downward J. Aberrant regulation of ras proteins in malignant tumour cells from type 1 neurofibromatosis patients. *Nature* 1992;356:713-715
4. Friedman JM, Birch PH. Type 1 neurofibromatosis: a descriptive analysis of the disorder in 1,728 patients. *Am J Med Genet* 1997;70:138-143
5. Van Es S, North KN, McHugh K, Silva MD. MRI findings in children with neurofibromatosis type 1: a prospective study. *Pediatr Radiol* 1996;26:478-487
6. Giordano MJ, Mahadeo DK, He YY, Geist RT, Hsu C, Gutmann DH. Increased expression of the neurofibromatosis 1 (NF1)



- gene product, neurofibromin, in astrocytes in response to cerebral ischemia. *J Neurosci Res* 1996;43:246–253
7. Gutmann DH, Zhang Y, Hirbe A. Developmental dysregulation of a neuron-specific neurofibromatosis 1 isoform. *Ann Neurol* 1999;46:777–782
  8. Said SM, Yeh TL, Greenwood RS, Whitt JK, Tupler LA, Krishnan KR. MRI morphometric analysis and neuropsychological function in patients with neurofibromatosis. *Neuroreport* 1996;7:1941–1944
  9. Moore BD, Slopis JM, Schomer D, Jackson EF, Levy BM. Neuropsychological significance of areas of high signal intensity on brain MRIs of children with neurofibromatosis. *Neurology* 1996;46:1660–1668
  10. Denckla MB, Hofman K, Mazzocco MM, et al. Relationship between T2-weighted hyperintensities (unidentified bright objects) and lower IQs in children with neurofibromatosis-1. *Am J Med Genet* 1996;67:98–102
  11. Ferner RE, Hughes RA, Weinman J. Intellectual impairment in neurofibromatosis 1. *J Neurol Sci* 1996;138:125–133
  12. North K, Joy P, Yuille D, et al. Specific learning disability in children with neurofibromatosis type 1: significance of MRI abnormalities. *Neurology* 1994;44:878–883
  13. Duffner PK, Cohen ME, Seidel FG, Shucard DW. The significance of MRI abnormalities in children with neurofibromatosis. *Neurology* 1989;39:373–378
  14. Aoki S, Barkovich AJ, Nishimura K, et al. Neurofibromatosis types 1 and 2: cranial MR findings. *Radiology* 1989;172:527–534
  15. Sevick RJ, Barkovich AJ, Edwards MS, Koch T, Berg B, Lempert T. Evolution of white matter lesions in neurofibromatosis type 1: MR findings. *AJR Am J Roentgenol* 1992;159:171–175
  16. Ferner RE, Chaudhuri R, Bingham J, Cox T, Hughes RA. MRI in neurofibromatosis 1: the nature and evolution of increased intensity T2 weighted lesions and their relationship to intellectual impairment. *J Neurol Neurosurg Psychiatry* 1993;56:492–495
  17. Itoh T, Magnaldi S, White RM, et al. Neurofibromatosis type 1: the evolution of deep gray and white matter MR abnormalities. *AJNR Am J Neuroradiol* 1994;15:1513–1519
  18. Parazzini C, Triulzi F, Bianchini E, et al. Spontaneous involution of optic pathway lesions in neurofibromatosis type 1: serial contrast MR evaluation. *AJNR Am J Neuroradiol* 1995;16:1711–1718
  19. Terada H, Barkovich AJ, Edwards MS, Ciricillo SM. Evolution of high-intensity basal ganglia lesions on T1-weighted MR in neurofibromatosis type 1. *AJNR Am J Neuroradiol* 1996;17:755–760
  20. DiMario FJ Jr, Ramsby G. Magnetic resonance imaging lesion analysis in neurofibromatosis type 1. *Arch Neurol* 1998;55:500–505
  21. Moore BD, Slopis JM, Jackson EF, De Winter AE, Leeds NE. Brain volume in children with neurofibromatosis type 1: relation to neuropsychological status. *Neurology* 2000;54:914–920
  22. Steen RG, Gronemeyer SA, Kingsley PB, Reddick WE, Langston JW, Taylor JS. Precise and accurate measurement of proton T1 in human brain in vivo: validation and preliminary clinical application. *J Magn Reson Imaging* 1994;4:681–691
  23. Steen RG, Gronemeyer SA, Taylor JS. Age-related changes in proton T1 values of normal human brain. *J Magn Reson Imaging* 1995;5:43–48
  24. Steen RG, Ogg RJ, Reddick WE, Kingsley PB. Age-related changes in the pediatric brain: quantitative MR evidence of maturational changes during adolescence. *AJNR Am J Neuroradiol* 1997;18:819–828
  25. Cho S, Jones D, Reddick WE, Ogg RJ, Steen RG. Establishing norms for age-related changes in proton T1 of human brain tissue in vivo. *Magn Reson Imaging* 1997;15:1133–1143
  26. Steen RG, Reddick WE, Mulhern RK, et al. Quantitative MRI of the brain in children with sickle cell disease reveals abnormalities unseen by conventional MRI. *J Magn Reson Imaging* 1998;8:535–543
  27. Steen RG, Xiong X, Mulhern RK, Langston JW, Wang WC. Subtle brain abnormalities in children with sickle cell disease: relationship to blood hematocrit. *Ann Neurol* 1999;45:279–286
  28. National Institutes of Health Consensus Development Conference. Neurofibromatosis: conference statement. *Arch Neurol* 1988;45:575–578
  29. Jones KL. *Recognizable Patterns of Human Malformation*. 5th ed. Philadelphia: Saunders; 1997
  30. Wechsler D. *Wechsler Intelligence Scale for Children*. 3rd ed. San Antonio, TX: The Psychological Corp; 1991
  31. Cawthon RM, Weiss R, Xu GF, et al. A major segment of the neurofibromatosis type 1 gene: cDNA sequence, genomic structure, and point mutations. *Cell* 1990;62:193–201
  32. Broniscer A, Gajjar A, Bhargava R, et al. Brain stem involvement in children with neurofibromatosis type 1: role of magnetic resonance imaging and spectroscopy in the distinction from diffuse pontine glioma. *Neurosurgery* 1997;40:331–337
  33. Raininko R, Autti T, Vanhanen SL, Ylikoski A, Erkinjuntti T, Santavuori P. The normal brain stem from infancy to old age: a morphometric MRI study. *Neuroradiology* 1994;36:364–368
  34. Rakic P, Yakovlev PI. Development of the corpus callosum and cavum septi in man. *J Comp Neurol* 1968;132:45–72
  35. Hayakawa K, Konishi Y, Matsuda T, et al. Development and aging of brain midline structures: assessment with MR imaging. *Radiology* 1989;172:171–177
  36. Steen RG, Reddick WE, Ogg RJ. More than meets the eye: significant regional heterogeneity in human cortical T1. *Magn Reson Imaging* 2000;18:361–368
  37. Reddick WE, Ogg RJ, Steen RG, Taylor JS. Statistical error mapping for reliable quantitative T1 imaging. *J Magn Reson Imaging* 1996;6:244–249
  38. Kingsley PB, Ogg RJ, Reddick WE, Steen RG. Correction of errors caused by imperfect inversion pulses in MR imaging measurement of T1 relaxation times. *Magn Reson Imaging* 1998;16:1049–1055
  39. Glass JO, Reddick WE, Goloubeva O, Yo V, Steen RG. Hybrid artificial neural network segmentation of precise and accurate inversion recovery (PAIR) images from normal brain. *Magn Reson Imaging* 2000;18:1245–1253
  40. Reddick WE, Glass JO, Cook EN, Elkin TD, Deaton RJ. Automated segmentation and classification of multispectral magnetic resonance images of brain using artificial neural networks. *IEEE Trans Med Imaging* 1997;16:911–918
  41. Reddick WE, Mulhern RK, Elkin TD, Glass JO, Merchant TE, Langston JW. A hybrid neural network analysis of subtle brain volume differences in children surviving brain tumors. *Magn Reson Imaging* 1998;16:413–421
  42. Ozonoff S. Cognitive impairment in neurofibromatosis type 1. *Am J Med Genet* 1999;89:45–52
  43. Huson SM, Harper PS, Compston DA. Von Recklinghausen neurofibromatosis: a clinical and population study in south-east Wales. *Brain* 1988;111:1355–1381
  44. Griffiths PD, Blaser S, Mukonoweshuro W, Armstrong D, Milomason G, Cheung S. Neurofibromatosis bright objects in children with neurofibromatosis type 1: a proliferative potential? *Pediatrics* 1999;104:e49
  45. Eldridge R, Denckla MB, Bien E, et al. Neurofibromatosis type 1 (Recklinghausen's disease): neurologic and cognitive assessment with sibling controls. *Am J Dis Child* 1989;143:833–837
  46. Cnossen MH, Moons KG, Garssen MP, et al. Minor disease features in neurofibromatosis type 1 (NF1) and their possible value in diagnosis of NF1 in children < or = 6 years and clinically suspected of having NF1. *J Med Genet* 1998;35:624–627
  47. Zvulunov A, Weitz R, Metzker A. Neurofibromatosis type 1 in childhood: evaluation of clinical and epidemiologic features as predictive factors for severity. *Clin Pediatr* 1998;37:295–299
  48. Kaplan AM, Chen K, Lawson MA, Wodrich DL, Bonstelle CT, Reiman EM. Positron emission tomography in children with neurofibromatosis-1. *J Child Neurol* 1997;12:499–506
  49. Wang PY, Kaufmann WE, Koth CW, Denckla MB, Barker PB. Thalamic involvement in neurofibromatosis type 1: evaluation with proton magnetic resonance spectroscopic imaging. *Ann Neurol* 2000;47:477–484