



**Providing Choice & Value**  
Generic CT and MRI Contrast Agents

**FRESENIUS  
KABI**

**CONTACT REP**

**AJNR**

## **Abciximab Rescue in Acute Carotid Stent Thrombosis**

Frank C. Tong, Harry J. Cloft, Gregory J. Joseph, Owen B. Samuels and Jacques E. Dion

*AJNR Am J Neuroradiol* 2000, 21 (9) 1750-1752

<http://www.ajnr.org/content/21/9/1750>

This information is current as  
of July 21, 2025.

## Case Report

# Abciximab Rescue in Acute Carotid Stent Thrombosis

Frank C. Tong, Harry J. Cloft, Gregory J. Joseph, Owen B. Samuels, and Jacques E. Dion

**Summary:** Occlusion of an internal carotid artery stent was identified immediately post placement in a patient who had restenosis after prior angioplasty. An IV dose of abciximab was administered, and serial angiograms were performed. This resulted in partial resolution of the thrombus at 10 minutes and complete resolution at 20 minutes.

Acute thrombosis is a potential complication of arterial angioplasty and stent placement. Abciximab (Reopro, Centocor, Malvern, PA) is a potent antiplatelet drug that is Food and Drug Administration–approved as an adjunctive therapy to prevent thromboembolic complications in patients undergoing percutaneous coronary artery intervention. This is accomplished by drug binding to the IIb/IIIa surface-membrane glycoprotein platelet receptor, which prevents platelet crosslinking and aggregation (1). We describe a case in which abciximab was used as a thrombolytic agent in the setting of acute carotid stent thrombosis.

## Case Report

A 44-year-old man presented initially with left transient monocular blindness. Arteriography demonstrated 70% focal stenosis of the left internal carotid artery (ICA) at the C2 level, and total occlusion of the right ICA and right vertebral artery. He underwent angioplasty of the left ICA stenosis. The lesion was successfully dilated with a 3.5-mm angioplasty balloon, without complication or significant residual stenosis. The patient was asymptomatic at discharge and was followed up with serial carotid sonography. Follow-up two-dimensional time-of-flight MR angiography (MRA) performed 14 months later showed diminished flow in the distal left cervical ICA, consistent with recurrent high-grade stenosis. MR imaging performed at that time revealed no signal abnormality within the brain. Carotid angiography confirmed the MRA findings of recurrent high-grade left ICA stenosis, with supply of nearly the entire anterior intracranial circulation through large bilateral posterior communicating arteries. The left ICA stenosis had a very focal appearance not typical of atherosclerotic disease, possibly representing a site of previous dissection (Fig 1A).

Because the right ICA and right vertebral arteries were occluded, and the left ICA stenosis had been previously symp-

tomatic, we elected to perform angioplasty with stent placement. Ten thousand U of IV heparin was administered after placement of a vascular access sheath and a guide catheter. A 0.035-in hydrophilic guidewire was placed across the left ICA stenosis, and a 4-mm × 2-cm angioplasty balloon was then advanced across the lesion and inflated. Angiography obtained through the guiding catheter showed elimination of the previously seen high-grade stenosis. The angioplasty balloon was then removed and a 8 × 23-mm Symphony stent (Boston Scientific, Natick, MA) was placed over the 0.035-in hydrophilic guidewire across the dilated segment. The stent was successfully deployed, with no residual stenosis, as verified on angiography through the guiding catheter (Fig 1B). The stent deployment device was then withdrawn, and follow-up angiography was performed through the guiding catheter, which showed complete occlusion of the left ICA (Fig 1C). Because there was no evidence of vasospasm on the initial or immediate poststent images, the carotid occlusion was thought to represent acute thrombosis.

The patient's activated clotting time (ACT) was 198 seconds and 5000 U of IV heparin was administered immediately, which increased the ACT to 282 seconds. In a rescue attempt to dissolve the intraluminal thrombus, an IV bolus of 0.25 mg/kg of abciximab was administered, followed by a maintenance infusion of 10 mcg/minute. Angiography performed 10 minutes after the abciximab bolus showed partial recanalization of the left ICA thrombus. Subsequent angiography performed 20 minutes after abciximab bolus administration showed complete recanalization of the left ICA (Fig 1D). There was no evidence of distal embolism on the intracranial angiograms, and the patient remained asymptomatic throughout the procedure.

The patient was maintained on the abciximab infusion for 12 hours and remained asymptomatic. Repeat angiography the next morning showed patency of the stented left ICA, without evidence of residual or recurrent thrombus. The patient remained asymptomatic and was discharged 48 hours after angioplasty and placed on aspirin and clopidogrel.

## Discussion

We describe a case in which stenting of the extracranial ICA was complicated by acute thrombosis. Because acute thrombus is known to be platelet-rich, we elected to administer a platelet glycoprotein IIb/IIIa antagonist as a rescue attempt to dissolve the clot. After IV abciximab treatment, there was resolution of the clot over a 20-minute period. The potential mechanisms of this thrombolytic effect include active platelet deaggregation at the site of thrombus, endogenous autothrombolysis, and inhibition of platelet-rich thrombus propagation.

Acute/subacute stent thrombosis remains a major concern for carotid stent implantation, occurring in 0.5% to 2% of cases (2, 3). By comparison, recent cardiology literature indicates that acute/subacute stent thrombosis occurs in 0.6% to 16.7% (4, 5) of

Received July 13, 1999; accepted after revision March 20, 2000.

From the Departments of Radiology (F.C.T., H.J.C., G.J.J., J.E.D.) and Neurosurgery (H.J.C., G.J.J., O.B.S., J.E.D.), Emory University, Atlanta.

Address reprint requests to Frank C. Tong, MD, Department of Radiology, Emory University, 1364 Clifton Rd. N.E., Atlanta, GA 30322.

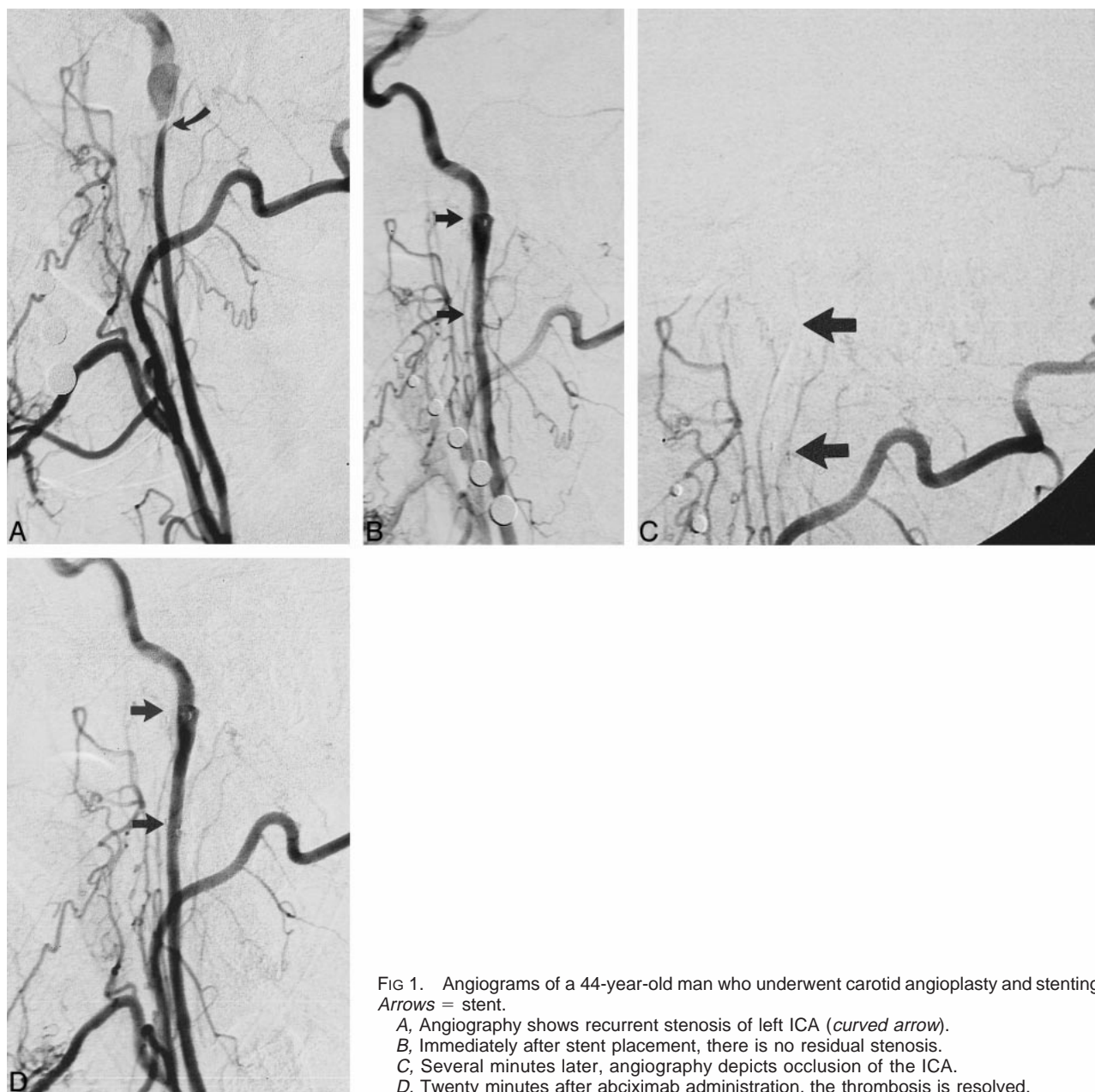


FIG 1. Angiograms of a 44-year-old man who underwent carotid angioplasty and stenting. Arrows = stent.

A, Angiography shows recurrent stenosis of left ICA (*curved arrow*).

B, Immediately after stent placement, there is no residual stenosis.

C, Several minutes later, angiography depicts occlusion of the ICA.

D, Twenty minutes after abciximab administration, the thrombosis is resolved.

coronary stenting procedures despite concomitant heparin and aspirin therapy. Animal studies evaluating acute stent thrombosis have demonstrated that platelet activation is the primary mediator in acute stent thrombosis (6). A canine *ex vivo* model has shown significant reduction of stent thrombosis when platelets are inactivated with platelet receptor antagonist 7E3 directed against the glycoprotein IIb/IIIa receptor (7). Patients with glycoprotein receptor IIb/IIIa inactivation from receptor antagonist 7E3 have 35% less risk of mortality, subsequent myocardial infarction, or further unplanned revascularization after high-risk coronary angioplasty (8).

Presently abciximab is primarily administered prior to coronary interventions to reduce the likelihood of thrombotic and ischemic complications prophylactically. Additionally, oral antiplatelet agents

(aspirin and clopidogrel) have demonstrable benefit in preventing subacute thrombosis after coronary angioplasty and stent placement (9). Kinetic studies have shown that there is approximately 80% reduction in adenosine diphosphate–moderated platelet aggregation 5 hours after a loading dose of 375 mg clopidogrel (10), with possible synergistic effect from blockade of the cyclooxygenase pathway by aspirin (11). Retrospectively, it is quite possible that the acute stent thrombosis experienced in this case may have been prevented by the prophylactic IV administration of abciximab or oral clopidogrel plus aspirin.

A recently emerging use for abciximab is in the “rescue” role, as described in the cardiology literature about patients with acute coronary stent thrombosis. Abciximab has also been used as an

adjunct to heparin and aspirin therapy to potentiate clot dissolution in acute myocardial infarction (12). Other case reports have recently described the use of IV abciximab in subacute stent thrombosis in occluded coronary (13) and renal stents (14). The potential usefulness of abciximab to potentiate thrombolysis is further illustrated by cases describing the selective intraarterial infusion of the drug in reduced dosages to recanalize thrombosed coronary arteries successfully in the setting of acute myocardial infarction (15).

Use of abciximab in neurovascular applications was first described in the cerebral circulation to prevent rethrombosis in the basilar artery after transluminal angioplasty (16). Samuels et al recently presented encouraging preliminary data on the safety and potential efficacy on abciximab as adjunctive therapy for vertebrobasilar angioplasty in 14 patients (17). Another recent case report described the thrombolytic role of IV abciximab as rescue therapy for treatment of acute parent vessel thrombosis during Guglielmi detachable coil placement for intracranial aneurysm embolization (18).

Our case illustrates the thrombolytic potential of abciximab in the setting of acute carotid stent thrombosis. Given the proven efficacy of IV abciximab in decreasing thrombus formation and ischemic complications during coronary interventions, platelet inhibition with glycoprotein IIb/IIIa receptor antagonists such as abciximab could play valuable therapeutic and prophylactic roles for patients undergoing neurovascular interventions. Further investigation will determine if abciximab is effective and safe in reducing complications of carotid angioplasty and stenting.

## References

1. Topol EJ, Califf RM, Lincoff AM, et al. **Platelet glycoprotein IIb/IIIa receptor blockade and low-dose heparin during percutaneous coronary revascularization. The EPILOG Investigators [see comments].** *N Engl J Med* 1997;336:1689-1696
2. Roubin GS, Yadav S, Iyer SS, Vitek J. **Carotid stent-supported angioplasty: a neurovascular intervention to prevent stroke.** *Am J Cardiol* 1996;78:8-12
3. Diethrich EB, Ndiaye M, Reid DB. **Stenting in the carotid artery: initial experience in 110 patients.** *J Endovasc Surg* 1996;3:42-62
4. Kornowski R, Hong MK, Saucedo J, et al. **Procedural results and long-term clinical outcomes following coronary stenting in perimycardial infarction syndromes.** *Am J Cardiol* 1998;82:1163-1167
5. Liu MW, Voorhees WD III, Agrawal S, Dean LS, Roubin GS. **Stratification of the risk of thrombosis after intracoronary stenting for threatened or acute closure complicating coronary balloon angioplasty: a Cook registry study.** *Am Heart J* 1995;130:8-13
6. Jeong MH, Owen WG, Staab ME, et al. **Porcine model of stent thrombosis: platelets are the primary component of acute stent closure.** *Cathet Cardiovasc Diagn* 1996;38:38-43
7. Makkar RR, Litvack F, Eigler NL, et al. **Effects of GP IIb/IIIa receptor monoclonal antibody (7E3), heparin, and aspirin in an ex vivo canine arteriovenous shunt model of stent thrombosis.** *Circulation* 1997;95:1015-1021
8. Topol EJ, Califf RM, Smith CR, et al. **Use of a monoclonal antibody directed against the platelet glycoprotein IIb/IIIa receptor in high-risk coronary angioplasty. The EPIC Investigation [see comments].** *N Engl J Med* 1994;330:956-961
9. Moussa I, Oetgen M, Roubin G, et al. **Effectiveness of clopidogrel and aspirin versus ticlopidine and aspirin in preventing stent thrombosis after coronary stent implantation.** *Circulation* 1999;99:2364-2366
10. Savcic M, 7Hauert J, Bachmann F, Wyld PJ, Geudelin B, Cariou R. **Clopidogrel loading dose regimens: kinetic profile of pharmacodynamic response in healthy subjects.** *Semin Thromb Hemost* 1999;25:15-19
11. Rupprecht HJ, Darius H, Borkowski U, et al. **Comparison of antiplatelet effects of aspirin, ticlopidine, or their combination after stent implantation.** *Circulation* 1998;97:1046-1052
12. Rechavia E, Wurzel M. **Platelet glycoprotein IIb/IIIa receptor blockade in acute myocardial infarction associated with thrombotic occlusion of the left main coronary artery.** *Circulation* 1998;98:1249-1250
13. Henry P, Boughalem K, Rinaldi JP, et al. **Use of anti-GP IIb-IIIa in acute thrombosis after intracoronary stent implantation.** *Cathet Cardiovasc Diagn* 1998;43:105-107
14. Berkompas DC. **Abciximab combined with angioplasty in a patient with renal artery stent subacute thrombosis.** *Cathet Cardiovasc Diagn* 1998;45:272-274
15. Bailey SR, O'Leary E, Chilton R. **Angioscopic evaluation of site-specific administration of ReoPro [see comments].** *Cathet Cardiovasc Diagn* 1997;42:181-184
16. Wallace RC, Furlan AJ, Moliterno DJ, Stevens GH, Masaryk TJ, Perl J III. **Basilar artery rethrombosis: successful treatment with platelet glycoprotein IIb/IIIa receptor inhibitor.** *AJNR Am J Neuroradiol* 1997;18:1257-1260
17. Samuels OB, Mohammad Y, Stern BJ, et al, presented at the American Society of Interventional and Therapeutic Neuroradiology meeting, January 1999
18. Lempert TE, Malek AM, Halbach VV, Phatouros CC, Dowd CF, Higashida RT. **Rescue treatment of acute parent vessel thrombosis with glycoprotein IIb/IIIa inhibitor during GDC coil embolization.** *Stroke* 1999;30:693-695