



## Get Clarity On Generics

Cost-Effective CT & MRI Contrast Agents



FRESENIUS  
KABI

WATCH VIDEO

# AJNR

## Balloon Angioplasty for Embolic Total Occlusion of the Middle Cerebral Artery and Ipsilateral Carotid Stenting in an Acute Stroke Stage

Takahisa Mori, Ken Kazita, Tatsuo Mima and Koreaki Mori

*AJNR Am J Neuroradiol* 1999, 20 (8) 1462-1464

<http://www.ajnr.org/content/20/8/1462>

This information is current as  
of August 6, 2025.

## Case Report

# Balloon Angioplasty for Embolic Total Occlusion of the Middle Cerebral Artery and Ipsilateral Carotid Stenting in an Acute Stroke Stage

Takahisa Mori, Ken Kazita, Tatsuo Mima, and Koreaki Mori

**Summary:** A 66-year-old man suffering from neurologic symptoms caused by acute embolic total occlusion of the left middle cerebral artery was treated successfully with balloon angioplasty, and an ipsilateral carotid stenosis subsequently was dilated with stenting. The patient's clinical outcome 30 days later was favorable. This therapeutic option may prove to be a useful means of treating a patient with acute stroke, embolic total occlusion of the middle cerebral artery, and an ipsilateral carotid stenosis.

In the United States, thrombolysis with intravenous recombinant tissue plasminogen activator is performed currently for patients with acute stroke within 3 hours after symptom onset (1). In Japan, however, the Ministry of Health and Welfare has not yet approved this procedure. In contrast, percutaneous transluminal cerebral balloon angioplasty (PTCBA) of the intracranial artery has already been approved in Japan and there are some reports of administering PTCBA to patients with acute stroke (2).

In general, percutaneous transluminal coronary angioplasty has already been shown to be of value as a means to recanalize total occlusion of the coronary artery in patients with acute myocardial infarction. In addition, it is reported that elective carotid stenting has good efficacy in resolving a high-grade stenosis of the carotid artery (3). We herein describe a case in which direct PTCBA resolved embolic total occlusion of the middle cerebral artery (MCA) and carotid stenting resolved a stenosis of the ipsilateral internal carotid artery (ICA) in an acute stroke phase.

## Case Report

A 66-year-old man suffering from severe dysarthria, severe aphasia, and right-sided hemiplegia was admitted to our institution

3 hours after symptom onset. The National Institutes of Health Stroke Scale score at admission was a score of 18, CT scans of the brain revealed no intracranial hemorrhage, and dynamic CT scanning (4) suggested decreased flow of the left MCA compared with the right MCA (Fig 1A). We attempted to perform diagnostic arteriography and, if necessary, PTCBA and stenting to open probable lesions directly. The Ministry of Health and Welfare in Japan has not yet approved any intravascular stents for supra-aortic arteries. The president of our institution, however, permitted us to use coronary or biliary stents for the supra-aortic arteries in the patient, if necessary. The patient's family provided informed written consent for arteriography, balloon angioplasty, and stenting for supra-aortic arteries.

The patient underwent arteriography while under local anesthesia. Pan-cerebral arteriography revealed total occlusion of the left MCA and a high-grade stenosis of the left ICA, indicating that artery-to-artery thromboembolism had occurred in the patient. We decided to perform PTCBA to open the total occlusion of the left MCA directly. A 7F guiding catheter (Mtech-MR2, Medikit Co. Ltd., Tokyo, Japan) was placed selectively via a femoral arterial route into the left common carotid artery (CCA). Heparin (10,000 units) was administered intravenously to avoid thrombus formation during the procedure. A 0.014-in guidewire (Dasher-14, Boston Scientific/Target, Fremont, CA) was navigated across the stenosis of the left ICA. A noncompliant balloon catheter (Symmetry; Boston Scientific/Mediatech, Watertown, MA) with a 6-mm diameter and a 40-mm length was guided over the wire and then was inflated twice at 10 atm for 60 seconds. The 0.014-in guidewire subsequently was navigated through the thrombus in the left MCA, and a flexible balloon catheter (Stealth, Boston Scientific/Target) with a 2.5-mm diameter and a 10-mm length was guided over the wire and then inflated twice at 6 atm for 60 seconds (Fig 1B). The left MCA was recanalized completely. Nevertheless, there was a residual stenosis in the left ICA. Carotid stenting subsequently was performed to dilate the stenosis sufficiently and prevent reocclusion of the left MCA attributable to thromboembolism. A 9F, 75-cm-long sheath (Tonokura, Tokyo, Japan) as a guiding catheter was replaced by an Mtech-MR2 guiding catheter and 7F sheath and was positioned directly in the left CCA. A 0.035-in guidewire (Radifocus; Terumo, Tokyo, Japan) was navigated across the residual stenosis of the left ICA, and a 9F self-expandable biliary stent (Wallstent, Boston Scientific/Schneider, Inc., Minneapolis, MN) with a 10-mm diameter and a 34-mm length was guided over the wire and deployed in the left ICA and CCA. The lesion was dilated sufficiently by firmly expanding the stent with a balloon catheter (Accent DG, Cook, Inc., Bloomington, IN) (Fig 1C) with a 6-mm diameter and a 20-mm length. No complications occurred during or after the procedure. After direct PTCBA and carotid stenting, 250 mL of low-molecular-weight dextran was administered twice a day for 7 days, 40 mg of sodium ozagrel was administered twice a day for 14 days, 60 mg of argatroban was administered once a day for the initial 2 days, and 10 mg of argatroban was adminis-

Received in original form October 21, 1998; accepted after revision March 13, 1999.

From the Division of Neurological Endovascular Intervention (T.M., K.K.) and the Department of Neurosurgery (T.M., K.M.), Kochi Medical School Hospital, Kochi, Japan.

Address reprint requests to Takahisa Mori, MD, PhD, Director, Division of Neurological Endovascular Intervention, Department of Neurosurgery, Kochi Medical School Hospital, Kohasu, Okoutyo, Nankoku City, Kochi 783–8505, Japan.

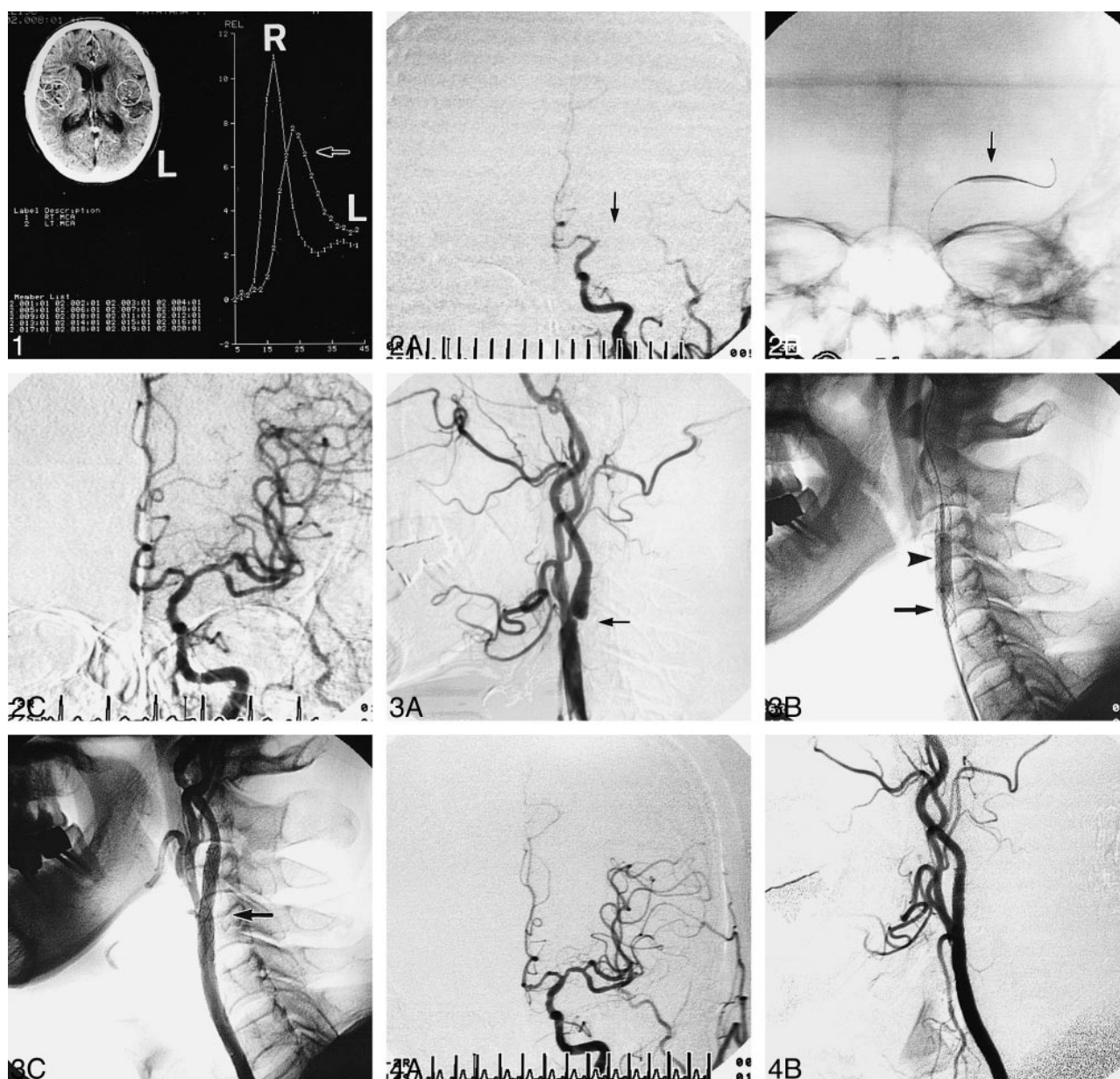


FIG 1. Time-density curve, calculated from dynamic CT scanning, reveals decreased flow of the left MCA (arrow) compared with the right MCA.

FIG 2. A, Anteroposterior view left carotid angiogram, obtained before PTCBA, reveals total occlusion of the left MCA (arrow). B, Anteroposterior view roentgenogram of the skull shows the 2.5-mm inflated balloon catheter (arrow). C, Anteroposterior view left carotid angiogram, obtained after PTCBA, shows complete recanalization of the left MCA.

FIG 3. A, Lateral view left carotid angiogram reveals a high-grade stenosis of the left ICA (arrow). B, Lateral view cervical roentgenogram shows the stent (arrow) and the balloon catheter (arrowhead). C, Lateral view of the left carotid angiogram, obtained after stenting, reveals sufficient dilation of the left ICA (arrow).

FIG 4. One-year follow-up angiograms of the left MCA (A) and ICA (B) depict good patency.

tered twice a day for an additional 12 days. Fourteen days later, orally administered ticlopidine replaced the sodium ozagrel and argatroban. The neurologic symptoms were improved remarkably after recanalization of the left MCA and the National Institutes of Health Stroke Scale score decreased to a score of 6 on the next day and to a score of 1 30 days later. The patient's ability to perform activities of daily living received a score of 100 on the Barthel index. One-year follow-up angiography revealed good patency of the left MCA and ICA (Fig 1D), no stroke recurred, and the patient's clinical outcome remained favorable.

## Discussion

PTCBA is a powerful means to reconstruct antegrade cerebral blood flow of the intracranial artery (5, 6). PTCBA can open directly not only total occlusion in patients with acute stroke without urokinase or recombinant tissue plasminogen activator (2) but also even chronic total occlusion of the intracranial artery, as some previous studies have reported (6, 7).



Weaver et al (8) reported that, based on outcomes at hospital discharge or 30 days later from 10 randomized trials, primary angioplasty seemed to be superior to thrombolytic therapy for treatment of patients with acute myocardial infarction. In addition, Ueda et al (9) reported that angioplasty might be an effective option for improving the success rate of recanalization and preventing reocclusion of the MCA and that the success rate of angioplasty for the MCA was 100%. Mori et al (10) reported successful cerebral artery stenting for total occlusion of the vertebrobasilar artery in an acute stroke stage. Even though there is an atherosclerotic stenosis in total occlusion, angioplasty can dilate the lesion adequately and the success rate of reperfusion can be increased. Therefore, direct PTCBA probably has a great effect on recanalizing intracranial total occlusion in patients with acute stroke and can likely yield a favorable clinical outcome.

There is, as yet, no stent specifically designed for carotid artery stenosis. Because the vascular Wallstent has not been available in Japan, we used the biliary Wallstent to be implanted in the carotid artery. To our knowledge, there is no previous report of direct PTCBA for MCA occlusion and ipsilateral carotid stenting in an acute stroke phase. This therapeutic option may prove to be a useful technique for treating patients with both MCA occlusion and ipsilateral carotid stenosis.

Nevertheless, several issues remain unsolved. Angioplasty of the MCA clot may create distal embolization. Direct PTCBA might be more effective when there is an associated atherosclerotic stenosis in total occlusion of the intracranial artery. Overinflation of a balloon catheter causes intracranial artery dissection, leading to fatal subarachnoid hemorrhage. The age of a thrombus on a carotid stenosis, causing an MCA occlusion, may have some bearing on the likelihood of success or complication of direct PTCBA. Intracerebral or intraventricular hemorrhage may occur after carotid stenting (11), because opening the ICA to full perfusion pressure after clot dissolution could cause hyperperfusion injury if a major infarct has occurred. Therefore, direct PTCBA for an MCA oc-

clusion and ipsilateral carotid stenting must be applied carefully, although direct angioplasty without urokinase or recombinant tissue plasminogen activator may be performed safely even when early CT findings are found (2). Pretreatment single-photon emission CT may provide useful information to increase the efficacy of reperfusion therapy by reducing hemorrhagic complications and improving neurologic outcome (12).

In conclusion, this initial result of direct PTCBA for embolic MCA occlusion and ipsilateral carotid stenting for a patient with acute stroke is very encouraging and warrants further investigation.

## References

1. The National Institute of Neurological Disorders and Stroke rt-PA Stroke Study Group. **Tissue plasminogen activator for acute ischemic stroke.** *N Engl J Med* 1995;333:1581-1587
2. Nakano S, Yokogami K, Ohta H, Yano T, Ohnishi T. **Direct percutaneous transluminal angioplasty for acute middle cerebral artery occlusion.** *AJNR Am J Neuroradiol* 1998;19:767-772
3. Yadav JS, Roubin GS, Iyer S, Vitek J, King P, Jordan WD, Fisher WS. **Elective stenting of the extracranial carotid arteries.** *Circulation* 1997;95:376-381
4. Lo EH, Rogowska J, Bogorodzki P, Trocha M, Matsumoto K, Saffran B, Wolf GL. **Temporal correlation analysis of penumbra dynamics in focal cerebral ischemia.** *J Cereb Blood Flow Metab* 1996;16:60-68
5. Clark WM, Barnwell SL, Nesbit G, O'Neil OR, Wynn ML, Coull BM. **Safety and efficacy of percutaneous transluminal angioplasty for intracranial atherosclerotic stenosis.** *Stroke* 1995;26:1200-1204
6. Mori T, Fukuoka M, Kazita K, Mori K. **Follow-up study after intracranial percutaneous transluminal cerebral balloon angioplasty.** *AJNR Am J Neuroradiol* 1998;19:1525-1533
7. Mori T, Mori K, Fukuoka M, Honda S. **Percutaneous transluminal cerebral angioplasty for total occlusion of middle cerebral arteries.** *Neuroradiology* 1997;39:71-74
8. Weaver WD, Simes RJ, Betriu A, Grines CL, Zijlstra F, Garcia E, Grinfeld L, Gibbons RJ, Ribeiro EE, DeWood MA, Ribichini F. **Comparison of primary coronary angioplasty and intravenous thrombolytic therapy for acute myocardial infarction. A quantitative review.** *JAMA* 1997;278:2093-2098
9. Ueda T, Sakaki S, Nochi I, Kumon Y, Kohno K, Ohta S. **Angioplasty after intra-arterial thrombolysis for acute occlusion of intracranial arteries.** *Stroke* 1998;29:2568-2574
10. Mori T, Kazita K, Seike M, Nojima Y, Mori K. **Successful cerebral artery stent placement for total occlusion of the vertebrobasilar artery in a patient suffering from acute stroke.** *J Neurosurg* 1999;90:955-958
11. Mori T, Fukuoka M, Mori K. **Intraventricular hemorrhage after carotid stenting.** *J Endovasc Surg* (in press)<sup>2</sup>
12. Ueda T, Sakaki S, Yuh WT, Nochi I, Ohta S. **Outcome in acute stroke with successful intra-arterial thrombolysis and predictive value of initial single-photon emission-computed tomography.** *J Cereb Blood Flow Metab* 1999;19:99-108