



Providing Choice & Value

Generic CT and MRI Contrast Agents



**FRESENIUS
KABI**

CONTACT REP

AJNR

Giant Fibrovascular Polyp of the Oropharynx

Alexandra Borges, Henry Bikhazi and Jeffrey P. Wensel

AJNR Am J Neuroradiol 1999, 20 (10) 1979-1982

<http://www.ajnr.org/content/20/10/1979>

This information is current as
of July 20, 2025.

Giant Fibrovascular Polyp of the Oropharynx

Alexandra Borges, Henry Bikhazi, and Jeffrey P. Wensel

Summary: We describe a case of a giant fibrovascular polyp arising from the oropharynx and causing vague clinical symptoms. To our knowledge, this is the first description of an oropharyngeal fibrovascular polyp reported in the medical literature. The diagnosis was based on MR imaging findings, which showed the size and configuration of the polyp as well as the site of attachment. The patient underwent surgery, and the diagnosis was confirmed histologically.

In the cases reported to date, the fibrovascular polyps all arose from the esophagus or hypopharynx, most (85% to 90%) adjacent to the cricopharyngeal muscle (1–5). To our knowledge, this is the first case of a fibrovascular polyp arising from the oropharynx.

Case Report

A 49-year-old woman presented with a 1-year history of mild dyspnea, which was exacerbated when she was in the left lateral decubitus position, and a recent onset of occasional difficulty swallowing. She denied dysphonia, regurgitation, or retrosternal pain and also denied any weight loss. Her medical history was negative for gastric problems and evidence of gastroesophageal reflux.

A physical examination performed by an otolaryngologist disclosed an oropharyngeal mass in the region of the right palatine tonsil, which extended inferiorly into the hypopharynx and prevented adequate visualization of the pyriform sinuses. The mass was smooth and erythematous without being friable. No bleeding was elicited during the clinical examination.

MR imaging of the neck was ordered to characterize the origin and extent of the mass further (Fig 1A–E). The MR study, performed on a 1.5-T imager, showed a pedunculated soft-tissue mass originating in the oropharynx from the posterior aspect of the right palatine tonsil and extending inferiorly along the posterior wall of the hypopharynx into the proximal cervical esophagus. The mass measured 9 cm in length, with its distal tip seen at the C7–T1 disk space. The stalk, hyperintense on T1-weighted images and hypointense on fat-suppressed images, extended inferiorly from the posterior aspect of the right palatine tonsil, coursing behind the epiglottis and right aryepiglottic fold, medially to the right pyriform sinus and along the post-cricoid space. More inferiorly, the lesion had a globular configuration and filled the lumen of the prox-

imal cervical esophagus. The mass bulged into the supraglottic larynx, distorting the laryngeal vestibule. The stalk showed a central linear core of T1 and T2 hypointensity, likely representing fibrovascular tissue. The contrast-enhanced images showed mild enhancement of this fibrovascular core. No lymphadenopathy was detected in the cervical region, and no other abnormalities were seen in the visceral compartment of the neck.

Based on the results of the clinical examination and the imaging findings, a presumptive diagnosis of giant fibrovascular polyp was made. The patient was scheduled to undergo surgery while under general anesthesia. At surgery, after securing the airway and using a microlaryngoscope, the large pedunculated mass originating from the body of the right palatine tonsil was delivered from the esophagus into the oropharynx. The mass and palatine tonsil were excised en bloc using the potassium Titanyl phosphate laser (Fig 1F). Successful hemostasis was obtained by fulguration of the base of the mass and electrocauterization of a large central artery.

Macroscopically, this sausage-shaped mass measured 9 cm in length and showed a wrinkled, reddish, glistening surface, with no evidence of ulceration (Fig 1G). The cut section of the mass showed soft yellow submucosal tissue with longitudinally oriented vascular structures. Microscopic evaluation of the pathologic specimen showed dilated vascular spaces surrounded by a matrix of fibrous connective and adipose tissue (Fig 1H). The mucosal surface of the lesion was covered by squamous epithelium, with no evidence of hyperplastic or dysplastic changes. The final pathologic diagnosis confirmed a giant fibrovascular polyp arising from the palatine tonsil.

The immediate postoperative period was uneventful. At the first postoperative visit, 1 week after surgery, the patient's symptoms had resolved.

Discussion

Fibrovascular polyps are thought to originate from areas of diminished resistance in the pharyngeal musculature and to be initiated secondary to changes in pressure during the different phases of swallowing (6–8). In a review of esophageal and hypopharyngeal fibrovascular polyps, Owens et al (6) describe two areas of inherent weakness in the posterior wall of the hypopharynx: one between the superior and inferior cricopharyngeal muscles (Killian's dehiscence), and the second between the inferior cricopharyngeus muscle and the proximal end of the esophagus (also known as the area of Laimer-Haeckermann, or Laimer triangle). Polyps are thought to originate from nodular submucosal thickenings or redundant submucosal folds, which, because of changes in intrinsic mucosal tension and lack of muscular support, evaginate into the surrounding lax connective tissue. Then, through a mechanism of traction triggered by peristaltic activity, the size of these mucosal/submucosal "evaginations" increases to attain giant proportions (6–8).

Received March 1, 1999; accepted after revision May 20.

From the Department of Radiological Sciences (A.B.), University of California, Los Angeles Medical Center, Los Angeles, CA; the Department of Head and Neck Surgery (H.B.), Hoag Memorial Hospital, Newport Beach, CA; and Radiology Associates, P.C. (J.P.W.), Eugene, OR.

Address reprint requests to Alexandra Borges, Department of Radiological Sciences, University of California, Los Angeles Medical Center, 10833 Le Conte Avenue, 90024-2771 Los Angeles, CA.

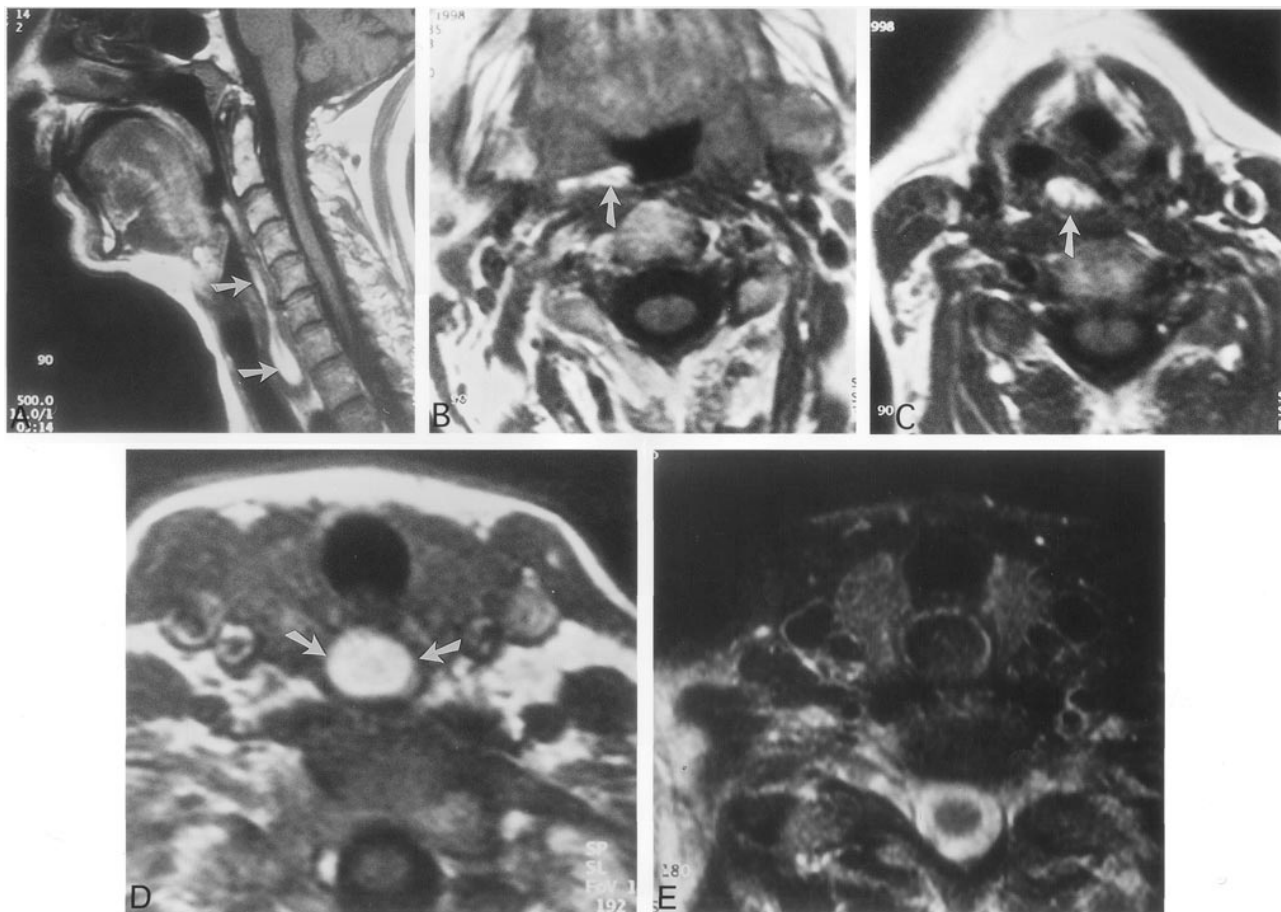


FIG 1. The case of a 49-year-old woman who presented with a 1-year history of mild dyspnea and recent onset of occasional difficulty swallowing.

A, Sagittal T1-weighted MR image shows a sausage-shaped hyperintense mass extending inferiorly from the oropharynx, posterior to the base of the tongue, to the cervical esophagus along the posterior pharyngeal wall and postcricoid space (arrows).

B, Axial T1-weighted MR image shows the site of origin of the pedicle in the posterior aspect of the right palatine tonsil and the medially directed stalk (arrow).

C, Axial T1-weighted MR image, obtained at the level of the supraglottic larynx, shows the position of the polyp behind the right aryepiglottic fold, medial to the pyriform sinus (arrow).

D, Axial T1-weighted image, obtained at the level of the first tracheal ring, shows a hyperintense mass filling the lumen of the proximal cervical esophagus (arrows).

E, Axial contrast-enhanced fat-saturated T1-weighted image, obtained at the same level as that shown in Figure 1D, shows loss of signal and confirms its fatty nature.

The pathophysiologic mechanism underlying the origin of oropharyngeal polyps is unknown. In this case, the origin of the polyp from the palatine tonsil cannot be explained by muscular weakness. Nonetheless, a small mucosal lesion in the tonsillar region exposed to the pressure changes associated with deglutition and innumerable boluses of swallowed material could provide a nidus for the formation of a giant fibrovascular polyp.

Giant fibrovascular polyps display a spectrum of clinical presentations, which vary from vague prolonged symptoms to life-threatening episodes of asphyxiation (6, 8). Most commonly, fibrovascular polyps present with dysphagia, dysphonia, odynophagia, recurrent episodes of dyspnea or choking sensation, and retrosternal discomfort. Intermittent regurgitation of the polyp is not an uncommon occurrence and usually is associated with an episode

of coughing or eructation accompanied by a choking sensation relieved by swallowing of the polyp (2). When symptoms are vague, patients may be misdiagnosed as having a psychiatric disorder. Diagnosis of this condition may be challenging, because the submucosal nature of the tumor may make it undetectable by clinical and endoscopic examinations. Twenty-five per cent of intraluminal and intramural esophageal tumors are missed by performing endoscopy (7). Not infrequently, the polyp's mucosa is mistaken for the normal esophageal or pharyngeal mucosa and the tumor remains undetected (6, 7). Therefore, imaging of these patients is mandatory, not only to detect the mass but also to determine the extent and site of origin. Most hypopharyngeal and esophageal polyps have been diagnosed on barium swallow studies as filling defects (8, 9). This study has limitations, however, in that it does not adequately reflect the site of origin,

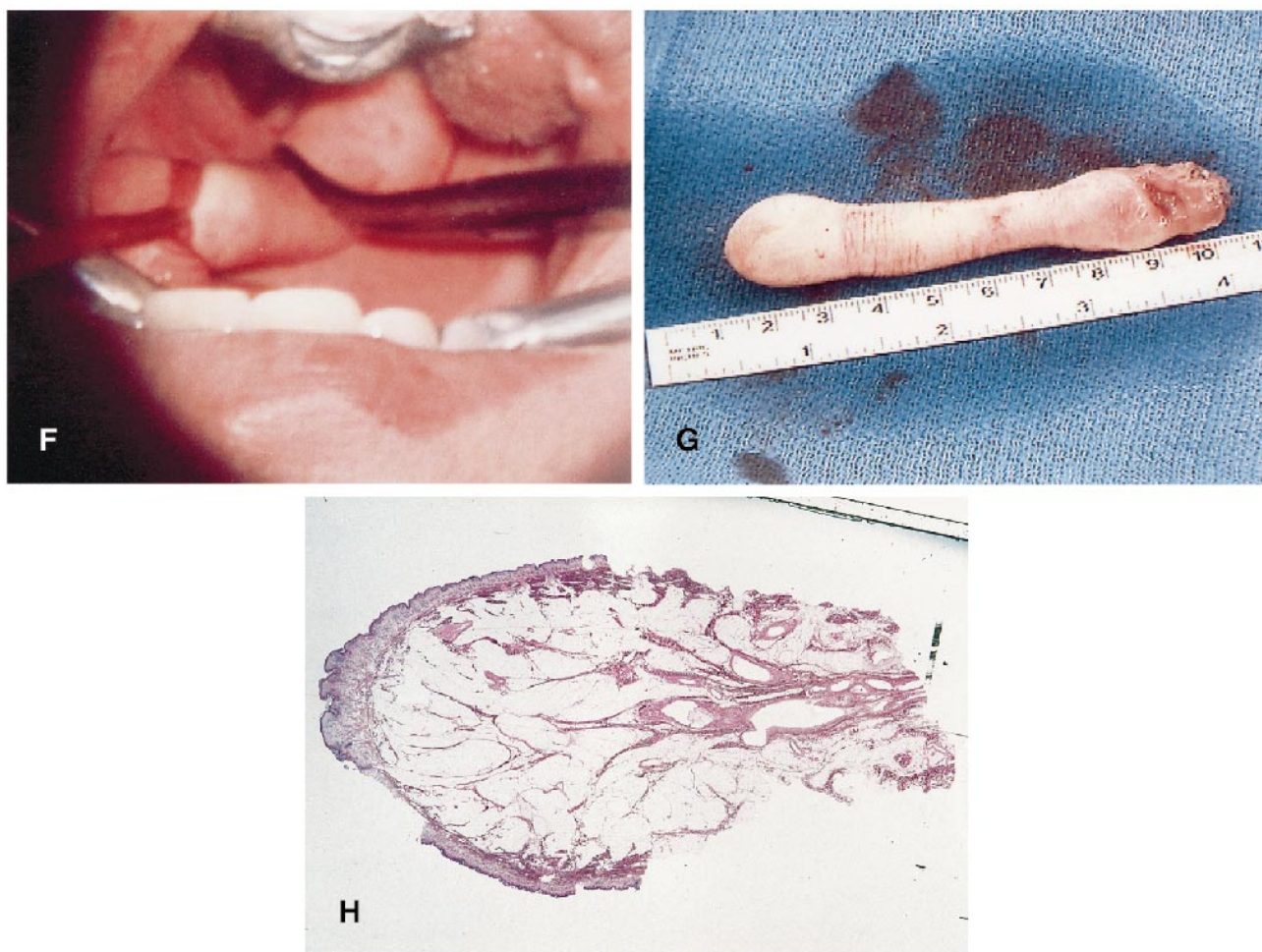


FIG 1. Continued.

F, Intraoperative photograph showing the fibrovascular polyp being delivered into the oral cavity through gentle traction. Note the origin of the pedicle from the body of the right palatine tonsil.

G, Photograph of the surgical specimen after resection shows a 9-cm sausage-shaped lesion covered by wrinkled mucosa.

H, Photomicrograph of a longitudinal section through the body of the polyp (hematoxylin and eosin stain; original magnification, $\times 100$) shows a central core of dilated vascular spaces surrounded by a matrix of fibrous connective and adipose tissue covered by normal squamous epithelium, with no evidence of hyperplastic or dysplastic changes.

which is important information for surgical planning.

Cross-sectional imaging, particularly MR imaging, is ideal for delineation of this lesion. CT and MR findings of fibrovascular polyps have been described by Whitman et al (7). MR imaging, because of its multiplanar capability and high soft-tissue resolution, allows optimal characterization of this tumor. Sagittal and coronal sections are ideal for showing the extent of the lesion and different pulse sequences, including T1-weighted, T2-weighted, fat-saturated, and contrast-enhanced T1-weighted imaging, may provide valuable information regarding the composition of the mass. Fatty elements are identified easily on MR images as areas of T1-weighted hyperintensity that follow the signal of subcutaneous fat on all pulse sequences and appear hypointense on the fat-suppressed images. Similarly, areas of T1 and T2 hypointensity may reflect the presence of fibrovascular elements. In the case presented herein, the imaging features strongly sug-

gested the diagnosis, and there was excellent correlation between the MR and pathologic findings.

Polypoid lesions may have many different histologic abnormalities (1). Therefore, it is important to consider other neoplastic and non-neoplastic conditions that may present as a polyp in the differential diagnosis. These include hamartomas, inflammatory polyps, lipomas, hemangiomas, lymphangiomas, schwannomas (10), and other unusual neoplasms, such as carcinoid tumors and chemodectomas. Histologically, giant polyps are a mixture of fibrous elements, adipose tissue, and vessels (8). Depending on the preponderant elements, they may be classified as fibromas, fibrolipomas, or fibrovascular polyps. The possibility of life-threatening asphyxiation due to airway obstruction is an important concern and should be considered when managing this condition. Once the presumptive diagnosis is made, it is crucial to secure the airway and treat the patient as soon as possible. Surgical

removal, using laser or cryocoagulation, remains the treatment of choice.

References

1. Halfhide BC, Ginai AZ, Spoelstra HA, Dees J, Vuzevski VD. **Case report. A hamartoma presenting as a giant oesophageal polyp.** *Br J Radiol* 1995;68:85–88
2. Jang GC, Clouse ME, Fleishner FG, et al. **Fibrovascular polyp. A benign intraluminal tumor of the esophagus.** *Radiology* 1969; 92(6):1196–1200
3. Walters NA, Coral A. **Fibrovascular polyp of the oesophagus. The appearances on computed tomography.** *Br J Radiol* 1988; 61:641–643
4. Lee KN, Auh JY, Nam KJ, Sung SC. **Regurgitated giant fibrovascular polyp of the esophagus [letter].** *AJR Am J Roentgenol* 1996;166:730
5. Le Blanc J, Carrier G, Ferland S, Boutet M, et al. **Fibrovascular polyp of the esophagus with computed tomographic and pathological correlation.** *Can Assoc Radiol J.* 1990;87–89
6. Owens JJ, Donovan DT, Alford EL, McKechnie JC, Franklin DJ, Stewart MG, Schwartz MR. **Life-threatening presentations of fibrovascular esophageal and hypopharyngeal polyps.** *Ann Otol Rhinol Laryngol* 1994;103:838–842
7. Whitman GJ, Borkowski GP. **Giant fibrovascular polyp of the esophagus. CT and MR findings.** *AJR Am J Roentgenol* 1989; 152:518–520
8. Partensky C, Partensky C, Caillon P, Berger F, Valette PJ, Moulinier B. **X-ray computed tomography in the diagnosis and treatment of fibrovascular polyp of the esophagus.** *Chirurgie* 1988;114:217–222
9. Eliashar R, Saah D, Sichel JY, Elidan J. **Fibrovascular polyp of the esophagus.** *Otolaryngol Head Neck Surg* 1998;118:734–735
10. Eberlein TJ, Eberlein TJ, Hannan R, Josa H, Sugarbaker DJ. **Benign schwannoma of the esophagus presenting as a giant fibrovascular polyp.** *Ann Thorac Surg* 1992;53:343–345