



Get Clarity On Generics

Cost-Effective CT & MRI Contrast Agents

**FRESENIUS
KABI**

[WATCH VIDEO](#)

AJNR

Follow-up of Conservatively Managed Epidural Hematomas: Implications for Timing of Repeat CT

Thomas P. Sullivan, Jeffrey G. Jarvik and Wendy A. Cohen

AJNR Am J Neuroradiol 1999, 20 (1) 107-113

<http://www.ajnr.org/content/20/1/107>

This information is current as
of August 9, 2025.

Follow-up of Conservatively Managed Epidural Hematomas: Implications for Timing of Repeat CT

Thomas P. Sullivan, Jeffrey G. Jarvik, and Wendy A. Cohen

BACKGROUND AND PURPOSE: Small asymptomatic epidural hematomas (EDHs) are frequently managed nonoperatively with good neurologic outcome. Our goals were to determine the frequency and timing of enlargement of acute traumatic EDHs that are not immediately surgically evacuated as well as to identify factors associated with rehemorrhage.

METHODS: Of 252 consecutive patients with acute traumatic EDH who were treated over a 5-year period, 160 were managed nonoperatively. Their CT scans, imaging reports, and medical records were reviewed retrospectively. Parameters analyzed as possible predictors of rehemorrhage during nonoperative management were size of the EDH, presence of an associated fracture, contralateral brain injury, midline shift, coagulopathy, and neurologic and physiological injury as measured by the Revised Trauma Score. We compared discharge disposition as a proxy for neurologic condition at discharge.

RESULTS: The EDH enlarged in 37 (23%) of the 160 patients during conservative management. Mean enlargement was 7 mm, and the mean time to enlargement was 8 hours after injury and 5.3 hours after CT diagnosis. EDH enlargement occurred within 36 hours after injury in all cases. Of the parameters analyzed, only a high Revised Trauma Score correlated significantly with EDH rehemorrhage, suggesting that intubation and chemical paralysis may prevent rehemorrhage through the restriction of head movement and the control of blood pressure. The subgroup of patients with rehemorrhage experienced no difference in neurologic outcome despite a higher rate of clinical deterioration.

CONCLUSION: EDH enlargement occurs frequently, but early. Repeat imaging with CT is most appropriate within 36 hours after injury.

Nonoperative management of small asymptomatic epidural hematomas (EDHs) is increasingly accepted for patients with convexity lesions without associated midline shift or significant mass effect. However, no firm consensus in the literature exists regarding the required length of conservative observation (1), and it is unclear whether immediate surgery is not more cost-effective than serial CT scanning, intracranial pressure (ICP) monitoring, and neuropsychological testing performed to determine the presence of delayed deterioration (2).

Delayed deterioration after EDH is typically the result of progressive cerebral swelling and ischemia (3). Rehemorrhage or continued hemorrhage re-

mains a concern as a cause of delayed deterioration in nonoperatively managed patients. In small series, the frequency of EDH enlargement has been reported to range from 5.5% to 65% (1, 4–7).

The primary goals of this study were to determine the frequency of enlargement of acute EDHs that are conservatively managed, to determine when that enlargement is most likely to occur, to identify the clinical factors at presentation and initial CT findings that might predict subsequent EDH enlargement, and, finally, to compare clinical outcomes between patients with conservatively managed EDHs that enlarged and those that did not.

Methods

We conducted a retrospective review of consecutive patients with acute traumatic EDH admitted to a regional level I trauma center from February 1992 to February 1997, using a computerized imaging records tracking system, a manual review of imaging logbooks, and medical records. Approval was obtained from the institution's human subjects review board. We identified 252 patients with EDH and, from these, a subgroup of patients in whom the initial treatment was nonsurgical. Their CT scans and clinical records were reviewed.

Received March 23, 1998; accepted after revision August 20.

Supported by a grant from the GE-Radiology Research Academic Fellowship (J.G.J.).

Presented at the annual meeting of the American Society of Neuroradiology, Toronto, Canada, May 1997.

From the Department of Radiology, University of Washington Medical Center, 1959 NE Pacific St, 357115, Seattle, WA 98195.

Address reprint requests to Jeffrey Jarvik, MD.

© American Society of Neuroradiology

TABLE 1: Comparison of clinical data for patients with enlarging epidural hematoma (EDH) (patient group) and those with stable EDH (control group)

	Patient Group (%)	Control Group (%)	P Value
Number	37 (23.1)	123 (76.9)	
Age (y)	23	27	.25
Males	31 (84)	96 (78)	.77
Supratentorial location	33 (89)	117 (95)	
Delayed	1 (2.7)	4 (3.2)	
Coagulopathy	1 (3)	3 (3)	.98
Revised Trauma Score (0–12)	10.5 (SD, 2.5)	8.9 (SD, 3.7)	.02
Width	10 mm (SD, 7 mm)	9 mm (SD, 6 mm)	
Increase in width	7 mm (SD, 8.5 mm)		
Interval from injury to initial CT	3 h (SD, 4 h)	4.2 h (SD, 5.3 h)	
Interval from injury to EDH	8.2 h (SD, 6.7 h)		
Enlargement			
Interval from initial CT to EDH	5.3 h (SD, 4.3 h)		
Enlargement			

Of the 252 patients with acute traumatic EDH, 216 initial diagnostic CT scans were obtained at the time of admission to the trauma center, and 36 were obtained at outside institutions before transfer. All follow-up CT scans were obtained at the trauma center, except for one patient, whose EDH was identified as enlarging on a follow-up scan at the outside institution to which he was admitted before his transfer to our center. Scans were obtained without contrast in 5-mm axial sections at 7-mm intervals from vertex to foramen magnum and displayed in window settings for brain parenchyma (width, 80 HU; level, 30 HU), extraaxial hemorrhage (width, 150 HU; level, 40 HU), and bone (width, 4000 HU; level, 400 HU) and filmed in 16-on-1 format until 1994 and subsequently in 20-on-1 format. Follow-up scans were obtained emergently if neurologic status deteriorated or headache was reported as worsening. Routine follow-up scans were generally obtained within 24 hours in neurologically stable, conservatively managed patients. Those patients with a nonoperatively managed EDH that did not enlarge on at least one follow-up CT scan were used as control subjects for comparison against those with an EDH that did enlarge under observation.

Two observers rated the presence and time interval of enlargement (measured with calipers as an increase in width) of the EDH, the presence of skull fracture, contralateral brain injury, or extraaxial hemorrhage, and the presence and degree of midline shift. Scans showed no or mild midline shift if less than 5 mm, moderate midline shift if 5 to 10 mm, and severe shift if more than 10 mm. The only disagreements between the readers were whether a mild versus no midline shift had occurred in two patients. We resolved one of these disagreements by consensus; the other required a third neuroradiologist's opinion.

We reviewed medical records to determine the interval between injury and initial CT scan, the clinical factors at the time of presentation (including coagulation parameters [prothrombin time/partial thromboplastin time]), and the Revised Trauma Score (RTS), a physiological indicator of injury severity that combines respiratory rate, systolic blood pressure, and the Glasgow Coma Scale (GCS) score, with 0 to 4 points for each category (8). A higher RTS indicates a patient with less severe injuries, and an intubated and chemically paralyzed patient receives a score of 4 (0 points for a GCS score of 3, 0 points for respiratory rate, and 4 points for normal systolic blood pressure).

Disposition at discharge was measured as a proxy for clinical outcome. Disposition to home, to a rehabilitation facility, or to a skilled nursing facility corresponded to progressively more severe neurologic impairment.

χ^2 and Fisher's exact tests were performed to compare categorical variables and independent samples *t*-tests were used

for continuous variables. We also performed a multivariate logistic regression, with rehemorrhage as the dependent variable and the imaging parameters (fracture, shift, contralateral injury) and clinical parameters (coagulopathy and RTS) as independent variables.

Results

In the 5-year period studied, 252 patients were admitted with acute traumatic EDH, 92 (36.5%) of whom underwent immediate surgical evacuation and were not included in the study group. The remaining 160 patients (63.5%) were examined with at least one follow-up CT scan, either as part of conservative observation or until definitive surgery could be performed. Medical records were available for all patients whose EDH enlarged and for all but seven of the patients whose EDH did not enlarge.

The EDHs enlarged in 37 patients (23%) (Table 1). In all 37 patients, enlargement was detected on the first follow-up scan after diagnosis. One EDH enlarged 17 hours after injury and again 11 hours later, without subsequent enlargement thereafter. It was located in the posterior fossa, was presumed venous in origin, was 9 mm in width, and did not require surgery. All but four EDHs were supratentorial. Only one enlarging EDH was delayed in initial appearance (not present on the initial postinjury CT scan, but seen on a 3-hour follow-up scan). The mean age of patients with an enlarged EDH was 23 years (range, 1 to 87 years), and 84% were male. The average size of the initial EDH was 10 mm (SD, 7 mm), and the average increase in width was 7 mm (SD, 8.5 mm).

The mean time to CT scanning after injury was 3 hours (SD, 4 hours). All 37 patients had their initial CT scan within 24 hours after injury: 34 within 3 hours, one at 8 hours, one at 11 hours, and one at 24 hours. The patient whose EDH was detected 24 hours after injury had EDH enlargement 12 hours later (36 hours after injury). The initial EDH was 8 mm in width and enlarged to 12 mm. It did not require surgical evacuation, and the

patient was discharged home within 48 hours with no neurologic deficit.

The mean interval between injury and EDH enlargement was 8.2 hours (SD, 6.7 hours). All 37 EDHs enlarged within 24 hours after the initial CT scan: 35 (95%) of 37 enlarged within 12 hours, one (3%) enlarged after 14 hours, and one (3%) enlarged 24 hours after the initial diagnostic scan.

Because of the retrospective nature of this study and the physical constraints of routine CT scanning in patients with multiple injuries in a busy trauma center, these data points represent times at which EDH enlargement was detected, not necessarily when it occurred. In all but one of the 37 patients, EDH enlargement was seen on the first follow-up scan. In one patient, the EDH was not present on the admission scan but was detected on a follow-up scan at 3 hours. Careful evaluation of intermediate window settings (width, 150 HU; level, 40 HU) excluded an isodense EDH on the admission scan. It an enlarged 4 hours later and remained stable on a subsequent scan. The patient did not require surgery and was discharged home without neurologic deficit.

Our control group consisted of 123 patients in whom the EDH remained stable under observation (Table 1). The mean age of the control subjects was 27 years, and 78% were male. The average width of the EDH was 9 mm (SD, 6 mm). All but six were supratentorial, and four were delayed in appearance (not present on the initial CT scans but present on follow-up scans, at a mean interval of 9.7 hours [SD, 6.3 hours]). Delayed EDHs are a somewhat controversial entity. With delayed EDHs, a vascular injury presumably has occurred by the time the initial CT scan with negative findings is obtained, but the extraaxial hemorrhage is identified later, when factors such as increasing venous or arterial blood pressure overcome the tamponade effect of elevated ICP (9–11). These subjects were not included in the patient group because our goal was to identify risk factors for EDH enlargement in patients with known EDH. Patients without an identified EDH (even if it was present but too small to detect by CT) were treated differently, clinically, from those with an identified EDH and, as such, for our primary analyses, were not included in our patient group. The single delayed EDH in the patient group and the four delayed EDHs in the control group all had fractures on the initial scan, which showed no EDH.

No statistically significant difference in the initial CT findings was found between the patient and control groups when examined for the size of the EDH, fractures associated with the EDH, contralateral brain injury or extraaxial hemorrhage, or the presence or degree of midline shift, quantitated as mild, moderate, or severe (Table 2). We did not have the data available to examine ICP values in this series.

Clinical data, including coagulation parameters (prothrombin time/partial thromboplastin time) and

TABLE 2: Comparison of imaging features for patients with enlarging epidural hematoma (EDH) (patient group) and those with stable EDH (control group)

	Patient Group (%)	Control Group (%)	P Value
Fracture	32 (86)	101 (82)	.41
Contralateral injury	14 (38)	53 (53)	.43
No midline shift	22 (60)	85 (69)	.44
Mild shift	10 (27)	25 (20)	.54
Moderate shift	3 (8)	11 (9)	.76
Severe shift	2 (5)	2 (2)	.23

TABLE 3: Comparison of neurologic status at discharge as measured by disposition

Discharge Disposition	Patient Group (%)	Control Group (%)
Home	23 (62)	71 (62)
Rehabilitation facility	8 (22)	27 (24)
Skilled nursing facility	2 (5)	12 (11)
Died	4 (11)	3 (3)

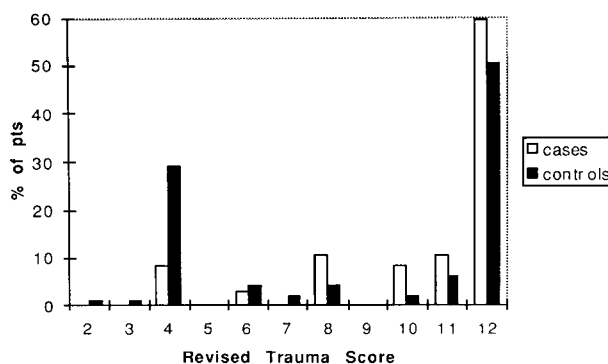


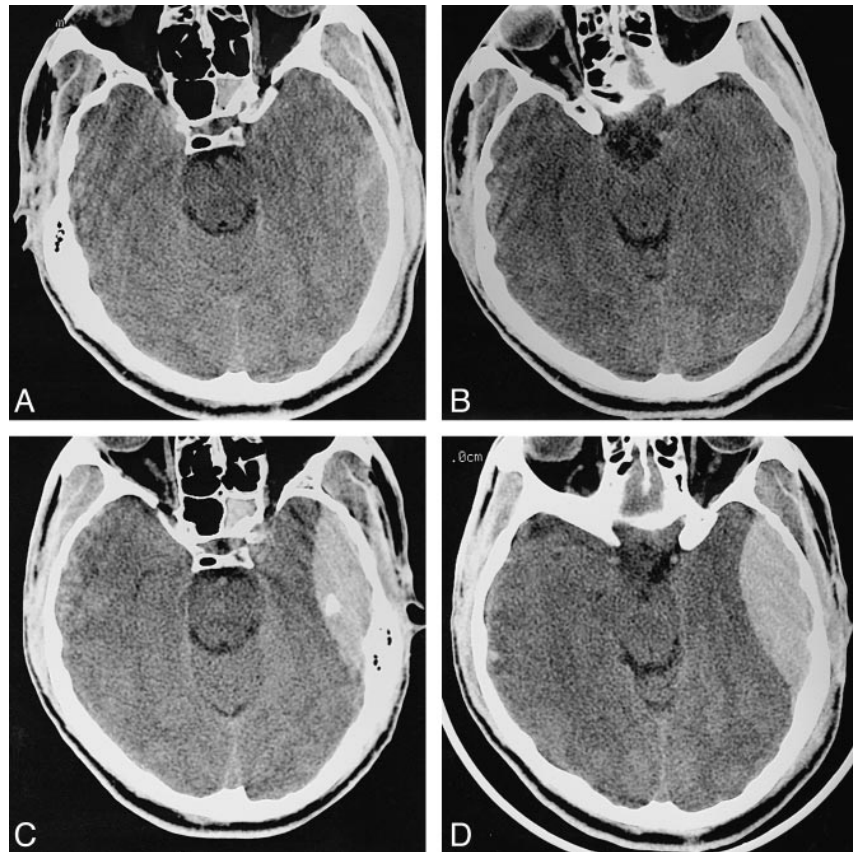
FIG 1. Graph of RTS subgroups in patients (enlarging EDH under conservative management) and control subjects (stable EDH). Note that a higher RTS indicates less severe injury, and an RTS of 4 indicates an intubated and paralyzed patient.

RTS, were available for all 37 patients and 113 of 123 control subjects. Multivariate regression analysis performed to evaluate predictors of EDH enlargement determined that only the RTS correlated significantly with EDH enlargement (Table 3). We found that the patients with higher RTS (presumably less severely injured) were more likely to have EDH enlargement ($P = .02$) (Fig 1), with an increase in the odds ratio of 1.17 for every point increase in the RTS (exponent of coefficient $\beta = 1.17$). Fewer patients in the patient group were intubated at the time of the initial CT scan (eight [22%] of 37 patients vs 45 [40%] of 113 control subjects). An even smaller percentage of the patients were intubated and chemically paralyzed as compared with the control subjects (three [8%] of 37 patients vs 33 [29%] of 113 control subjects). The most frequent abnormal RTS (ie, a score below 12) for control subjects was 4, which is the score assigned for intubated and chemically paralyzed patients (Fig 1).

FIG 2. Unenhanced CT scans of a 36-year-old male assault victim (initial CT scan 2 hours after injury).

A and B (at a level 5 mm contiguously higher than A), Scans show a left temporal EDH, 2 cm in width. The patient was neurologically normal at the time of the initial CT scan.

C and D (at a level 5 mm contiguously higher than C), Follow-up scans 10 hours later, after decline in neurologic status prompted repeat scanning. The EDH enlarged to 3 cm in width, associated with early ipsilateral uncal herniation. The patient underwent surgical evacuation and was discharged to a skilled nursing facility after a 17-day hospitalization.



We repeated the logistic regression twice, switching the four control subjects with delayed EDH into the group of 37 patients as well as excluding delayed EDH cases from both the patient and the control groups. The significance of the RTS ($P = .03$) remained essentially unchanged when we excluded patients with delayed EDH from both the patient and the control groups, nor did it change the resulting odds ratio (exponent of coefficient $\beta = 1.15$). However, switching the four subjects with delayed EDH from the control group to the patient group changed the significance of the RTS as a predictor of rehemorrhage ($P = .07$), making it borderline insignificant. This P value is still much smaller than any of the other factors analyzed, and the apparent lack of stability of the significance of the RTS is most likely attributable to our relatively small sample size.

Slightly less than half (16 of 37) of the patients with EDH enlargement subsequently underwent surgery. All but two of these patients had deteriorated clinically, manifested by worsening headache or a decreasing level of consciousness. At our institution, worsening neurologic status, in addition to EDH enlargement, is an indication for surgical EDH evacuation. Five of the 37 patients had EDH enlargement greater than 10 mm, four of whom deteriorated clinically. Five of nine patients with EDH enlargement of 5 to 10 mm deteriorated clinically, as did five of the 23 patients with EDH enlargement of less than 5 mm. In contrast, only 22

(18%) of 123 patients with a stable EDH underwent surgery, of whom 17 (77%) had deteriorated clinically. This was a statistically significant difference ($P = .001$). No statistically significant difference ($P = .18$) was found between patients and control subjects regarding discharge disposition (Table 3).

Discussion

EDH enlargement was found on follow-up CT scans in nearly one fourth (23%) of patients in our series with conservatively managed EDH (Figs 2 and 3). EDH enlargement occurred early, detected on average within 8 hours of injury and within 5 hours of initial diagnosis. A higher RTS was predictive of rehemorrhage, but no imaging features were found to correlate significantly with EDH enlargement. Patients with EDH rehemorrhage reported a worsening of their clinical condition more frequently and underwent subsequent surgical evacuation twice as often as those with stable EDH, but they did not experience a worse neurologic outcome, as measured by disposition at discharge.

To our knowledge, this is the largest series in which the frequency of enlargement of nonoperative EDHs was examined. Previous series have reported frequencies from 5.5% to 65% (1, 4–7, 12). Hamilton and Wallace (1) reported one of 18 conservatively managed patients with an EDH that enlarged from 1.0 to 2.5 cm after 48 hours, but the

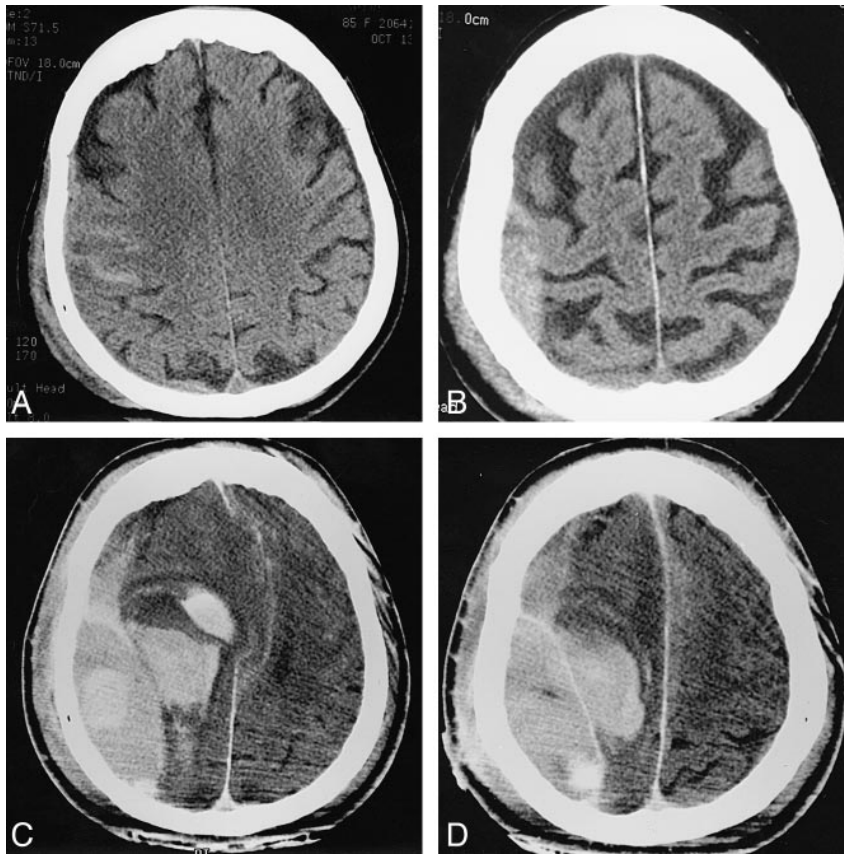


FIG 3. Unenhanced CT scans of an 87-year-old woman struck by a car (initial CT scan 2 hours after injury).

A and B (at a level 15 mm higher than A), Scans show a 12-mm-wide high-right-convexity EDH with subarachnoid hemorrhage in the right parietal lobe inferiorly. The patient had a neurologic deficit, but surgery was not performed because of the patient's religious preferences. A further decline in neurologic status prompted a follow-up scan 9 hours later.

C and D (at a level 10 mm higher than C), Scans show an increase in width of the high-right-convexity EDH to 18 mm, with ipsilateral parenchymal hemorrhage and severe right to left midline shift. The patient did not survive the injury.

true frequency of enlargement in their series is higher, since they reported but did not enumerate other EDHs that increased by 3 mm or less. The highest incidence was reported by Sakai et al (6) (in what is also the largest series to date), who found 24 of 37 conservatively managed patients with EDH enlargement, all within 5 hours. While the incidence is higher than that reported here, the time frame is similar to ours (the mean time to EDH enlargement after injury was 8 hours).

We found, as expected, that the majority of EDHs are associated with underlying fractures, including all five cases of delayed EDH. The presence of a fracture, however, did not correlate with a greater tendency to rehemorrhage. A contralateral subdural hematoma located at the countercoup site is frequently found with EDH and may tamponade an EDH at the coup site (13). We found no lesser tendency for EDH enlargement in the presence of a contralateral subdural hematoma. Abnormal coagulation factors do not seem to play a role in rehemorrhage, with similar numbers in both groups. Sakai et al also reported no increased occurrence of bleeding diathesis in their 24 patients with an enlarging EDH (6). Clinical deterioration in our patient group corresponded in general to the degree of enlargement. This may not be entirely attributable to mass effect, since associated parenchymal shear injury is most likely a contributing factor.

Our data controverts previous assertions that EDH attains maximum size within minutes of for-

mation (4, 14–16). In most cases, arterial thrombosis at the injury site as well as the tamponade effect by the clot and adjacent brain prevent continued EDH enlargement (17). EDH enlargement in the acute setting may represent continued hemorrhage or rehemorrhage from an arterial or venous origin. Some authors have suggested that venous hemorrhage does not generate enough pressure to overcome the tamponade effects of the clot itself and the adjacent brain (18). In the subacute phase, clot expansion has been described to be coincident with a decrease in density after day 5, associated with formation of membranes with permeable sinusoids (5), and the patients in this series all had persistent or worsening symptoms. The mean time to diagnosis in these patients was 2.9 days. We did not find this expansile phase of EDH in our series, probably because of the prompt surgical evacuation of all collections in patients with persistent or worsening neurologic impairment or enlarging EDH. Rather, all EDHs reached maximal size by 36 hours, with most by 8 hours after injury. Nor did we find evidence in the patient or control groups of EDHs decreasing in size by decompressing into fractures, a mechanism that has been suggested by others (17, 19). Nonoperatively managed EDHs presumably undergo resorption, but follow-up in our series was limited and incomplete; patients with head injuries who were doing well with no clinical deficits generally did not have late follow-up scans at our institution. Early detection (namely,

within 6 hours of injury) is crucial to improving outcome (12), but the longer an EDH is asymptomatic, the greater is the likelihood that it will remain so (20).

The RTS (8) at presentation correlated significantly with rehemorrhage. We found that patients with a higher RTS, apparently less severely injured, had a statistically greater likelihood of EDH enlargement. A bimodal distribution to the RTS was found in most patients, either with a score of 4 (because of intubation and chemical paralysis) or a score of 12 (because of being physiologically and neurologically normal). This is not unexpected, since any patient with head injury and a lower GCS score or more severe signs of physiological injury (hypotension or tachypnea) would be treated with immediate surgical evacuation. It is possible that blood pressure and ICP were better controlled in patients with an RTS of 4 (chemically paralyzed patients with appropriate mechanical ventilation). Conversely, in awake patients with head injuries and no physiological injury according to trauma score (RTS = 12), agitation may lead to blood pressure elevation and hyperventilation with a lowering of the ICP, both of which may promote bleeding into an existing EDH. However, in the series of Sakai et al (6), five patients with EDH enlargement were monitored for ICP: two had ICP increases and three were unchanged. We lacked the data to examine ICP values in our series.

Our initial analysis included delayed EDH in patients and control subjects. An argument can be made that delayed EDH represents enlargement of an EDH from invisible to visible (assuming high-quality CT scans at diagnosis and follow-up) and should, therefore, be considered an enlarging lesion. A counter argument is that patients without EDH on initial CT scans are treated differently from those with EDH, and thus these groups should not be lumped together. One solution to this dilemma is to remove all patients with delayed EDH (in both the patient and the control group) from the analysis. When we did this, our results remained essentially unchanged. Another approach is to consider the appearance of delayed EDH as an enlarging lesion and include these patients with cases of rehemorrhage. This analysis changed the RTS to a borderline insignificant predictor, increasing the *P* value from .02 to .07. This lack of stability most likely reflects our small sample size, although other explanations, such as misclassification, are possible as well. Other variables in the logistic regression analysis remained insignificant on both repeat analyses.

Nonoperative management has been advocated for EDHs that are less than 1.5 cm in width, associated with minimal or no midline shift, and located in the convexities (1, 19, 20). The majority of EDHs occur in the temporal region (21) and, when large, cause the most pronounced symptoms associated with temporal lobe herniation and brain stem mass effect. EDHs in the posterior fossa are

usually venous in origin but are generally less favorable lesions for nonoperative management because of the small volume of the posterior fossa (22). Our cohort of nonoperatively managed patients with EDH generally conformed to these criteria, with a mean EDH width of 9 to 10 mm, with 94% being supratentorial.

EDH enlargement, while common in our series, was not found to cause any difference in immediate clinical outcome, as measured by discharge disposition. This is most likely attributable in great part to close clinical monitoring and prompt surgical evacuation of clinically significant EDH enlargement, as evidenced by the 43% rate of subsequent surgical treatment of enlarging EDHs. We acknowledge that our measure of outcome is approximate, and perhaps its insensitivity accounts for the lack of difference between patients and control subjects. However, this was the only variable available in the database. Those who caution against nonoperative management of EDHs cite the safety of EDH surgery, the cost of hospitalization and monitoring, and the devastating effects of late swelling and herniation (2, 20, 23). We found a higher rate of clinical deterioration in patients with EDH enlargement, which occurred more frequently in patients with an enlargement of 1 cm or greater. Although mass effect may play a role in clinical decline, it is likely that associated brain injury, such as diffuse shear, may be more common in patients with an enlarging EDH. Prompt surgical evacuation once EDH enlargement or clinical decline was detected no doubt accounts for the observation that outcome was unchanged as compared with patients with stable a EDH managed conservatively.

Conclusion

Our findings suggest that CT monitoring of conservatively managed EDH for rehemorrhage is most appropriately timed in the first 36 hours after injury, with most cases of EDH enlargement occurring by 8 hours after injury. Moreover, intubation and chemical paralysis seem to have protective effects against EDH enlargement, perhaps by the control of head movement, blood pressure, and possibly ICP. Finally, EDH rehemorrhage does not appear to result in worse neurologic status at discharge in conservatively managed patients.

References

1. Hamilton M, Wallace C. **Nonoperative management of acute epidural hematoma diagnosed by CT: the neuroradiologist's role.** *AJNR Am J Neuroradiol* 1992;13:853-859
2. Marshall LF. **Nonoperative management of extradural hematoma (letter).** *Neurosurgery* 1985;16:606
3. Langfitt TW, Gennarelli TA. **Can the outcome from head injury be improved?** *J Neurosurg* 1982;56:19-25
4. Bullock R, Smith RM, van Dellen JR. **Nonoperative management of extradural hematoma.** *Neurosurgery* 1985;16:602-606
5. Pang D, Horton JA, Herron JM, Wilberger JEJ, Vries JK. **Non-surgical management of extradural hematomas in children.** *J Neurosurg* 1983;59:958-971

6. Sakai H, Takagi H, Ohtaka H, Tanabe T, Ohwada T, Yada K. **Serial changes in acute extradural hematoma size and associated changes in level of consciousness and intracranial pressure.** *J Neurosurg* 1988;8:566-570
7. Servadei F, Faccani G, Roccella P, et al. **Asymptomatic extradural haematomas: results of a multicenter study of 158 cases in minor head injury.** *Acta Neurochir (Wien)* 1989;96:39-45
8. Champion HR, Sacco WJ, Copes WS, Gann DS, Gennarelli TA, Flanagan ME. **A revision of the Trauma Score.** *J Trauma* 1989;29:623-629
9. Domenicucci M, Signorini P, Strzelki J, Delfini R. **Delayed post-traumatic epidural hematoma: a review.** *Neurosurg Rev* 1995;18:109-122
10. DiRocco A, Ellis SJ, Landes C. **Delayed epidural hematoma.** *Neuroradiology* 1991;33:253-254
11. Smith HK, Miller JD. **The danger of an ultra-early computed tomographic scan in a patient with an evolving acute epidural hematoma.** *Neurosurgery* 1991;29:258-260
12. Knuckey NW, Gelbard S, Epstein MH. **The management of "asymptomatic" epidural hematomas: a prospective study.** *J Neurosurg* 1989;70:392-396
13. Maurer JJ, Mayfield FH. **Acute bilateral extradural hematomas.** *J Neurosurg* 1965;23:63-66
14. Ford LE, McLaurin RI. **Mechanisms of extradural hematomas.** *J Neurosurg* 1963;20:760-769
15. Lofgren J. **Traumatic intracranial hematomas: pathophysiological aspects on their course and treatment.** *Acta Neurochir Suppl (Wien)* 1986;36:151-154
16. McLaurin RL, Ford LE. **Extradural hematoma: statistical survey of 47 cases.** *J Neurosurg* 1964;21:364-371
17. Gean AD. **Imaging of Head Trauma.** New York: Raven; 1994; 107-124
18. Bender MB, Christoff N. **Non-surgical treatment of subdural hematomas.** *Arch Neurol* 1974;31:73-79
19. Pozzati E, Tognetti F. **Spontaneous healing of acute extradural hematomas: study of twenty-two cases.** *Neurosurgery* 1986;18:696-700
20. Sagher O, Ribas GC, Jane JA. **In discussion of: Hamilton M, Wallace C. Nonoperative management of acute epidural hematoma diagnosed by CT: the neuroradiologist's role.** *AJNR Am J Neuroradiol* 1992;13:853-862
21. Zimmerman RA, Bilaniuk LT, Gennarelli T, Bruce D, Dolinskas C, Uzzell B. **Cranial computed tomography in diagnosis and management of acute head trauma.** *AJR Am J Roentgenol* 1978;131:27-34
22. Kawakami Y, Tamiya T, Tanimoto T, et al. **Nonsurgical treatment of posterior fossa epidural hematoma.** *Pediatr Neurol* 1990;6:112-118
23. Cooper PR. **Nonsurgical extradural hematomas (letter).** *Neurosurgery* 1986;18:-700