



Providing Choice & Value
Generic CT and MRI Contrast Agents

**FRESENIUS
KABI**

CONTACT REP

AJNR

Direct coronal CT of the spine in infants and children.

M C Kaiser, H Pettersson, D C Harwood-Nash, C R Fitz and E Armstrong

AJNR Am J Neuroradiol 1981, 2 (5) 465-466
<http://www.ajnr.org/content/2/5/465.citation>

This information is current as
of July 22, 2025.

Direct Coronal CT of the Spine in Infants and Children

M. C. Kaiser,^{1,2} H. Pettersson,¹
D. C. Harwood-Nash,¹ C. R. Fitz,¹ and
E. Armstrong¹

Kaiser and Veiga-Pires [1, 2] introduced a direct coronal mode in whole body computed tomography (CT) scanning whereby they sat the patient upright within the gantry hole. We have had further experience with this mode in CT of the spine in infants and children. As general anesthesia is required for CT metrizamide myelography in these patients [3], the sitting position is not compatible with intubation. We introduce the patient in a lateral decubitus position into the gantry orifice and perform direct coronal CT of the spine and posterior abdominal structures. We have used this technique with children up to 4 years of age.

Technique

After obtaining transaxial views, we put the patient into a lateral decubitus position across the examination table, the long axis of the body being parallel to the plane of the gantry (fig. 1). The legs are in flexion to the pelvis, the gonads remaining if possible outside the irradiation field. A slight anterior bending of the upper spine with minimal flexion of the neck keeps the head outside the circle of reconstruction. The head may either rest upon foam supports, or be held by the radiologist to control its position during table movements. The first scan is obtained, using the light localizer, through the area of the spine under investigation. We use a 10 mm slice thickness and a 9.6 sec scanning time with a General Electric 8800 scanner. The largest circle of reconstruction (42 cm) must be used. Subsequent to the localization on the first cut, more scans may be obtained by inward or outward movements of the table using 5 mm steps. The procedure is rapid as at most four slices are sufficient. A special General Electric "review" program to enhance the contrast and to increase spatial resolution was used.

Representative Case Reports

Case 1

A 3-year-old boy with spinal dysraphism underwent CT metrizamide myelography to exclude other congenital abnormalities. Direct

coronal imaging clearly demonstrates the segmentation defects with hemivertebrae at the thoracolumbar junction and a widened lumbar and sacral canal (fig. 2). As the sacral region had not been investigated by axial CT scanning, this represented additional information.

Case 2

A 9-month-old girl with obvious weakness of the lower limbs, mainly on the left, underwent CT metrizamide myelography. Direct coronal imaging delineates a complete block to metrizamide at the lower end of L3 (fig. 3A). The distal dysraphic lumbar canal is widened. The attenuation of the mass measures -100 Hounsfield units (H). The lower limit of the mass is localized at S1. The use of review reconstruction improved the detail of hard bone and enhanced the contrast so that the cord with emerging nerve roots was well outlined (fig. 3B). The cord is shown to be displaced by and intimately involved with the lipomatous mass at the level of the block.

Discussion

Detail is sharper on direct coronal images than on coronal reconstructions. The technique may obviate additional axial

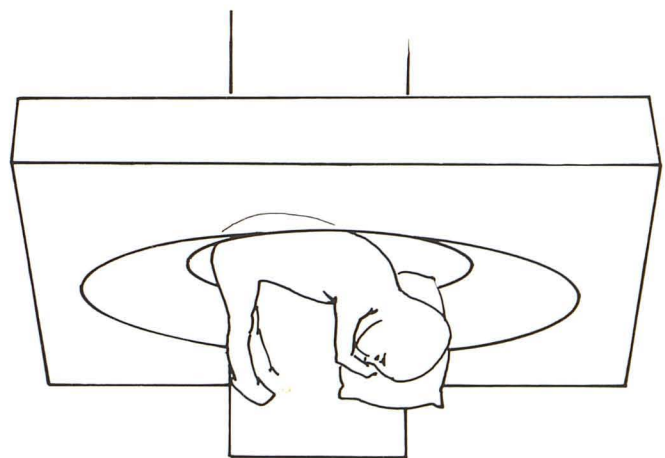


Fig. 1.—Position of patient inside gantry for direct coronal scanning.

Received February 10 1981; accepted after revision May 7, 1981.

¹ Department of Radiology, Hospital for Sick Children, Toronto, Canada.

² Present address: X-Ray Department, Centre Hospitalier Luxembourg, 4, Rue Barblé, Grand-Duchy of Luxembourg, Europe. Address reprint requests to M. C. Kaiser.

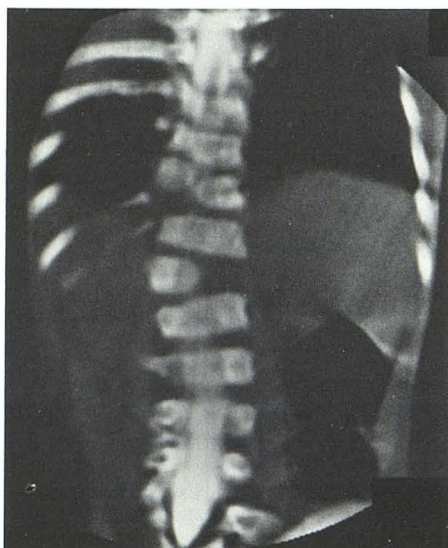
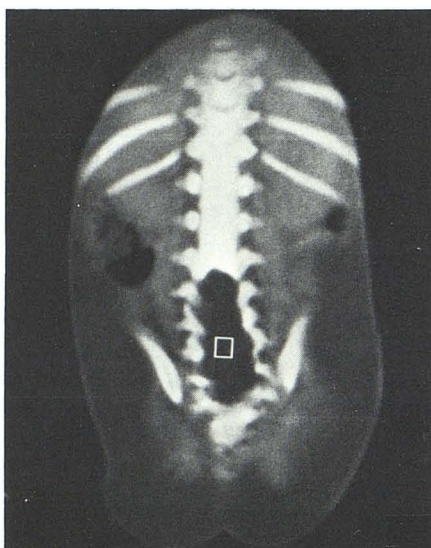
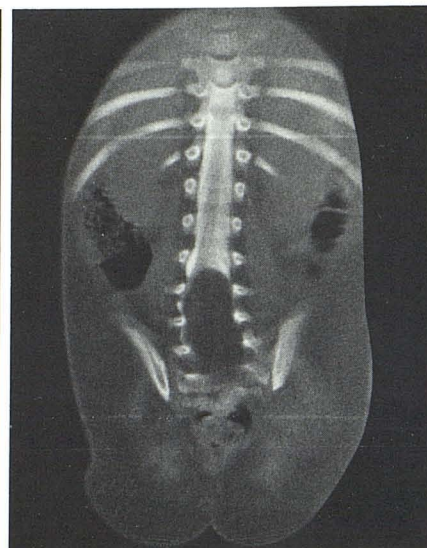

Fig. 2.—Case 1. Coronal image. Dysraphic spine with hemivertebrae and scoliosis. Metrizamide outlines widened lumbar neural canal and short segment of the low thoracic cord.



A



B

Fig. 3.—Case 2. A, Coronal image. Lipomatous mass in widened lumbar and upper sacral canal. Attenuation of mass is -100 H. B, "Review" image outlines long segment of cord with emerging nerve roots. At level of block, distal cord and nerve roots are displaced by and intimately involved with lipomatous mass.

cuts required for coronal reconstruction modes, thus reducing radiation exposure. Anatomic details demonstrated along this plane are very similar to those encountered by the neurosurgeon during the operative approach. Accurate demonstration of extension and relation of lesions to neighboring structures may facilitate surgical or radiation treatment.

On most scanners the largest gantry aperture is 42 cm. As a consequence, decubitus positioning is only applicable to children up to 4 years of age. The sitting position is much less restricted by the patient's stature; it has been shown to be applicable to normal-sized adult patients [2], but it is

difficult to use with infants and small children because of general anesthesia or sedation.

REFERENCES

1. Kaiser MC, Veiga-Pires JA. Sitting position variation of direct longitudino-axial (semi-coronal) mode in CTT-scanning. *ROEFO* 1981;131:97-99
2. Kaiser MC, Veiga-Pires JA. Evaluation de nouvelles techniques en tomodesitométrie. *Ann Radiol (Paris)* 1980;23:559-563
3. Resjo M, Harwood-Nash DCF, Fitz CR, Chuang S. Normal cords in infants and children examined with computed tomographic metrizamide myelography. *Radiology* 1979;130:691-696