



**Providing Choice & Value**

Generic CT and MRI Contrast Agents



CONTACT REP

**AJNR**

**MR of the eye with retrobulbar anesthesia.**

N Hosten, N Bornfeld, A J Lemke, B Sander, R Wassmuth  
and R Felix

*AJNR Am J Neuroradiol* 1997, 18 (9) 1788-1790

<http://www.ajnr.org/content/18/9/1788>

This information is current as  
of July 21, 2025.

# MR of the Eye with Retrobulbar Anesthesia

Norbert Hosten, Norbert Bornfeld, Arne-Jörn Lemke, Bernhard Sander, Ralf Waßmuth, and Roland Felix

**Summary:** MR imaging with retrobulbar anesthesia was performed in eight patients with uveal melanoma. Injection of 2 mL prilocain hydrochloride in 2% epinephrin into the eye muscle cone resulted in improved image quality in seven patients, without side effects. Ocular MR imaging can be indicated to clarify indeterminate sonographic findings in cases of extrascleral growth or to exclude optic nerve invasion in patients with tumors located at the posterior pole of the globe.

**Index terms:** Anesthesia; Eyes, magnetic resonance; Magnetic resonance, technique

Because of the long acquisition times associated with spin-echo sequences, magnetic resonance (MR) images of the orbit can be degraded by motion artifacts. Retrobulbar anesthesia was used in this preliminary study to suppress motion artifacts in nondiagnostic MR studies of the eye (1).

## Materials and Methods

Between September 1994 and February 1996, 140 patients with uveal melanoma were studied with MR imaging. Examinations were performed on a 1.5-T imager, using a 6-cm surface coil. Axial T2-weighted and plain and enhanced T1-weighted images were acquired. Eight patients in whom standard MR imaging was nondiagnostic owing to artifacts caused by eye motion were reexamined after retrobulbar anesthesia. Ophthalmologists prefer this technique to intravenous and oral administration of sedatives because it selectively suppresses eye movements without compromising patient cooperation. Using a blunt 1-gauge needle, the referring ophthalmologist injected 5 mL prilocain hydrochloride in 2% epinephrin into the retrobulbar muscle cone. Because cooperation of the patient is needed, the procedure could not be performed in children.

To evaluate the image quality obtained with and without anesthesia, we measured signal-to-noise and contrast-to-noise ratios (2). Retrobulbar anesthesia resulted in a clear improvement in image quality in six of eight patients,

afforded a slight improvement in one patient, and had no appreciable effect in one patient. The patients did not report any discomfort during or after the examination. Signal-to-noise and contrast-to-noise ratios increased in all patients. The maximal increase observed was fourfold for signal-to-noise and sixfold for contrast-to-noise.

## Discussion

Motion artifacts in ocular MR imaging can be due to spatial misregistration caused by movements of the head or of the globe itself. Movements of the lids cause spatial misregistration of the subcutaneous fat and result in artifacts in the direction of the frequency-encoding gradient. When performing MR examinations of the eye, we routinely instruct patients not to move their head at all, to close their eyes during data acquisition, and to open and close their eyes a few times during image reconstruction, a maneuver that helps patients relax. Despite these measures, MR examinations of the eye may still be nondiagnostic, which was the situation in 5.7% of the patients in our study.

MR imaging in these patients was indicated for two reasons: first, to detect or exclude extrascleral growth in cases in which sonographic findings seemed unreliable to the referring ophthalmologist (Fig 1), and, second, to evaluate the optic nerve with regard to tumor infiltration in choroidal melanomas located at the posterior pole. Additionally, high-quality ocular MR imaging is a prerequisite in the planning of proton-beam radiation therapy.

Retrobulbar anesthesia is widely used to facilitate a variety of ophthalmologic procedures, including eye surgery. Retrobulbar injection is also needed for the administration of drugs, steroids in particular (3). Two techniques are avail-

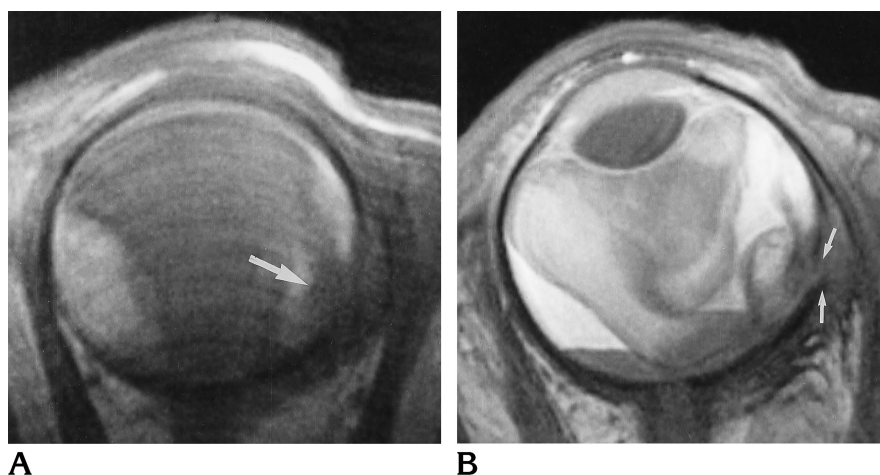
Received July 31, 1996; accepted after revision November 19.

Supported by grant 70-01847-Ho 1, Deutsche Krebshilfe.

From the Department of Radiology, Virchow Klinikum, Humboldt University (N.H., A.-J.L., B.S., R.W., R.F.) and the Department of Ophthalmology, Benjamin Franklin Hospital, Freie Universität (N.B.), Berlin, Germany.

Address reprint requests to Priv.-Doz Dr med Norbert Hosten, Strahlenklinik und Poliklinik, Virchow-Klinikum der Humboldt Universität zu Berlin, Augustenburger Platz 1, 13353 Berlin, Germany.

AJNR 18:1788-1790, Oct 1997 0195-6108/97/1809-1788 © American Society of Neuroradiology



**A** side by a hypointense mass. The hypointensity corresponding to the sclera and chemical shift is disrupted (arrows) by a contrast-enhancing mass (not shown). The MR diagnosis of extrascleral growth was confirmed at surgery.

**B**

Fig 1. MR images without (A) and with (B) retrobulbar anesthesia in a 62-year-old patient with visual loss of the left eye. The fundus was invisible because of a dense intraocular hemorrhage; sonography was indeterminate with respect to extraocular growth.

A, Plain T1-weighted image in the axial plane shows retinal detachment with hyperintense subretinal material. A hypointense mass was suspected temporally (arrow), but no definite diagnosis was possible.

B, Repeat MR examination after retrobulbar anesthesia clearly shows vitreous hemorrhage and retinal detachment with layered subretinal hemorrhage. The lateral rectus muscle is displaced to the temporal

able for the administration of anesthetic agents into the orbit: retrobulbar and periorbital anesthesia (4). The two maneuvers differ in terms of the site at which the anesthetic is deposited. In retrobulbar anesthesia, the anesthetic is injected into the muscle cone. Periorbital injection is achieved via the lids into the superior or inferior orbital tissues just outside the muscle cone (1). Complete akinesia is usually better achieved by retrobulbar anesthesia. In periorbital injection, akinesia may be incomplete with remaining partial activity of the superior oblique muscle (1, 4). Usually, no significant difference in patient comfort or in the degree of anesthetic effect is noted between these techniques. Chemosis, however, is observed somewhat more often after retrobulbar anesthesia (4). In practice, the choice between retrobulbar and periorbital anesthesia is left to the experience of the referring ophthalmologist.

Retrobulbar anesthesia is a relatively safe procedure, and severe complications are rare. The frequency of complications arising from retrobulbar anesthesia varies from series to series. The main complications are retrobulbar hemorrhage with possible occlusion of the central retinal artery, perforation of the globe with intraocular injection of anesthetic drugs, intraocular hemorrhage and subsequent retinal detachment, and inadvertent injection into ophthalmic vessels. Perforation of the globe is a serious complication, which may eventually end in blindness due to retinal detachment. In terms of the possibility of tumor spread, note that the applicators for brachytherapy for ocular melanoma are placed with retrobulbar anesthe-

sia, and, with this practice, there has been no evidence of increased frequency of metastases or local recurrence. Myopia with increased axial length is a major risk factor for perforation (5). Retrobulbar hemorrhage is identified by acute proptosis with or without chemosis and subconjunctival or lid hematoma (1). If this occurs, immediate canthotomy should be performed, and observation of the central retinal artery is essential, since the hemorrhage may lead to central retinal artery occlusion. Direct damage of the optic nerve occurs nearly exclusively when long needles are used. Injection into an ophthalmic vessel may result in systemic effects, including arterial hypotension, respiratory arrests, various cardiovascular reactions, and seizures. Retrobulbar hemorrhage has been observed in 1% of applications (1). Scleral perforation may occur in 0.075% (1) to 0.1% (6) of cases. Adverse systemic reactions (cardiovascular or pulmonary problems) have been described in 0.9% of cases (1).

From a technical standpoint, fat saturation may also help improve the quality of ocular MR images by suppressing the high signal from subcutaneous fat, thus preventing lid ghosts but not eye movements. Echo-planar imaging is not well suited for eye studies, as susceptibility artifacts occur at air-fat interfaces. Fast spin-echo imaging depicts melanoma and the vitreous with good contrast, but imaging times are too long to prevent artifacts from eye movements.

In our series, ocular MR imaging was nondiagnostic in one patient, despite successful retrobulbar anesthesia, because of movements of

the head. Uncooperative patients should not be subjected to retrobulbar anesthesia. The relatively large volume of anesthetic given (5 mL) may confound imaging findings, and we therefore reviewed our T1- and T2-weighted images with regard to this problem. In none of our studies was the local anesthetic separable from the signal of retrobulbar fat. Thus, it seems unlikely that local anesthetic would be mistaken for extrascleral tumor growth.

In summary, we found retrobulbar anesthesia to be a valuable tool in cases of equivocal MR examinations of the eye. Diagnostic images will be obtained in a majority of patients who are unable to suppress movements of the globe and/or lids. Retrobulbar anesthesia has to be performed by an experienced ophthalmologist who knows the possible complications of the procedure. Because of the increased risk of

scleral perforation, high myopia should be regarded as a relative contraindication to retrobulbar anesthesia.

## References

1. Feibel RM. Current concepts in retrobulbar anesthesia. *Surv Ophthalmol* 1985;30:102-110
2. Kaufman L, Kramer DM, Crooks LE, Ortendahl DA. Measuring signal-to-noise ratios in MR imaging. *Radiology* 1989;173:265-267
3. Schechter RJ. Management of inadvertent intraocular injections. *Ann Ophthalmol* 1985;17:771-775
4. Weiss JL, Deichman CB. A comparison of retrobulbar and periorbital anesthesia for cataract surgery. *Arch Ophthalmol* 1989;107:96-98
5. Hay A, Flynn HW, Hoffman JI, Rivera AH. Needle perforation of the globe during retrobulbar and peribulbar injections. *Ophthalmology* 1991;98:1017-1024
6. Boniuk V, Nockowitz R. Perforation of the globe during retrobulbar injection: medicolegal aspects in four cases. *Surv Ophthalmol* 1994;39:141-145