



Providing Choice & Value

Generic CT and MRI Contrast Agents



**FRESENIUS
KABI**

CONTACT REP

AJNR

Sarcoid involvement of the supraorbital nerve: MR and histologic findings.

D R Salvage, J A Spencer, A G Batchelor and K A MacLennan

AJNR Am J Neuroradiol 1997, 18 (9) 1785-1787

<http://www.ajnr.org/content/18/9/1785>

This information is current as
of July 31, 2025.

Sarcoid Involvement of the Supraorbital Nerve: MR and Histologic Findings

D. R. Salvage, J. A. Spencer, A. G. Batchelor, and K. A. MacLennan

Summary: We report the MR and histologic findings of neurosarcoidosis presenting as a mass involving the supraorbital nerve in a 29-year-old woman in whom this was the first manifestation of the disease. The features and associations of neurosarcoidosis and the response to treatment are discussed.

Index terms: Nerves, neoplasms; Sarcoidosis

Involvement of the nervous system in sarcoidosis is uncommon, and as a presenting feature of sarcoidosis is unusual (1–6). Although cranial nerve involvement is common in neurosarcoidosis, the trigeminal nerve is rarely involved, especially without abnormalities of other cranial nerves (1–3, 5, 7). Basal granulomatous meningitis is the usual cause of cranial nerve symptoms, and when affecting the trigeminal nerve, causes sensory symptoms (5, 7).

We describe a patient with biopsy-proved neurosarcoidosis who had a mass involving the peripheral portion of the supraorbital nerve, without previously diagnosed sarcoidosis.

Case Report

A 29-year-old woman had a 2-month history of a rapidly developing swelling above the right eye. She reported no constitutional symptoms and had no history of skin rashes. Her only other symptom was of recent deterioration of vision in the left eye. She had had poor vision in the left eye and intermittent diplopia since partial correction in childhood of a congenital internal strabismus.

On examination, a 4 × 1-cm subcutaneous swelling was present between the hairline and the eyebrow on the right that ran in the course of the right supraorbital nerve, which lies deep to the frontalis muscle initially. The medial division pierces the muscle and the lateral division the galea aponeurotica to supply sensation to the anterior scalp. The swelling was tender on firm palpation, which produced radiating pain in the right side of the face and into the right scalp. The skin overlying the swelling was

stretched but there was no local skin rash. With the rapid enlargement of the mass, the clinical diagnosis was a soft-tissue tumor involving the right supraorbital nerve. Magnetic resonance (MR) imaging revealed a tubular mass extending superiorly from the right supraorbital ridge. On the anterior aspect there were spicular extensions into the subcutaneous fat. The lesion was of intermediate intensity on an unenhanced T1-weighted sequence, and enhanced homogeneously after intravenous injection of contrast material (Fig 1A–C). In addition, numerous periventricular and deep white matter high signal foci were seen on a T2-weighted axial sequence (not shown).

A biopsy of the affected supraorbital nerve was performed, and an irregular portion of rubbery, tan-colored tissue 3.2 × 2 × 1 cm was excised from deep to the frontalis with extension along branches of the nerve through the muscle into the subcutaneous fat. Granulomatous inflammation surrounded the right supraorbital nerve, with associated perineurial fibrosis (Fig 1D). Special stains for fungi and acid fast bacilli were negative. The histologic appearance was regarded as entirely consistent with sarcoid.

Subsequently, computed tomography of the chest and upper abdomen revealed discrete lymph nodes, 10 to 15 mm in size, at both lung hila and in the superior mediastinum. There were no lung nodules.

After high-dose corticosteroid therapy, the right supraorbital mass disappeared completely, and no residual abnormality was evident at this site at a follow-up MR examination. The white matter abnormalities were unchanged. One year after initial presentation the patient was in good health, and no other features of sarcoidosis have developed.

Discussion

Clinical features of neurosarcoidosis occur in 5% of the cases of sarcoidosis (1–6) and are the presenting signs of the disease in approximately half those with neurosarcoidosis (2, 3, 5, 6). Autopsy evidence suggests that nervous system involvement in sarcoidosis occurs in up to

Received April 1, 1996; accepted after revision November 27.

From the Departments of Radiology (D.R.S., J.A.S.), Plastic Surgery (A.G.B.), and Pathology (K.A.M.), St James's University Hospital, Leeds, England. Address reprint requests to Dr D. R. Salvage, Department of Radiology, Hull Royal Infirmary, Anlaby Rd, Hull, England, HU3 2JZ.

AJNR 18:1785–1787, Oct 1997 0195-6108/97/1809–1785 © American Society of Neuroradiology

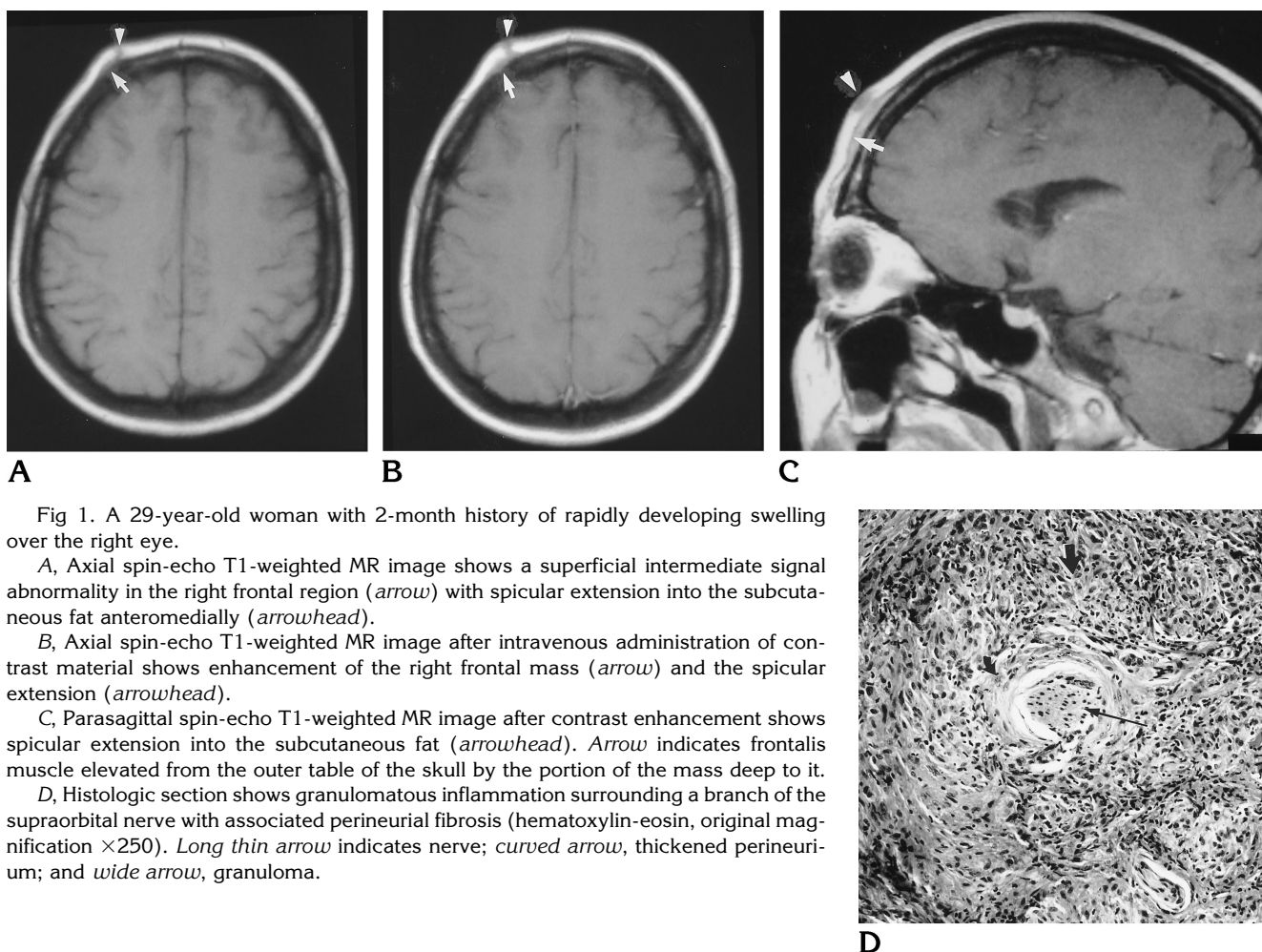


Fig 1. A 29-year-old woman with 2-month history of rapidly developing swelling over the right eye.

A, Axial spin-echo T1-weighted MR image shows a superficial intermediate signal abnormality in the right frontal region (arrow) with spicular extension into the subcutaneous fat anteromedially (arrowhead).

B, Axial spin-echo T1-weighted MR image after intravenous administration of contrast material shows enhancement of the right frontal mass (arrow) and the spicular extension (arrowhead).

C, Parasagittal spin-echo T1-weighted MR image after contrast enhancement shows spicular extension into the subcutaneous fat (arrowhead). Arrow indicates frontalis muscle elevated from the outer table of the skull by the portion of the mass deep to it.

D, Histologic section shows granulomatous inflammation surrounding a branch of the supraorbital nerve with associated perineurial fibrosis (hematoxylin-eosin, original magnification $\times 250$). Long thin arrow indicates nerve; curved arrow, thickened perineurium; and wide arrow, granuloma.

16% of cases (1, 4). Cranial nerve involvement is common in neurosarcoidosis, often affecting several cranial nerves, the facial nerve most frequently (1–3, 5, 7). The trigeminal nerve is one of the cranial nerves less commonly affected, and its involvement is usually intracranial, resulting from basal granulomatous leptomeningitis (7). The symptoms usually experienced in such involvement are unilateral and sensory, often with other cranial nerves affected as well (5, 7). To our knowledge, peripheral involvement of the trigeminal nerve by a sarcoid granulomatous mass has not been described.

Mass lesions in neurosarcoidosis are unusual, and are normally intracranial (2, 3). Peripheral nerve involvement occurs in 15% of the patients with neurosarcoidosis (3, 5, 7) and is usually sensorimotor with a typical “glove and stocking” distribution, rather than a mass involving the nerves (2, 6).

The MR features of neurosarcoidosis in the

central nervous system have been well described (1, 4, 8). Periventricular white matter lesions are common (1, 2, 4, 9), as is enhancement of the leptomeninges (2, 4). The latter was not seen in our patient. Enhancing mass lesions are uncommon in neurosarcoidosis, and to our knowledge have only been described at intracranial sites (2, 3).

Proof of neurosarcoidosis is usually difficult to obtain by biopsy of the affected nervous tissue, owing to the sites involved and the neurologic deficits likely to result after biopsy (5, 6, 8, 9). Diagnosis therefore usually depends on histologic proof that the sarcoidosis has affected other systems and on the lack of another explanation for the nervous system signs and symptoms (1, 2, 5, 6, 8, 9). The response of neurologic signs and symptoms to steroid therapy is often used as further circumstantial evidence of the diagnosis (1). In our patient, a biopsy sample was obtained easily and proved the diagno-

sis before evidence of involvement of other systems was manifested.

There were other more typical features of neurosarcoidosis and sarcoidosis in this patient. The periventricular white matter lesions producing a high signal on T2-weighted MR images are common in neurosarcoidosis (1, 2, 4, 9), though not specific. Multisystem involvement by sarcoidosis in association with neurosarcoidosis is the usual pattern of disease, with isolated neurosarcoidosis occurring rarely (5, 6, 8). The demonstration of hilar and mediastinal lymph node involvement was another strong indicator of the diagnosis (5). An association between cutaneous sarcoid, such as lupus pernio, and neurosarcoid is not known, and in this patient there was no involvement of the skin, only the subcutaneous tissues.

The differential response to steroid therapy of the nervous system manifestations of sarcoidosis was also typical, with resolution of the mass disease involving the trigeminal nerve and little change in the periventricular white matter lesions. Cranial and peripheral nerve involvement with neurosarcoidosis generally has a good prognosis with steroid therapy (3, 7). Other manifestations of neurosarcoidosis that respond well to steroid therapy are mass lesions (5, 6) and granulomatous leptomeningitis (4). Lesions in the periventricular white matter, seen as high signal on T2-weighted MR images, however, usually have little or no response (4), although a few cases of improvement have been described (4, 8).

Our case demonstrates, yet again, how protean the manifestations and presentations of

sarcoidosis are. Involvement of the nerve resulted in a homogeneously enhanced mass on contrast-enhanced T1-weighted MR images with spicular involvement of the surrounding fat. The differential response of features of neurosarcoidosis to steroid therapy has been previously documented, with resolution of the mass lesion and cranial nerve involvement but no change in the periventricular white matter lesions.

Acknowledgments

We acknowledge the assistance of the Department of Medical Illustration at St James's University Hospital for providing the figures, and Karen Higgins for typing the manuscript.

References

1. Zouaoui A, Maillard JC, Dormont D, Chiras J, Marsault C. MRI in neurosarcoidosis. *J Neuroradiol* 1992;19:271-284
2. Oksanen V. Neurosarcoidosis. *Sarcoidosis* 1994;11:76-79
3. Scott TF. Neurosarcoidosis: progress and clinical aspects. *Neurology* 1993;43:8-12
4. Lexa FJ, Grossman RI. MR of sarcoidosis in the head and spine: spectrum of manifestations and radiographic response to steroid therapy. *AJNR Am J Neuroradiol* 1994;15:973-982
5. Heck AW, Phillips LH. Sarcoidosis and the nervous system. *Neurol Clin* 1989;7:641-654
6. Stern BJ, Krumholz A, Johns C, Scott P, Nissim J. Sarcoidosis and its neurological manifestations. *Arch Neurol* 1985;42:909-917
7. Delaney P. Neurologic manifestations in sarcoidosis: review of the literature, with a report of 23 cases. *Ann Intern Med* 1977;87:336-345
8. Handler MS, Johnson LM, Dick AR, Batnitzky S. Neurosarcoidosis with unusual MRI findings. *Neuroradiology* 1993;35:146-148
9. Smith AS, Meisler DM, Weinstein MA, et al. High-signal periventricular lesions in patients with sarcoidosis: neurosarcoidosis or multiple sclerosis? *AJR Am J Roentgenol* 1989;153:147-152