



Get Clarity On Generics

Cost-Effective CT & MRI Contrast Agents



FRESENIUS
KABI

WATCH VIDEO

AJNR

Solitary subglottic neurofibroma: MR findings.

H Tanaka, U Patel, J U Coniglio and A Rubio

AJNR Am J Neuroradiol 1997, 18 (9) 1726-1728

<http://www.ajnr.org/content/18/9/1726>

This information is current as
of August 7, 2025.

Solitary Subglottic Neurofibroma: MR Findings

Hisashi Tanaka, Uresh Patel, John U. Coniglio, and Ana Rubio

Summary: We present a case of subglottic neurofibroma, which is of interest because laryngeal neurofibroma rarely occurs in the subglottic space. Nonspecific MR findings did not allow us to exclude the preoperative diagnosis of hemangioma.

Index terms: Neuroma; Larynx, neoplasms

Subglottic neurofibromas are extremely rare. We found five cases reported previously (1–5). We describe a case of subglottic neurofibroma in a 12-year-old girl, with emphasis on the magnetic resonance (MR) imaging features. Before surgery, the tumor had been thought to be a hemangioma.

Case Report

A 12-year-old girl initially presented with acute onset of nocturnal stridor, and was treated for asthma. She had three additional attacks, each severe enough to require epinephrine. Laryngoscopy revealed a large erythematous subglottic submucosal mass, suggesting a hemangioma. MR imaging at 1.5 T confirmed a 12 × 7 mm well-circumscribed mass in the subglottic space. The mass had its root at the anterior wall of the larynx and extended into the airway (Fig 1A–C). It also infiltrated the cricothyroid membrane and extended slightly anterior to this. The mass was isointense with muscle on T1-weighted spin-echo images (500/15/2 [repetition time/echo time/excitations]) (Fig 1A) and homogeneously hyperintense on T2-weighted spin-echo images (3000/102/2) (Fig 1B). No flow void was observed inside or around the mass, and there was no signal void suggesting calcification in the mass. After injection of gadopentetate dimeglumine, the lesion showed marked homogeneous enhancement (Fig 1C). Hemangioma was considered the most likely diagnosis. There was no lymphadenopathy. Physical examination did not show any cutaneous or mucosal stigmata suggesting neurofibromatosis or hemangioma. The patient underwent biopsy and excision by laser. Histopathologic examination revealed a neoplasm composed of spindle cells and myxoid background (Fig 1D). There was no necrosis or mitosis. Immunohistochemical stains revealed positivity for vimentin and S100 only. These results were diagnostic of a

peripheral nerve sheath tumor. Silver impregnation stain revealed axons intermingled with the tumor cells, consistent with a neurofibroma (Fig 1E).

Discussion

Neurofibromas arise from the sheath of nerve fibers and are characterized by prominent collagen production and trapped nerve fibers. They usually grow within the sheath, encompassing the nerve. Because of this growth characteristic, it is frequently difficult to excise a neurofibroma without sacrificing the nerve of origin (5).

Laryngeal neurofibroma is rare. Not more than 60 cases have been reported (6). The presenting symptoms are hoarseness, dyspnea, stridor, dysphagia, and voice change (2, 7). Laryngeal neurofibromas have been described in patients ranging in age from 2 to 60 years (2, 7). Children are often affected, particularly with neurofibromatosis. On the other hand, laryngeal involvement in neurofibromatosis is uncommon and may present with a solitary neurofibroma or a plexiform neurofibroma (4). The latter is pathognomonic for neurofibromatosis. Of 58 cases of laryngeal neurofibromas we reviewed in the literature, 34 (59%) were associated with neurofibromatosis. Among five subglottic neurofibromas, two were associated with neurofibromatosis. There is no obvious sex predilection in laryngeal neurofibromas (2). Supraglottic involvement is the rule (2, 7). The aryepiglottic folds and arytenoids are the most commonly involved regions, as these areas of the larynx are the richest in terminal nerve plexus (8).

MR imaging features in our case are similar to those reported in neurofibromatosis (6, 9). The tumors are well defined and show intermediate signal intensity on T1-weighted images with marked homogeneous enhancement, and ho-

Received August 27, 1996; accepted after revision January 10, 1997.

From the Departments of Radiology (H.T., U.P.), Surgery (J.U.C.), and Pathology (A.R.), University of Rochester (NY) Medical Center.

Address reprint requests to Hisashi Tanaka, MD, Department of Radiology, Osaka University Medical School, 2-2 Yamadaoka, Suita, Osaka 565, Japan.

AJNR 18:1726–1728, Oct 1997 0195-6108/97/1809–1726 © American Society of Neuroradiology

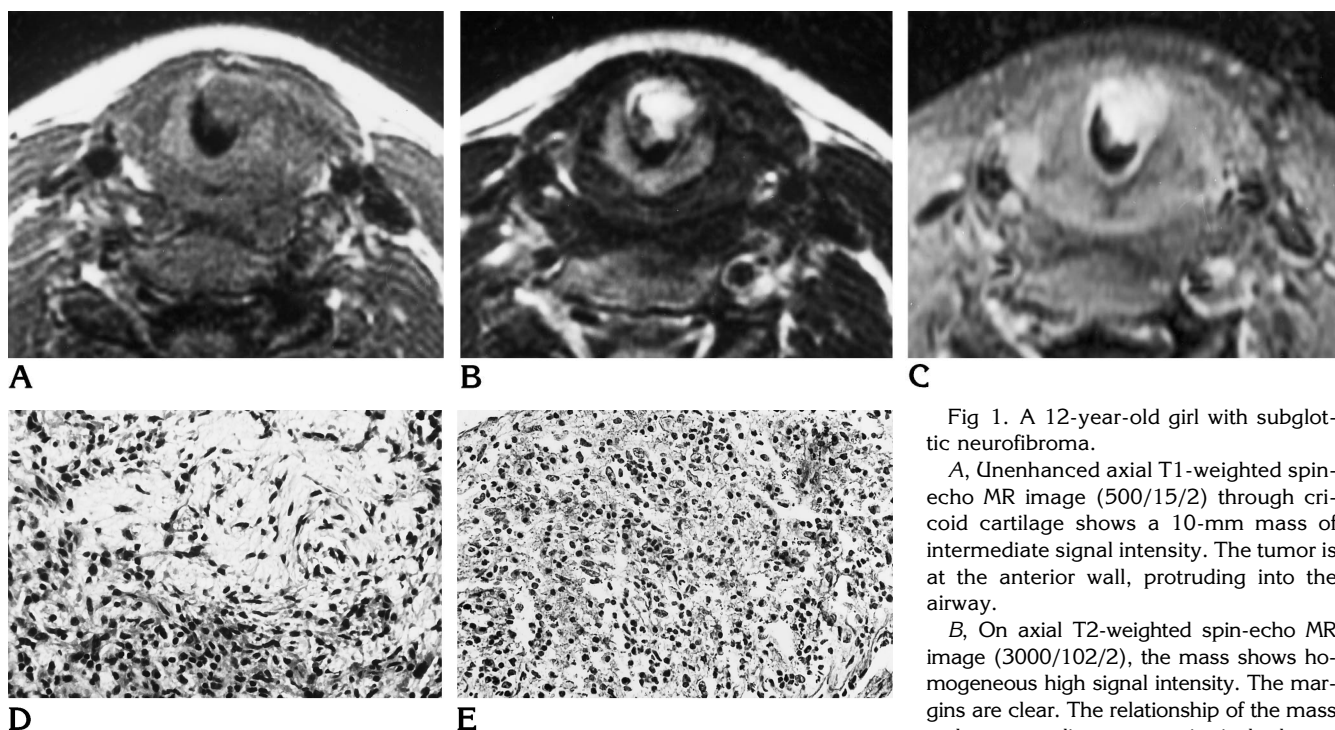


Fig 1. A 12-year-old girl with subglottic neurofibroma.

A, Unenhanced axial T1-weighted spin-echo MR image (500/15/2) through cricoid cartilage shows a 10-mm mass of intermediate signal intensity. The tumor is at the anterior wall, protruding into the airway.

B, On axial T2-weighted spin-echo MR image (3000/102/2), the mass shows homogeneous high signal intensity. The margins are clear. The relationship of the mass to the surrounding structure is nicely shown.

C, Contrast-enhanced axial T1-weighted fat-suppressed MR image (700/11/2) shows the mass is homogeneously enhanced.

D, Light photomicrograph of surgical specimen shows myxoid degeneration with sparsely distributed spindle cells in the upper portion of the field and densely packed cells in the lower portion (hematoxylin-eosin, original magnification $\times 120$).

E, Photomicrograph of the surgical specimen reveals axons randomly distributed among the cellular and fibrous elements of the neoplasm (Bodian silver impregnation method, original magnification $\times 120$).

homogeneous high signal intensity on T2-weighted images.

Subglottic tumors in this age group are relatively rare. They include subglottic hemangioma, neurilemmoma, granular cell tumor, fibrous histiocytoma, inflammatory pseudotumor, benign mixed tumors, mucoepidermoid carcinoma, adenoid cystic carcinoma, non-Hodgkin lymphoma, and rhabdomyosarcoma (10). Among them, subglottic hemangiomas are the most common, and the other tumors are rare.

Subglottic hemangiomas, which usually become symptomatic in the first 6 months of life, are associated with cutaneous hemangioma in 50% of cases (10). At MR imaging, hemangiomas are seen as solid masses with intermediate signal intensity on T1-weighted images, high signal intensity on T2-weighted images, and prominent enhancement on contrast-enhanced T1-weighted images (11, 12). These features are the same as the MR findings in the present case, which hampered the true diagnosis. Sometimes, hemangiomas show more specific features, such as vascular flow signal voids or

fatty change (11, 13). Although rare, neurofibroma should be included in the differential diagnosis of subglottic masses in childhood, and thorough skin examinations should be performed.

References

1. Levine HL, Tubbs R. Nonsquamous neoplasms of the larynx. *Otolaryngol Clin North Am* 1986;19:475-488
2. Stanley RJ, Scheithauer BW, Weiland LH, Neel HB III. Neural and neuroendocrine tumors of the larynx. *Ann Otol Rhinol Laryngol* 1987;96:630-638
3. Fukuda I, Ogasawara H, Kumoi T, Sugihara K, Wada H. Subglottic neurofibroma in a child. *Int J Pediatr Otorhinolaryngol* 1987;14:161-170
4. Stines J, Rodde A, Carolus JM, Perrin C, Becker S. CT findings of laryngeal involvement in von Recklinghausen disease. *J Comput Assist Tomogr* 1987;11:141-143
5. Jones SR, Myers EN, Barnes EL. Benign neoplasms of the larynx. In: Fried MP, ed. *The Larynx: A Multidisciplinary Approach*. Boston, Mass: Little, Brown; 1988:401-420
6. Martin DS, Stith J, Awwad EE, Handler S. MR in neurofibromatosis of the larynx. *AJNR Am J Neuroradiol* 1995;16:503-506
7. Chang-Lo M. Laryngeal involvement in von Recklinghausen's disease: a case report and review of the literature. *Laryngoscope* 1977;87:435-442

8. Helg JR. Neurinomas of the larynx and neurofibromatosis of von Recklinghausen's. *Pract Otorhinolaryngol (Basel)* 1950;12:165-184
9. Yousem DM, Oberholtzer C. Neurofibroma of the aryepiglottic fold. *AJNR Am J Neuroradiol* 1991;12:1176-1178
10. Pransky SM, Richard Kang D. Tumors of the larynx, trachea, and bronchi. In: Bluestone CD, Stool SE, Kenna MA, eds. *Pediatric Otolaryngology*. 3rd ed. Philadelphia, Pa: Saunders; 1996:1405-1409
11. Baker LL, Dillon WP, Hieshima GB, Dowd CF, Frieden IJ. Hemangiomas and vascular malformations of the head and neck: MR characterization. *AJNR Am J Neuroradiol* 1993;14:307-314
12. Meyer JS, Hoffer FA, Barnes PD, Mulliken JB. Biological classification of soft-tissue vascular anomalies: MR correlation. *AJR Am J Roentgenol* 1991;157:559-564
13. Barnes PD, Burrows PE, Hoffer FA, Mulliken JB. Hemangiomas and vascular malformations of the head and neck: MR characterization (letter). *AJNR Am J Neuroradiol* 1994;15:193-194