



This information is current as  
of August 10, 2025.

## **Ectopic extraspinal meningioma: CT and MR appearance.**

L A Christopherson, D A Finelli, J Wyatt-Ashmead and M J Likavec

*AJNR Am J Neuroradiol* 1997, 18 (7) 1335-1337  
<http://www.ajnr.org/content/18/7/1335>

---

# Ectopic Extraspinal Meningioma: CT and MR Appearance

Lucy A. Christopherson, Daniel A. Finelli, Josephine Wyatt-Ashmead, and Matthew J. Likavec

**Summary:** We report a case of an ectopic, extraspinal meningioma that appeared as a midline interscapular mass in a 13-year-old girl. The tumor involved the T-2 and T-3 spinous processes, but was dorsal to the lamina and was entirely extrinsic to the spinal canal. Large amounts of tumoral calcification and reactive hyperostosis were present, radiologically mimicking an osteogenic sarcoma.

**Index terms:** Meninges, neoplasms; Spine, neoplasms

Spinal meningiomas are usually encountered in middle-aged women and typically are associated with signs and symptoms of cord or nerve root compression. The radiologic diagnosis is often suggested by their intradural, extramedullary location or by their association with a nerve root sleeve. Rarely, meningiomas are located outside the spinal canal, and these have been variously termed *extraspinal meningiomas*, *extradural meningiomas*, or *ectopic spinal meningiomas*. A review of the literature revealed two cases in which the meningioma was completely outside the spinal canal (1, 2), but even in these lesions, there was direct attachment to the dura at a nerve root sleeve. We report a case of an extraspinal meningioma involving the posterior bony elements of the upper thoracic spine, with no attachment to the dura or nerve root sleeves, in an otherwise asymptomatic young woman. The unusual radiologic manifestations of this tumor mimicked an osteogenic sarcoma.

## Case Report

A 13-year-old girl had a 3-month history of a painless lump between her shoulder blades. She had been asymptomatic except for some tingling and numbness in the right upper extremity periodically during the 3 weeks preceding presentation. Her medical history was unremarkable.

Physical examination revealed a 4 × 4.5-cm midline interscapular mass at the T2–3 level. The overlying skin was normal. Results of a neurologic examination were normal except for mildly decreased sensation in the right upper extremity. Two café au lait spots were present on examination. Findings on a computed tomographic (CT) scan of the head were normal. Laboratory examination revealed normal hematologic, blood chemistry, and urinalysis profiles. The patient's thoracic spine radiographs, CT scans, and magnetic resonance (MR) images are shown Figure 1. The primary diagnostic considerations based on the imaging findings were that of an osteogenic sarcoma or other bone-forming malignant tumor.

An open biopsy was performed, leaving the spinous processes and muscle borders intact to allow for total resection if the pathologic findings were compatible with an osteogenic sarcoma. The frozen section of the mass was compatible with a spindle cell tumor, probably benign. A T1–5 laminectomy was performed, and the tumor was resected completely via a sublaminar approach. At surgery, a soft, white tumor supplied by large dorsal arteries and veins was dissected along clear planes from the dorsal spine at T-2 (Fig 1G). The tumor grossly extended to the subperiosteum of the dorsal laminae of T-2. After tumor resection, bilateral lateral fusion with bone graft was performed. Microscopically, the tumor was composed predominantly of elongated cells with oval nuclei that contained a fine chromatin pattern and occasional pseudoinclusions (Fig 1H). Focally, the cells were arranged in sheets and whorls and contained heavy deposition of collagen parallel to and between the tumor cells. Psammoma bodies were present. Histologically, fingerlike projections of tumor invaded the T-2 and T-3 spinous processes and the T-2 laminae, and there was reactive hyperostosis of the involved bone. Special stains showed the tumor cells to be markedly positive for glycogen and vimentin, and positive for epithelial membrane antigen. The tumor cells were negative for S-100, carcinoembryonic antigen, neuron-specific enolase, Leu-7, and myoglobin. Results of a chromosomal analysis of the tumor were normal. The patient remained neurologically intact

---

Received June 20, 1996; accepted after revision October 30.

From the Departments of Radiology (L.A.C., D.A.F.), Pathology (J.W.-A.), and Neurosurgery (M.J.L.), MetroHealth Medical Center/Case Western Reserve University School of Medicine, Cleveland, Ohio.

Address reprint requests to Daniel A. Finelli, MD, Department of Radiology, MetroHealth Medical Center, 2500 MetroHealth Dr, Cleveland, OH 44109.

AJNR 18:1335–1337, Aug 1997 0195-6108/97/1807-1335 © American Society of Neuroradiology

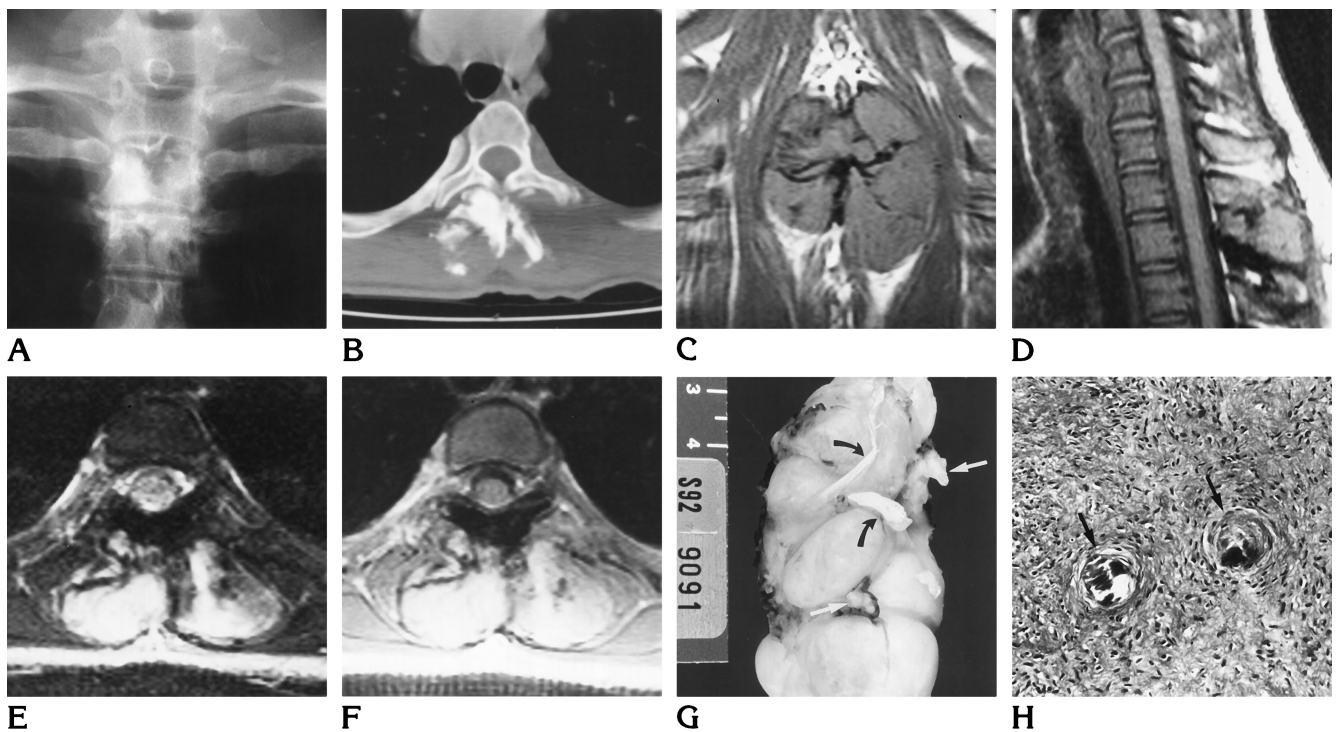


Fig 1. A 13-year-old girl with ectopic extraspinal meningioma.

A, Anteroposterior radiograph of the thoracic spine shows destruction of the T-2 and T-3 spinous processes, with dense adjacent calcification.

B, Unenhanced CT scan of the chest shows an approximately 4-cm-diameter mass extending from the T-2 spinous process into the adjacent paraspinal muscles. The laminae and transverse processes appear intact. The mass contains multiple bulky regions of dense calcification adjacent to the destroyed T-2 and T-3 spinous processes. No spinal canal involvement or intrathoracic abnormality is identified.

Coronal (C) and sagittal (D) unenhanced T1-weighted MR images (500/16/1 [repetition time/echo time/excitations]) show the lobulated mass originating in the region of the T-2 spinous process, splaying the adjacent dorsal paraspinal musculature. The T-2 and T-3 spinous processes are destroyed. Bulky, curved areas of markedly decreased signal are present within the soft-tissue mass and throughout the T-2 lamina on all sequences, compatible with the dense calcifications and a few large tumor vessels.

E, Axial gradient-recalled echo MR image (800/18/2, 20° flip angle) shows the mass to be hyperintense relative to the surrounding muscle, with very low signal in the regions that are calcified on the CT scan.

F, Axial contrast-enhanced T1-weighted MR image (600/16/1) shows intense enhancement of the tumor, with regions of low signal intensity corresponding to the heavily calcified portions of the mass.

G, Photograph of the surgical specimen from an en bloc resection shows a lobulated, soft, white tumor supplied by large dorsal arteries (white arrows) and veins (black arrows). The tumor extends to the subperiosteum of the dorsal laminae of T-2.

H, Microscopically, the tumor is composed of elongated spindle cells with oval nuclei, arranged in sheets and whorls. There is heavy deposition of collagen parallel to and between the tumor cells and multiple psammoma bodies (arrows).

throughout the hospital course, and was doing well with no recurrence on MR images at the 2-year follow-up.

## Discussion

The case presented here differs from two cases of extraspinal extradural meningioma described previously (1, 2) in that no component of the tumor was present within the spinal canal, and no attachment to either dura or nerve root sleeve was found at surgery or at microscopy. The case described by Hallpike and Stanley (1)

was a large, dumbbell-shaped extradural lesion, but it had a moderately large component within the spinal canal, and the patient had symptoms of thoracic cord compression. The case described by Ibrahim et al (2) was a large, completely extradural suboccipital mass, found to arise from the right C-2 nerve root sleeve. Calogero and Moosey (3) reviewed 35 cases of extradural spinal meningioma and suggested that these lesions most commonly arise from arachnoid villi located in the nerve root sleeves,

but since there is little room for expansive growth, they secondarily invade the extradural tissues. They did describe five of these patients, who were 14 years old or younger (one of whom had multiple cutaneous neurofibromata), and suggested that these extradural meningiomas in young patients may have a more aggressive behavior.

The large, lobulated, soft-tissue mass with dense, irregular calcification in this case is quite similar to the findings in a recently published case by Wright et al (4) of a young girl with a high-grade osteogenic sarcoma arising in the neural arch. Though a histologic slide was not included in their article, the histologic description is quite different from the findings in our case. Wright et al (4) framed their discussion in the context of the differential diagnosis of primary benign and malignant bone tumors, and extraspinal meningioma was not a consideration.

The features of our case suggest that the meningioma most likely arose from embryonic meningotheial (arachnoidal) cell rests within the T-2 spinous process, or perhaps in association with a dorsal ramus of a spinal nerve root. Embryonic meningotheial cell rests have been

thought to be the cause of other reported cases of "ectopic" meningiomas (5). Cushing (6) and Hassin (7) both noted that arachnoid cell clusters (meningotheial cells) are common at the spinal nerve root exit zones, and that these are the likely sites of origin in the typical patterns of "extradural" spinal meningioma (1-3). The rapid growth and striking bony and soft-tissue changes seen in our case support the observation by Calogero and Mooney (3) that extradural spinal meningiomas may be more aggressive in young patients.

## References

1. Hallpike JF, Stanley P. A case of extradural spinal meningioma. *J Neurol Neurosurg Psychiatry* 1968;31:195-197
2. Ibrahim AW, Satti MB, Ibrahim EM. Extraspinal meningioma: case report. *J Neurosurg* 1986;64:328-330
3. Calogero JA, Mooney J. Extradural spinal meningiomas, report of four cases. *J Neurosurg* 1972;37:442-447
4. Wright NB, Skinner R, Lee REJ, Craft AW. Osteogenic sarcoma of the neural arch. *Pediatr Radiol* 1995;25:62-63
5. Hoye SJ, Hoar CS Jr, Murray JE. Extracranial meningioma presenting as a tumor of the neck. *Am J Surg* 1960;100:486-489
6. Cushing H. The meningiomas (dural endotheliomas): their source, and favoured seats of origin. *Brain* 1922;45:282-316
7. Hassin GB. Villi (pacchionian bodies) of the spinal arachnoid. *Arch Neurol Psychiatry* 1930;23:65-78