



## Get Clarity On Generics

Cost-Effective CT & MRI Contrast Agents

 FRESENIUS  
KABI

[WATCH VIDEO](#)

# AJNR

## **Embolization of cerebral arteriovenous malformations with silk: histopathologic changes and hemorrhagic complications.**

F Schmutz, W McAuliffe, D M Anderson, J P Elliott, J M Eskridge and H R Winn

This information is current as  
of August 22, 2025.

*AJNR Am J Neuroradiol* 1997, 18 (7) 1233-1237  
<http://www.ajnr.org/content/18/7/1233>

# Embolization of Cerebral Arteriovenous Malformations with Silk: Histopathologic Changes and Hemorrhagic Complications

Friedrich Schmutz, William McAuliffe, David M. Anderson, J. Paul Elliott, Joseph M. Eskridge, and H. Richard Winn

**PURPOSE:** To evaluate the safety of silk as an embolic agent for preoperative embolization of cerebral arteriovenous malformations (AVMs) by assessing the histopathologic changes and hemorrhagic complications associated with its use. **METHODS:** Histopathologic specimens, medical records, and radiologic records of 73 patients with AVMs embolized with silk (alone or in combination with other agents) were reviewed retrospectively. Forty-eight histologic specimens obtained at surgery were analyzed for inflammatory responses and compared with the time interval between embolization and surgery. Postembolization angiograms were assessed for vasculitis and CT scans were reviewed for evidence of hemorrhage after embolization. **RESULTS:** There was no angiographic evidence of vasculitis. Histologic evidence of vasculitis was absent or mild in 92% of cases and histologic evidence of perivascular inflammation was absent or mild in 73% of cases. The frequency of histologic changes associated with vasculitis, perivascular inflammation, and vessel necrosis varied with the time interval between embolization and AVM resection. Intracranial hemorrhage, as a direct complication of silk use, occurred in one patient. Another patient had subarachnoid hemorrhage 24 hours after embolization, caused by rupture of a posteroinferior cerebellar artery aneurysm. Intraventricular high-density material appeared on routine postembolization CT scans in two other patients who had intraventricular AVM extension. This high-density material was thought to be contrast extravasation from intrinsically leaky AVM nidus vessels and not frank hemorrhage. **CONCLUSION:** Embolization of AVMs with silk does not result in marked inflammation or increased hemorrhagic complications as compared with other agents.

**Index terms:** Arteriovenous malformations, embolization; Interventional materials, embolic agents

*AJNR Am J Neuroradiol* 18:1233–1237, August 1997

Although not without complications, endovascular embolization has proved to be an important adjunct to the surgical treatment of intracranial arteriovenous malformations (AVMs) (A. Berenstein, I. S. Choi, M. Kuppersmith, et al, "Complications of Endovascular Embolization in 182 Patients with Cerebral AVMs," presented at the annual meeting of the American Society of Neuroradiology, Orlando, Fla, March 1989; J. M. Eskridge, R. P. Hartling, "Preoperative Embolization of Brain AVMs using Surgical Silk and Polyvinyl Alcohol" (abstract), *AJNR Am J Neuroradiol*

1989;10:882). The use of many embolic agents has been reported, including silk sutures, polyvinyl alcohol (PVA) particles, various coils, and glue (1–3). Concerns over inflammatory reaction to these embolic agents and associated treatment complications have been a recurrent theme in the literature (4–10). Although immediate or delayed hemorrhage associated with embolization can be a serious complication (11–13), the relationship between inflammatory response to embolic agents and subsequent hemorrhage remains unclear. Deveikis et al (14) described hemorrhagic complications with poor outcomes in a small series of patients in whom silk was used as one of many embolic agents. Vasculitis with angionecrosis was implicated as the cause. We report our experience with the use of 6–0 silk suture as the primary embolic agent for preoperative embolization of cerebral AVMs in 73 consecutive patients. The results suggest that silk is a comparatively safe embolic material.

---

Received June 14, 1995; accepted after revision January 7, 1997.

From the Departments of Radiology (F.S., W.M.), Pathology (D.M.A.), and Neurological Surgery (J.P.E., J.M.E., H.R.W.), University of Washington, Seattle.

Address reprint requests to Joseph M. Eskridge, MD, Department of Neurological Surgery, University of Washington, Seattle, WA 98195.

*AJNR* 18:1233–1237, Aug 1997 0195-6108/97/1807-1233

© American Society of Neuroradiology

## Materials and Methods

We retrospectively reviewed the medical and radiologic records of 73 consecutive patients who had cerebral AVMs embolized with silk and other agents between March 1988 and February 1994. We also reviewed the histopathologic findings in 48 of the 58 AVMs that were resected. Specimens for 10 resected AVMs were not available, and 15 AVMs were not resected because the patients were not favorable candidates for surgery.

The 41 male and 32 female subjects who constituted the study group ranged in age from 13 to 67 years. Staged embolization was performed over a period of weeks to months using silk as the sole or major embolic agent. In the majority (89%) of cases, silk was supplemented with PVA, glue, or microcoils.

After the induction of neuroleptic anesthesia, a 6F or 7F guiding catheter was positioned in the high cervical internal carotid or vertebral artery. Systemic anticoagulation was accomplished using 5000 to 7000 units of heparin. The adequacy of anticoagulation was verified using an activated clotting time of greater than 300 seconds. Microcatheters of variable stiffness (0.018 Fast Tracker, Target Therapeutics, Fremont, Calif) or flow-directed microcatheters (3F, Balt Magic, Paris, France, with the radiopaque tip removed to allow the passage of silk suture) were used for selective vessel catheterization and embolization.

Superselective angiography, in conjunction with intraarterial sodium amobarbital injection and clinical neurologic examination, was performed before embolization to identify vessels supplying essential territories of the central nervous system. When embolization was considered safe, 6–0 silk suture cut into 2- to 3-cm lengths was hand-loaded into the microcatheter hub and injected with a 1-mL Luer-Lok syringe filled with saline solution. The microcatheter was flushed after the delivery of each piece of silk. Intermittent fluoroscopy was used to assess the catheter position and the rate of blood flow through the vascular pedicle being embolized. Obliteration of a feeding pedicle was typically accomplished within 10 to 35 minutes. Catheters were removed and anticoagulation was reversed using 100 mg of protamine sulfate.

The size of each AVM was assessed angiographically before and after embolization by the same neuroradiologist. All angiograms were evaluated for evidence of vasculitis. Routine postembolization computed tomography (CT) was performed to identify immediate hemorrhage. Follow-up CT studies to monitor delayed hemorrhage ranged from 8 months to 6 years (mean, 15 months).

Resected specimens were fixed in 10% buffered formalin and embedded in paraffin. Selections from the specimens were stained for histologic examination with hematoxylin-eosin and Verhoeff–van Gieson elastica. All surgical specimens were examined by the same neuropathologist. Vessels were evaluated for the presence of silk, vasculitis, perivascular inflammation, and vessel necrosis. Vasculitis and perivasculitis were graded as none, mild, moderate, or severe. Vessel necrosis was noted to be present or absent.

Histologic vasculitis was considered mild if inflammation was confined to the intimal layers, moderate if inflammation included focal mural extension, and severe if there was complete transmural extension. Histologic perivascular inflammation was graded subjectively according to the distribution of inflammatory cells around and between vessels. These results were correlated with the time interval between initial embolization and surgical resection.

## Results

### *Embolization*

Fifty-two (71%) of the AVMs were large (diameter greater than 3 cm) and 21 (29%) were small (3 cm or smaller). Twenty-five (34%) of the patients had a history of intracranial hemorrhage (intraparenchymal, intraventricular, subarachnoid, or a combination of these) that preceded endovascular therapy. Silk was the sole embolic agent used in eight patients (11%). Silk and PVA were combined in 55 patients (75%). Silk, PVA, and *N*-butyl cyanoacrylate (NBCA) were combined in one patient. Silk, PVA, and microcoils were combined in the remaining nine patients (12%). The caliber of silk suture was 6–0 in all cases. Ninety percent to 100% obliteration of the AVM nidus was obtained in 31 patients (43%), 75% to 89% obliteration was obtained in 17 patients (23%), and 50% to 74% obliteration was obtained in 25 patients (34%).

### *Hemorrhage*

One patient suffered an intracranial hemorrhage as a direct consequence of endovascular therapy with silk sutures. This patient was a 38-year-old woman with a large right parietooccipital AVM who had a subarachnoid hemorrhage after the rupture of an angular artery branch during injection of silk. The angiographer noted increased resistance to injection of silk immediately before the artery ruptured and subsequent contrast extravasation. Immediate repeat angiography did not show continued contrast extravasation. After the microcatheter was removed, a small linear fissure was identified in the distal portion of the catheter proximal to an occlusion produced by silk lodged in the tip of the catheter. We concluded that this hemorrhage was the result of a technical problem related to the manner of silk delivery. The radiopaque catheter tip had not been removed in this case, which may have added a propensity

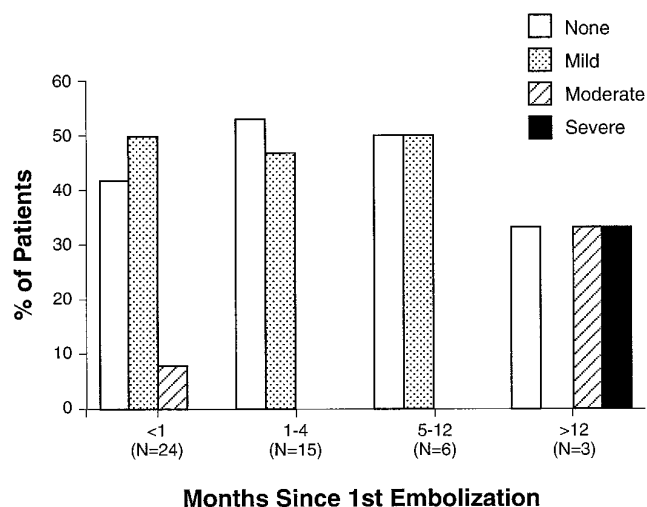


Fig 1. Histologic analysis of vasculitis.

for mechanical blockage at the tip. The postembolization CT scan showed a mixture of contrast material and acute subarachnoid blood. Headache, meningismus, and lethargy developed but the patient remained neurologically intact and all symptoms resolved within 3 days.

Two patients had AVMs with intraventricular extension. Postembolization CT scans showed layered high-density fluid in dependent portions of the ventricles. Both patients remained asymptomatic and the dense ventricular fluid cleared within 24 hours. It is thought that this fluid was most likely extravasated contrast material from intrinsically leaky AVM nidus vessels in contact with the ventricles and not frank hemorrhage.

#### *Vasculitis and Vessel Wall Necrosis*

Angiography did not show evidence of vasculitis after AVM embolization. In the 48 resected AVM specimens available for evaluation, histologic vasculitis was absent or mild in 44 cases (92%) (Fig 1). In two of the four cases in which vasculitis was moderate or severe, the first embolizations were done more than 12 months before resection. Specimens from patients in whom silk was the sole embolic agent showed mild vasculitis in four (100%) of four cases.

Histopathologic evidence of perivascular inflammation was absent or mild in 35 cases (73%) (Fig 2). Perivascular inflammation was only observed in specimens from AVMs resected 12 months or less after the first embolization. No obvious difference in severity was

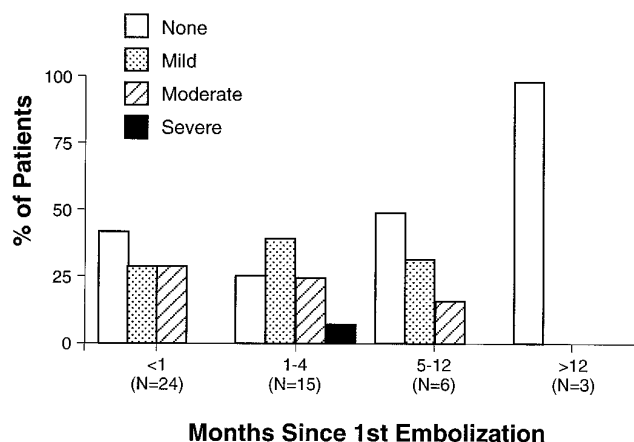

Fig 2. Histologic analysis of perivascular inflammation.

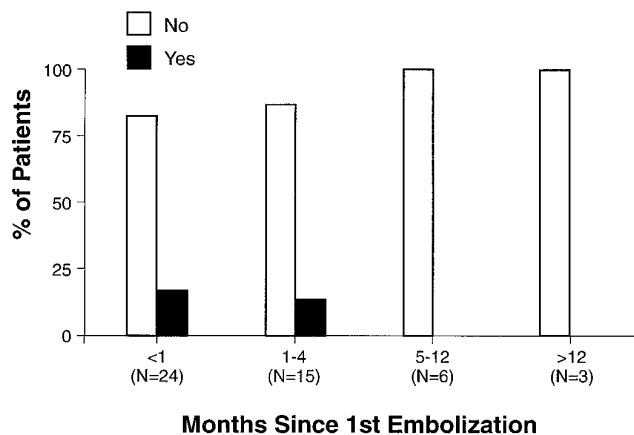


Fig 3. Histologic analysis of vessel necrosis.

appreciated for various intervals within that period. Histopathologic specimens from the four patients in whom silk was the sole embolic agent showed mild perivascular inflammation in one (25%); no inflammation was evident in the other three.

Histopathologic vessel necrosis was identified in six cases (12%) (Fig 3), and vessel necrosis was localized in all six. This was not observed in any specimens for which the time from first embolization to resection was greater than 4 months. Recanalization of AVM vessels occurred in nine cases (19%).

#### **Discussion**

A previous publication has suggested that silk may produce an inflammatory reaction leading to vessel wall necrosis and subsequent hemorrhage (14). We investigated this possibility through retrospective analysis of our cohort of 73 patients with AVMs treated preoperatively with silk suture embolization with and without

other embolic agents. We examined angiographic, CT, and histopathologic material for evidence of inflammation or hemorrhage.

In our series, only one (1%) of 73 patients hemorrhaged as a direct consequence of silk suture embolization. This was most likely a result of catheter blockage and the application of increased pressure, which ruptured the microcatheter and the adjacent vessel. Inflammation and vessel wall necrosis were not thought to be the cause. Mechanical occlusion of the microcatheter tip can be a problem with the larger embolic materials, particularly if the radiopaque tip marker has not been removed, which was the case here.

The operator needs to become familiar with the subtle changes in injection pressure that warn of impending occlusion. Conscientious flushing of the microcatheter between silk suture injections is important. Increased intraluminal pressure may lead to deformity or frank rupture of a microcatheter, precipitating rupture of an adjacent vessel.

Another important consideration in the use of silk is that it is radiolucent and can be injected unknowingly into vessels other than the targeted AVM pedicle. This risk is particularly high at the end of embolization, when there is an increasing probability of refluxing material into more proximal vessels. Intermittent injection of contrast agent will assist in closely monitoring the progress of embolization as well as the potential for reflux.

In our series, there was no angiographic evidence of vasculitis, and histologic analysis revealed a limited inflammatory response in most specimens. Notably, vasculitis was mild and perivascular inflammation was mild or absent in all the AVM specimens in which silk was the sole embolic agent. Vessel necrosis was also uncommon. Our neuropathologist has observed that although large numbers of hyalinized vessels were apparent on examination of most AVMs, similar vessels have been found in specimens resected from patients who have not undergone preoperative embolization (unpublished data, 1996).

An obvious difficulty encountered with our series in trying to assess the inflammatory or necrosing quality of silk compared with other embolic agents is that silk was combined with other agents in the majority of our patients. Although it would be informative to compare specimens in which embolic agents exclusive of

silk were used (as well as to compare specimens in which no preoperative embolization occurred), a marked inflammatory response was not common in our patients in whom silk was the sole or major embolic agent used, as noted above.

Another potential source of confusion occurs in those patients who have had an intracranial hemorrhage before embolization. Hemorrhage is likely to produce an inflammatory response, which might lead to an overestimation of the inflammatory response to the embolic agents.

Sampson (15) noted that most institutions using endovascular therapy for the treatment of AVMs report an overall frequency of hemorrhagic complications in the range of 3% to 5%. Our results are similar, and are comparable to the findings described by Jafar and Rezai (16) in which hemorrhage occurred in eight (5%) of 150 pial AVMs treated with embolization and surgery. However, our results are in contrast to those of Deveikis et al (14), who described hemorrhage in three (50%) of six patients after embolization of AVMs with a variety of agents, including silk. The source of this disparity with our experience is not known, but given the small sample size and the variety of embolic agents used, some caution should be exercised when considering the results and conclusions of this smaller series.

Our findings do not suggest that silk has a special propensity as an embolic agent to produce inflammation with angioneclerosis, which might lead to hemorrhage. Although embolization with silk and other agents may be associated with some inflammation and angioneclerosis, overall we found a low frequency of hemorrhage in our series. The one instance in which hemorrhage could be attributed directly to silk embolization was most likely the result of technical difficulty. With an appropriate technique, silk used alone or in concert with other embolic agents has been a safe and effective material for therapeutic embolization of cerebral AVMs in our institution.

## References

1. Halbach VV, Higashida RT, Hieshima GB. Interventional neuroradiology. *AJR Am J Roentgenol* 1989;153:467-476
2. Purdy PD, Batjer HH, Risser RC, Samson D. Arteriovenous malformations of the brain: choosing embolic materials to enhance safety and ease of excision. *Neurosurgery* 1992;77:217-222
3. Purdy PD, Samson D, Batjer HH, et al. Preoperative embolization of cerebral arteriovenous malformations with polyvinyl alcohol

- particles: experience in 51 adults. *AJNR Am J Neuroradiol* 1990; 11:501-510
4. Brothers MF, Kaufmann JCE, Fox AJ, Deveikis JP. *n*-Butyl 2-cyanoacrylate substitute for IBCA in interventional radiology: histopathologic and polymerization time studies. *AJNR Am J Neuroradiol* 1989;10:777-786
  5. Cromwell LD, Freeny PC, Kerber CW, et al. Histologic analysis of tissue response to bucrylate-pantopaque mixture. *AJR Am J Roentgenol* 1986;147:627-631
  6. Germano IM, Davis RL, Wilson CB, Hieshima GB. Histopathological follow-up of 66 cerebral arteriovenous malformations after therapeutic embolization with polyvinyl alcohol. *J Neurosurg* 1992;76:607-614
  7. Quisling RG, Mickle JP, Ballinger WB, et al. Histopathological analysis of intraarterial polyvinyl alcohol microemboli in rat cerebral cortex. *AJNR Am J Neuroradiol* 1984;5:101-104
  8. Radhakrishnan VV, Saraswathy A, Rao VRK, et al. Histopathologic evaluation of polymethyl methacrylate as an embolic agent. *Acta Neurochir (Wien)* 1992;117:30-33
  9. Vinters HV, Lundie MJ, Kaufmann JCE. Long-term pathological follow-up of cerebral arteriovenous malformation treated by embolization with bucrylate. *N Engl J Med* 1986;314:477-483
  10. White RI Jr, Strandberg JV, Gross GS, et al. Therapeutic embolization with long-term occluding agents and their effects on embolized tissues. *Radiology* 1977;125:677-687
  11. Fox AJ, Pelz DM, Lee DH. Arteriovenous malformation of the brain: Recent results of endovascular therapy. *Radiology* 1990; 177:51-57
  12. Jafar JJ, Davis A, Berenstein A. The effect of embolization with *N*-butylcyanoacrylate prior to surgical resection of cerebral arteriovenous malformations. *J Neurosurg* 1993;78:60-69
  13. Purdy PD, Batjer HH, Samson D. Management of hemorrhagic complications from preoperative embolization of arteriovenous malformations. *J Neurosurg* 1991;74:205-211
  14. Deveikis JP, Manz HJ, Luessenhop AJ, et al. A clinical and neuropathologic study of silk suture as an embolic agent for brain arteriovenous malformations. *AJNR Am J Neuroradiol* 1994;15:263-271
  15. Samson D. Comments regarding Jafar and Rezai, 1994. *Neurosurgery* 1994;34:12-13
  16. Jafar JJ, Rezai AR. Acute surgical management of intracranial arteriovenous malformations. *Neurosurgery* 1994;34:8-12