



Get Clarity On Generics

Cost-Effective CT & MRI Contrast Agents



FRESENIUS
KABI

WATCH VIDEO

AJNR

Precise placement of sphenoidal electrodes via fluoroscopic guidance.

D S Fenton, G K Geremia, A M Dowd, M A Papathanasiou,
W M Greenlee and M S Huckman

AJNR Am J Neuroradiol 1997, 18 (4) 776-778

<http://www.ajnr.org/content/18/4/776>

This information is current as
of August 13, 2025.

Precise Placement of Sphenoidal Electrodes via Fluoroscopic Guidance

Douglas S. Fenton, Glen K. Geremia, Anne M. Dowd, Matilda A. Papathanasiou, William M. Greenlee, and Michael S. Huckman

Summary: Fluoroscopically guided placement of sphenoidal electrodes for the assessment of epileptiform activity in the mesial-basal-temporal lobes offers distinct advantages over standard techniques, such as more precision in placement, reduced likelihood of facial pain, and fewer complications (vessel perforation or nerve injury). We describe our instrumentation, technique, and results in over 40 patients.

Index terms: Seizures; Fluoroscopy; Sphenoid bone

The benefits of sphenoidal electrodes versus scalp electrodes and more invasive intracranial electrodes in recording epileptiform activity of mesial-basal-temporal origin have been well documented (1, 2). In many institutions, sphenoidal electrodes are placed blindly, without fluoroscopic guidance, into the infratemporal fossa with their tips positioned at various distances from the optimal target, the foramen ovale (3, 4). The electrodes are loaded onto a carrier needle. During blind placement, the needle is inserted through the skin at a point 3 cm anterior to the external auditory canal, beneath the zygomatic arch, and through the mandibular notch. The tip of the needle is advanced to a depth of 4 to 5 cm beneath the skin's surface or until the patient reports mandibular pain. In one study, the accuracy of blind placement of sphenoidal electrodes was checked radiographically in six of 17 patients (4). All 12 electrodes placed in these six patients fell short of the lateral border of the foramen ovale by distances ranging from 4 to 35 mm. Thus, neither depth nor mandibular pain proved to be a reliable end point for targeting. We describe a fluoroscopic technique for more precise placement of electrodes.

Technique

Patients are screened for coagulopathy 24 hours preceding the procedure, and informed consent is obtained.

Bleeding times are obtained in addition to routine coagulation studies for patients being treated with valproic acid. Blood pressure, pulse, and oxygen saturation are monitored throughout the examination.

The required instrumentation consists of multistranded, 34-gauge, polytef-coated, stainless steel wires (sphenoidal electrodes); a 3.5-in spinal needle; and a 25-gauge, 1.5-in needle. A 10-mL syringe containing buffered 1% lidocaine is also needed. The sphenoidal electrode/needle system is created by removing the spinal needle stylets and back-loading the exposed portion of the wire approximately 5 mm into the spinal needle (Fig 1A). With a multifilament electrode, it may be necessary to roll the exposed wire between the thumb and index finger before inserting the wire into the needle. The remainder of the wire is bent back along the outer surface of the needle and hooked into the notch of the needle hub (Fig 1B). Biplane digital imaging is preferred to allow quick needle adjustments, although a single-plane imager will suffice. The foramen ovale and foramen spinosum must be adequately visualized for accurate needle placement.

A pillow is placed under the patient's shoulders to extend the head for optimal visibility of the foramen ovale in the anteroposterior plane. Submentovertex radiography and lateral positioning are used. A sterile field is created over a generous area of skin ventral to the external auditory canal and tragus. Lidocaine is injected into the subcutaneous and deep soft tissues midway between the mandibular condyle and coronoid process, and 3 to 5 mm inferior to the zygomatic arch and skull base (Fig 2). The patient may experience pain if the electrode is placed too near the fibrocartilage of the temporomandibular joint.

The electrode/needle system must be held together at the hub during manipulation or premature deployment of the wire may occur; if this happens, the wire can be gently removed under fluoroscopy. The electrode/needle system is inserted into the skin parallel to the lateral fluoroscopic beam, and is advanced 1 to 2 cm into the soft tissues, passing inferior to the zygoma and skull base. Anteroposterior fluoroscopy is then used to assess needle position in relation to the foramen ovale and foramen spinosum. The system is angled and advanced so that the needle tip lies anterior to the foramen ovale (Fig 3), avoiding the middle

Received April 23, 1996; accepted after revision July 18.

From the Department of Radiology, Rush-Presbyterian-St Luke's Medical Center, 1653 W Congress Parkway, Chicago, IL 60612. Address reprint requests to Glen K. Geremia, MD.

AJNR 18:776-778, Apr 1997 0195-6108/97/1804-0776 © American Society of Neuroradiology

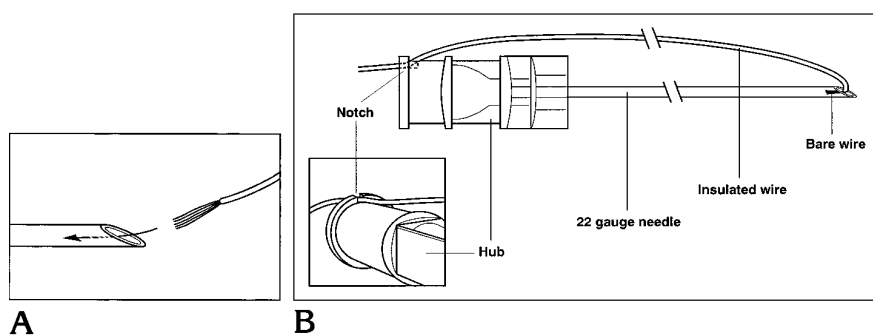


Fig 1. Sphenoidal electrode/needle system.

A, The noninsulated portion of a multi-stranded electrode is back-loaded into a spinal needle (stylet has been removed).

B, The wire is bent at the junction of its insulated and noninsulated portions and runs parallel to the needle. The wire is hooked into the notch of the needle hub.

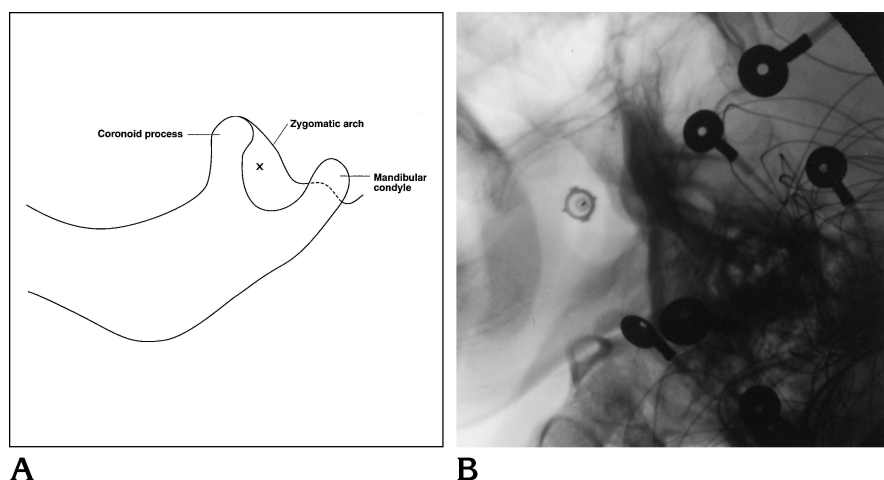


Fig 2. Insertion point.

A, Illustration shows the normal anatomic relationship of the mandibular condyle, coronoid process, and zygomatic arch in the lateral projection.

B, Lateral radiograph shows the needle positioned inferior to the zygomatic arch and midway between the mandibular condyle and coronoid process.

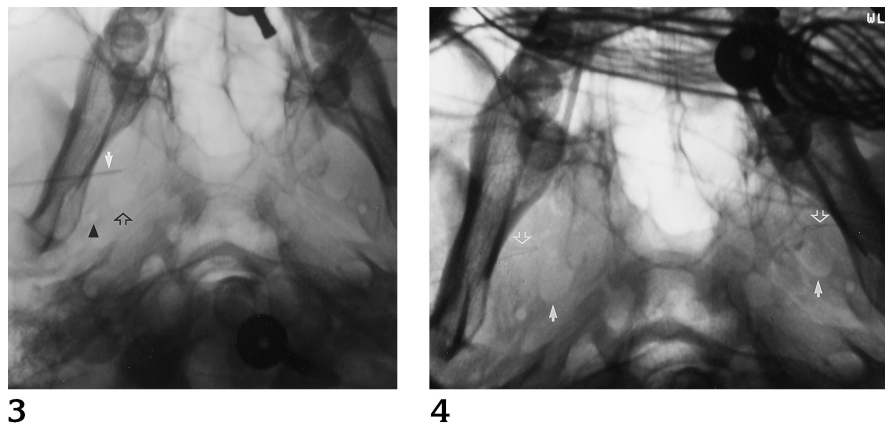


Fig 3. Submentovertex radiograph shows the normal relationship of the foramen ovale (open arrow) to the foramen spinosum (arrowhead). The electrode/needle system (solid arrow) is positioned anterior and slightly lateral to the foramen ovale.

Fig 4. Postprocedural submentovertex radiograph shows the position of both sphenoidal electrode wires (open arrows) anterior and lateral to their respective foramina ovale (solid arrows).

meningeal artery at the foramen spinosum and the gasserian ganglion at the foramen ovale. The optimal position is with the needle tip just anterior and lateral to the foramen ovale. The patient may experience transient pain in the ipsilateral face and jaw, and repositioning may be necessary if the pain persists. With the tip of the electrode/needle system anterior to the foramen ovale, the external portion of the wire is then compressed against the patient's skin while the needle is removed, leaving the wire in position. Mild pressure with gauze may be necessary to control minor bleeding. The exposed wire is then gently looped and taped to the skin to prevent accidental movement or removal, and the procedure is repeated on the opposite

side. Submentovertex radiography of the skull base confirms the position of the wires (Fig 4). In our experience, the electrodes are left in place until adequate seizure activity has been recorded. This period of time is usually less than 2 weeks.

Discussion

Fluoroscopic placement of sphenoidal electrodes may help detect seizure foci previously undetected by electrodes placed blindly. Kanner et al (4) performed a retrospective analysis

of 17 patients with pharmacologically intractable partial seizures in whom blind placement of sphenoidal electrodes failed to delineate the electrographic anterior-mesial-temporal focus (4). In nine of these 17 patients, a seizure focus within this region was discovered when sphenoidal electrodes were subsequently placed under fluoroscopic guidance.

Sphenoidal electrode placement under fluoroscopic guidance offers distinct advantages over the more commonly performed blinded procedure. Fluoroscopy allows more precise placement of the electrodes, resulting in greater sensitivity in the detection of mesial-basal-temporal lobe epileptiform activity. Under direct visualization, severe facial pain is unlikely, since the foramen ovale is avoided. Finally, potential complications related to vessel perforation or

nerve injury are reduced. We noted no complications in our experience with bilateral, fluoroscopically guided sphenoidal electrode placement in over 40 patients.

References

1. Sperling MR, Mendius JR, Engel J. Mesial temporal spikes: a simultaneous comparison of sphenoidal, nasopharyngeal, and ear electrodes. *Epilepsia* 1986;27:1:81-86
2. Kristensen O, Sindrup EH. Sphenoidal electrodes: their use and value in the electroencephalographic investigation of complex partial epilepsy. *Acta Neurol Scand* 1978;58:157-166
3. Wilkus RJ, Thompson PM. Sphenoidal electrode positions and basal EEG during long term monitoring. *Epilepsia* 1985;26:137-142
4. Kanner AM, Ramirez L, Jones J. The utility of placing sphenoidal electrodes under the foramen ovale with fluoroscopic guidance. *J Clin Neurophysiol* 1995;12:72-81