



## Get Clarity On Generics

Cost-Effective CT & MRI Contrast Agents



WATCH VIDEO

# AJNR

### **Absence of the common crus in Goldenhar syndrome.**

L Manfré, P Genuardi, M Tortorici and R Lagalla

*AJNR Am J Neuroradiol* 1997, 18 (4) 773-775

<http://www.ajnr.org/content/18/4/773>

This information is current as  
of August 6, 2025.

# Absence of the Common Crus in Goldenhar Syndrome

Luigi Manfré, Piero Genuardi, Manlio Tortorici, and Roberto Lagalla

**Summary:** We describe an unusual labyrinthine malformation in a case of Goldenhar syndrome studied with CT and steady-state MR imaging. A single posterosuperior semicircular canal was found with no common crus formation. The malformation could not be attributed to any embryologic development. Nosologic considerations are discussed.

**Index terms:** Ear, abnormalities and anomalies; Children, diseases

Oculoauriculovertebral dysplasia, also known as Goldenhar syndrome, is a congenital condition that includes anomalies of the derivatives of the first and second branchial arches, vertebral defects, and ocular abnormalities, generally epidermoids.

Since the syndrome was described in 1952 (1), various combinations of ocular (epibulbar dermoids and colobomas, microphthalmia), vertebral (cervicovertebral fusion), cardiovascular (ventricular septal defects, mitral stenoses), facial (median cleft face syndrome), oral (cleft palate), auricular, visceral (absence of portal vein), spinal (spina bifida), and cranial (lipomas and dermoids) malformations have been described. Characteristic polytomographic and computed tomographic (CT) features of Goldenhar syndrome have also been reported (2, 3).

We present the CT and magnetic resonance (MR) imaging findings in a patient with Goldenhar syndrome who had an unusual labyrinthine malformation. A brief nosologic hypothesis is added.

## Case Report

A 6-year-old boy with bilateral conductive hearing loss but normal neurosensory function was referred to us for a temporal bone study. On examination, the patient was noted to have bilateral preauricular skin tags and low pinna attachment. Bilateral epibulbar dermoids, median

cleft palate and left-sided cleft lips, webbed neck, hypertelorism, and an undescended right testis were also found. Contiguous axial and coronal 1-mm-thick CT sections were obtained at the level of the temporal bone with a 16-cm field of view. Upper cervical spine anomalies had previously been excluded by plain films. A bone algorithm was also applied.

A medium-field-strength MR unit equipped with a 5-in surface coil was used to examine the inner ear, one side at a time. The membranous labyrinth was imaged with the use of steady-state sequences. Axial, gradient-recalled acquisition in the steady state images were obtained using 0.75-mm-thick sections with no gap and imaging parameters of 30–80/17–22/2 (repetition time/echo time/excitations), 60° to 90° flip angle, 256 × 256 matrix, and 22-cm field of view. Maximum intensity projection reconstructions were done on a dedicated workstation (Sun Microsystems, Mountain View, Calif) for three-dimensional images.

## Results

On the left side, both CT and MR images showed a cystic lateral semicircular canal and vestibular dysplasia (4). On the right side, a complex malformation was found in which the anterior limb of the superior semicircular canal and the inferior limb of the posterior semicircular canal were joined together (Fig 1A and B), resulting in a single, wide, posterosuperior semicircular canal (Fig 1C). There was dysplasia of the lateral semicircular canal and the vestibule. No abnormality of the cochlea was found on either side, and the middle ear cavities were of normal size and shape. A right-sided fused ossicular mass was noted, and there was a mild atresia of the right external auditory canal.

## Discussion

External and middle ear malformations are common findings in patients with Goldenhar

Received April 22, 1996; accepted after revision August 2.

From the Departments of Radiology "P. Cignolini" (L.M., R.L.) and ENT (P.G., M.T.), University of Palermo (Italy).

Address reprint requests to Dr Luigi Manfré, Department of Radiology, University of Palermo, via Villa Sperlinga, n. 3, Palermo 90144, Italy.

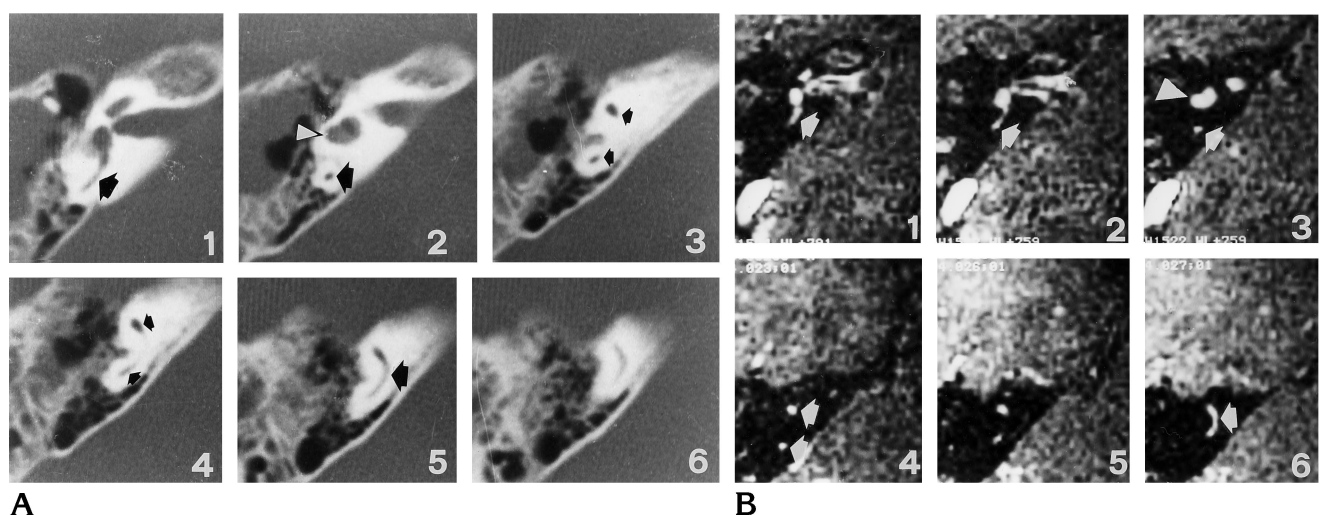


Fig 1. A 6-year-old boy with Goldenhar syndrome. Serial CT scans (A) and contiguous steady-state MR images (B), 1 to 6, of the right inner ear in the caudocranial direction, and 3-D maximum intensity projection reconstruction (C) of a sagittal view, with a normal labyrinth for comparison (D). The single posterosuperior semicircular canal is indicated by the *arrows* in A and B. At this stage, development of the lateral semicircular canal has not been completed, so a cystic lateral semicircular canal is also found (*arrowheads* in A and B). The round posterosuperior semicircular canal is seen better on the 3-D reconstruction (*arrowheads* in C). In a normal labyrinth (D), the common crus (*arrow*), shared by the superior (S) and posterior (P) semicircular canals, is always seen.

syndrome, being sequelae of abnormal development of the first and second branchial arches. Inner ear malformations (eg, deficiencies of the interscalar septum, as commonly seen in Mondini malformation) have also been described. The pathogenesis of ear defects in Goldenhar syndrome remains controversial; however, in animal models, Poswillo (5) determined that focal hemorrhages during embryonic life are responsible for local ear precursor destruction, with consequent abnormal repair. Because he found no inner ear involvement, Poswillo supposed the otic capsule to be an efficient barrier, preventing damage from the local hematoma.

According to Jackler et al (6), inner ear malformations should be related to a developmental arrest of the otic bud occurring during the fifth to seventh week of embryonic life. Development of the semicircular canals starts at approximately day 36, with a small bulging from the superior aspect of the vestibular process of the otocyst becoming a nearly disk-shaped

structure by day 42 and finally evolving into the typical tubular structure of the superior semicircular canal by pinching in of the mesenchyme inside the central neuroectodermal core at day 44. The same evolution occurs in the formation of the posterior semicircular canal, starting approximately at day 42 and finishing by the end of day 47. The posterior canal shares a common limb (common crus) with the superior canal; consequently, the superior and posterior semicircular canals develop approximately at the same time and are intimately related. Later, the lateral semicircular canal forms, starting its formation approximately at day 44 and reaching maturity at day 49 (7).

Unlike the Mondini malformation, the single posterosuperior semicircular canal does not correspond to any embryonic step in the development of the otic bud. One possible explanation would be abnormal reabsorption of the neuroectodermal tissue of the common crus, related to inner ear damage from local hematoma or vascular abnormality.

## References

1. Goldenhar M. Associations malformatives de l'oeil et de l'oreille, en particulier le syndrome dermoide epibulbaire-appendices auriculaires-fistula auris congenita et ses relations avec la dysostose mandibulo-faciale. *J Genet Hum* 1952;1:234-282
2. Phelps PD, Lloyd GAS, Poswillo DE. The ear deformities in cranio-facial microsomia and oculo-auriculo-vertebral dysplasia. *J Laryngol Otol* 1983;97:995-1005
3. Mafee M, Valvassori GE. Radiology of the craniofacial anomalies. *Otolaryngol Clin North Am* 1981;14:983
4. Jackler RK. Congenital malformation of the inner ear. In: Cummings CW, Fredrickson JM, Harker LA, Krause CJ, Schuller DE, eds. *Otolaryngology*. St Louis, Mo: Mosby; 1992;34
5. Poswillo D. The pathogenesis of the first and second branchial arches syndrome. *Oral Surg* 1973;35:302-328
6. Jackler RK, Luxford WM, House WF. Congenital malformations of the inner ear: a classification made on embryogenesis. *Laryngoscope* 1987;97:2-14
7. Eyries C, Perles B. Embryologie de l'oreille. *ORL J Otorhinolaryngol Relat Spec* 1962;3:1-12