



Get Clarity On Generics

Cost-Effective CT & MRI Contrast Agents

**FRESENIUS
KABI**

[WATCH VIDEO](#)

AJNR

Single-photon emission CT and MR findings in Klüver-Bucy syndrome after Reye syndrome.

H Ozawa, M Sasaki, K Sugai, T Hashimoto, H Matsuda, S Takashima, A Uno and T Okawa

This information is current as of August 18, 2025.

AJNR Am J Neuroradiol 1997, 18 (3) 540-542
<http://www.ajnr.org/content/18/3/540>

Single-Photon Emission CT and MR Findings in Klüver-Bucy Syndrome after Reye Syndrome

Hiroshi Ozawa, Masayuki Sasaki, Kenji Sugai, Toshiaki Hashimoto, Hiroshi Matsuda, Sachio Takashima, Akira Uno, and Takashi Okawa

Summary: We present the MR and single-photon emission CT findings in a 3-year-old patient in whom Klüver-Bucy syndrome developed after Reye syndrome. MR images showed diffuse brain atrophy, which was predominant in the temporal lobes, and single-photon emission CT scans showed decreased cerebral perfusion in the bilateral temporal lobes and associated cortical areas.

Index terms: Degenerative disease; Children, diseases; Reye syndrome

In 1939, Klüver and Bucy described a behavioral syndrome in rhesus monkeys observed after bilateral temporal lobectomy. The syndrome included psychic blindness, a strong tendency to examine all objects orally, an irresistible impulse to touch, loss of normal anger and fear responses, and increased sexual activity (1). We report the findings at magnetic resonance (MR) imaging and single-photon emission computed tomography (SPECT) in a patient in whom Klüver-Bucy syndrome developed after a definite diagnosis of Reye syndrome.

Case Report

A 3-year-old girl was admitted to the National Defense Medical College Hospital because of recurrent vomiting, disturbance of consciousness, and repetitive convulsions. On admission, she was comatose, and had generalized tonic seizures and hepatomegaly. On the second day of admission, laboratory examinations revealed 2427 IU/L glutamic-oxaloacetic transaminase (normal, 8 to 30 IU/L) and 1297 IU/L glutamic pyruvic transaminase (normal, 5 to 35 IU/L). Histopathologic examination of a liver biopsy specimen showed diffuse microvesicular lipid droplet infiltration without an inflammatory reaction or necrosis,

which is compatible with the pathologic findings in Reye syndrome. A definite diagnosis of Reye syndrome was established, and the patient was treated with repeated plasma exchanges, osmotherapy, gabexate mesilate, carnitine, and antibiotics. Her clinical condition gradually improved, but she could not recognize her parents or utter any meaningful words. She was discharged on the 79th hospital day.

After discharge, the patient had attacks of myoclonus of both upper limbs, which prompted admission to our hospital. On initial examination, she showed abnormal behavior. She put toys in her mouth, and ate such objects as paper and buttons (oral tendency). She wanted to touch everything within sight (hypermetamorphosis). She could not discriminate family members from strangers (visual agnosia), and she was unusually placid. A diagnosis of Klüver-Bucy syndrome was posited. MR imaging, performed with a superconducting magnet operating at 2.0 T, revealed diffuse brain atrophy, which was predominant in the temporal lobes bilaterally. On coronal images, bilateral hippocampal atrophy was evident (Fig 1A and B). The SPECT study, obtained with technetium Tc 99m ethyl cystinate dimer revealed widespread decreased cerebral perfusion in the bilateral temporal lobes and in the frontal and parietal cortical areas (Fig 1C).

Discussion

Klüver-Bucy syndrome consists of six main symptoms: psychic blindness or visual agnosia, with an inability to recognize significant persons (ie, to discriminate family members from strangers); an oral tendency, or compulsion to examine objects by mouth; increased appetite or eating of inedible objects; hypermetamorphosis, or an irresistible impulse to notice and react to everything within sight; placidity,

Received January 2, 1996; accepted after revision May 3.

From the Departments of Child Neurology (H.O., M.S., K.S., T.H.) and Radiology (H.M.), National Center Hospital for Mental, Nervous and Muscular Disorders, and the Department of Mental Retardation and Birth Defect Research, National Institute of Neuroscience (S.T.), National Center of Neurology and Psychiatry, Tokyo, and the Division of Mental Retardation Research, National Institute of Mental Health (A.U.), National Center of Neurology and Psychiatry, Chiba, and the Department of Pediatrics, National Defense Medical College, Saitama (T.O.), Japan.

Address reprint requests to Hiroshi Ozawa, MD, Department of Child Neurology, National Center Hospital for Mental, Nervous and Muscular Disorders, National Center of Neurology and Psychiatry, 4-1-1 Ogawahigashi, Kodaira, Tokyo 187, Japan.

AJNR 18:540-542, Mar 1997 0195-6108/97/1803-0540 © American Society of Neuroradiology

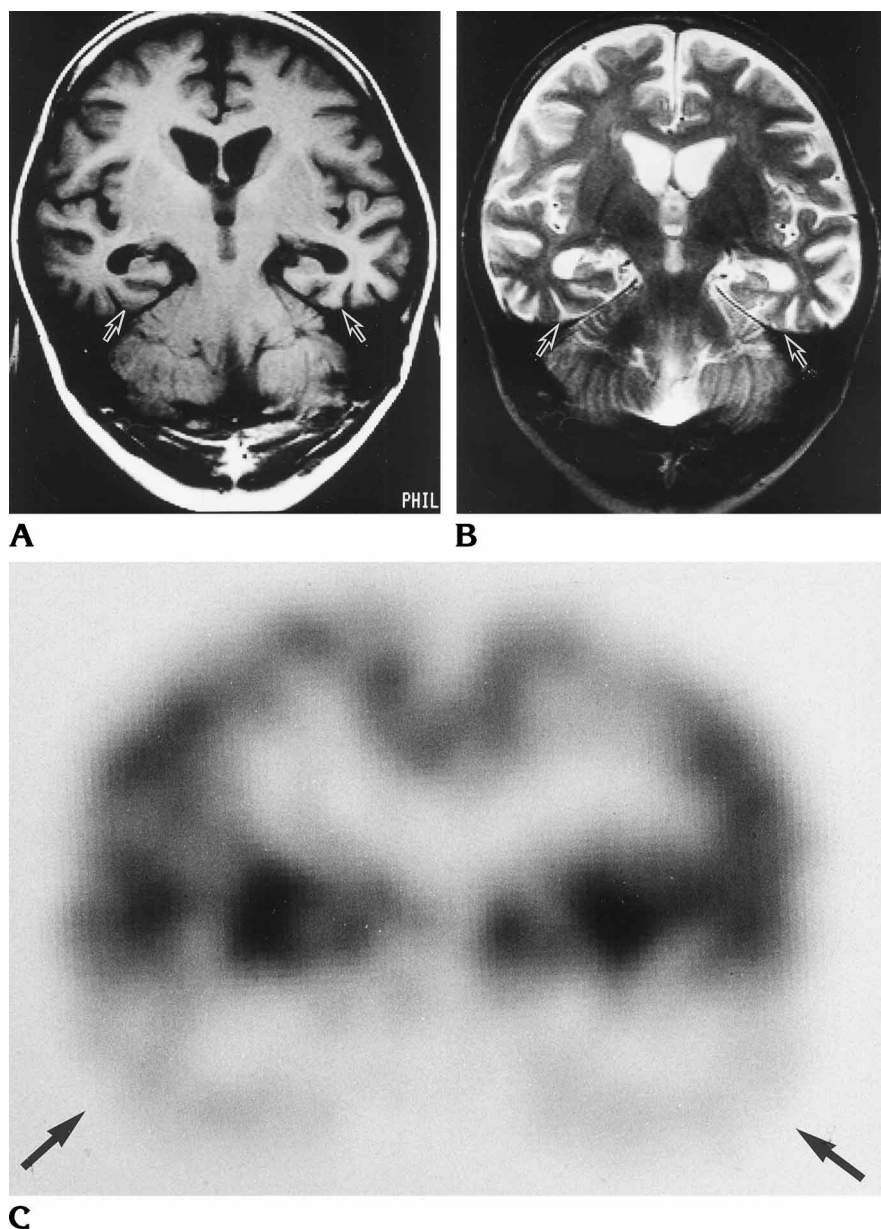


Fig 1. A 3-year-old girl with Klüver-Bucy syndrome after Reye syndrome.

A, Coronal T1-weighted (550/19 [repetition time/echo time]) MR image shows diffuse brain atrophy, especially in the temporal lobes and hippocampi (arrows).

B, Coronal T2-weighted (2100/100) MR image also shows diffuse brain atrophy, prominently in the bilateral hippocampi (arrows).

C, Coronal SPECT scan shows bilateral temporal hypoperfusion, including the hippocampal areas (arrows).

blunted affection, apathy, and petlike compliance; and altered sexual activity. A combination of at least three of these symptoms is highly suggestive of Klüver-Bucy syndrome (2, 3). In 1955, Terzian and Ore reported the same syndrome in humans after bilateral temporal lobectomy (4). Our patient had the first five of these six major symptoms of Klüver-Bucy syndrome. She did not exhibit altered sexual activity.

In humans, Klüver-Bucy syndrome has been reported with herpes simplex encephalitis (5), bilateral removal of the temporal lobes (4), head trauma, Pick disease (2), and hypoxia (3). On postmortem examination of a patient with

Klüver-Bucy syndrome following herpes simplex encephalitis, bilateral atrophy of the temporal lobes was observed (5). Both temporal lobes including the limbic areas were replaced by cystic and necrotic lesions. Microscopically, necrotic foci were seen in symmetrical areas of both temporal lobes, uncus, hippocampi, parahippocampi, cingulate gyri, amygdala, and insular gyri. In the present case, MR images revealed prominent brain atrophy in bilateral temporal lobes and in the hippocampi. The temporal lobes, including the hippocampi, may be replaced by cystic and necrotic tissue and by gliosis.

The hippocampus is a key structure in memory. In monkeys, destruction of the temporal lobes produces placidity and a lack of such reactions as fear, rage, and aggression (1). Similarly, atrophy and hypoperfusion of the temporal lobes in our patient produced psychic blindness, an oral tendency, eating of inedible objects, hypermetamorphosis, and placidity. On the other hand, cases of Klüver-Bucy syndrome have been reported in which no remarkable bilateral temporal structural lesions were observed on CT (3, 6, 7) or MR (8) studies of the brain. In these cases with fewer morphologic changes, the bilateral temporal lobe dysfunction presumably caused the syndrome.

SPECT is a useful noninvasive method for evaluating cerebral perfusion. It has shown poorly functioning regions of the brain as areas of hypoperfusion in a variety of disorders, including neuropsychiatric diseases (9) and viral encephalitis (10). In the present case, SPECT scans showed hypoperfusion in the bilateral frontal, parietal, and temporal regions, most remarkably in the latter. The widespread decreased cerebral perfusion seen both in the bilateral temporal lobes and in the frontal and parietal cortical areas suggests that SPECT may be a useful neuroimaging technique for detecting lesions even in patients with Klüver-Bucy syndrome in whom no remarkable mor-

phologic changes were evident on CT or MR studies.

References

1. Klüver H, Bucy PC. Preliminary analysis of functions of the temporal lobes in monkeys. *Arch Neurol Psychiatry* 1939;42:979-1000
2. Lilly R, Cummings JL, Benson DF, Frankel M. The human Klüver-Bucy syndrome. *Neurology* 1983;33:1141-1145
3. Tongsgard JH, Harwicke N, Levine SC. Klüver-Bucy syndrome in children. *Pediatr Neurol* 1987;3:162-165
4. Terzian H, Ore GD. Syndrome of Klüver and Bucy: reproduced in man by bilateral removal of the temporal lobes. *Neurology* 1955;5:373-380
5. Shoji H, Teramoto H, Satowa S, Satowa H, Narita Y. Partial Klüver-Bucy syndrome following probable herpes simplex encephalitis. *J Neurol* 1979;221:163-167
6. Nicolai A, Lazzarino LG, Alari E. Partial Klüver-Bucy syndrome arising from a multicentric glioblastoma: anatomo-clinical study of a case with unusual involvement of CNS. *Clin Neuropathol* 1991;10:16-20
7. Guedalia JSB, Zlotogorski Z, Goren A, Steinberg A. A reversible case of Klüver-Bucy syndrome in association with shigellosis. *J Child Neurol* 1993;8:313-315
8. Pitt DC, Kriel RL, Wagner NC, Krach LE. Klüver-Bucy syndrome following heat stroke in a 12-year-old girl. *Pediatr Neurol* 1995;13:73-76
9. Ohnishi T, Hoshi H, Nagamachi S, et al. High-resolution SPECT to assess hippocampal perfusion in neuropsychiatric diseases. *J Nucl Med* 1995;36:1163-1169
10. Kao CH, Wang SJ, Mak SC, Shian WJ, Chi CS. Viral encephalitis in children: detection with technetium-99m HMPAO brain single-photon emission CT and its value in prediction of outcome. *AJNR Am J Neuroradiol* 1994;15:1369-1373