



## Get Clarity On Generics

Cost-Effective CT & MRI Contrast Agents



FRESENIUS  
KABI

WATCH VIDEO

# AJNR

## **MR artifacts, heat production, and ferromagnetism of Guglielmi detachable coils.**

J Hartman, T Nguyen, D Larsen and G P Teitelbaum

*AJNR Am J Neuroradiol* 1997, 18 (3) 497-501

<http://www.ajnr.org/content/18/3/497>

This information is current as  
of August 10, 2025.

---

# MR Artifacts, Heat Production, and Ferromagnetism of Guglielmi Detachable Coils

J. Hartman, T. Nguyen, D. Larsen, and G. P. Teitelbaum

**Summary:** The Guglielmi detachable coil, a platinum microcoil used in the endovascular treatment of intracranial aneurysms, was studied in vitro for its MR imaging artifacts, heat production, and ferromagnetism. In addition, imaging artifacts were studied in vivo in eight patients who had undergone therapeutic placement of these coils. These devices displayed a very low level of MR artifact and no ferromagnetism or heat production. We conclude that the Guglielmi detachable coil is compatible with MR imaging in terms of both safety and image quality.

**Index term:** Interventional instruments, coils

Increasingly, transcatheter interventional techniques are being used to treat neurovascular disorders. One recent advance is the Guglielmi detachable coil, used clinically in the treatment of intracranial aneurysms since 1990 (1, 2). Given the potential widespread application of this device and the increasing use of magnetic resonance (MR) imaging, investigation of the safety of Guglielmi detachable coils and the imaging artifact produced by them is warranted.

Numerous intravascular devices have been evaluated (3–6) for their ferromagnetism, susceptibility to magnetic torque, and predisposition to MR imaging artifacts. While different devices may produce varying degrees of artifact and torque, two varieties of platinum embolization microcoils investigated by Marshall et al (7) showed no ferromagnetic properties and hence posed no significant risk of torque, migration, or artifact production during MR imaging.

Another concern when imaging metallic devices stems from the potential for time-varying magnetic fields to induce current flow in a conductor if sufficient voltage is present relative to the resistance of the conductor, and the heat thus generated poses at least a theoretical threat to surrounding tissue. Although the risk

has been shown to be minimal (8–11), instances of clinically significant heating have occurred (12, 13).

In this study, the magnetic deflection characteristics, heat production, and MR appearance of Guglielmi detachable coils were evaluated with in vitro studies and with the experiences of eight patients who had intracranial placement of these coils and who underwent subsequent MR imaging.

## Materials and Methods

### *Ferromagnetism*

Guglielmi detachable coils consist of a distal portion of soft coiled platinum wire attached to a soft stainless steel coil, which is then attached more proximally to a stainless steel core wire (1). The ferromagnetism of the devices was tested using a method described previously (14). Five coils were suspended as a group by nonferromagnetic thread of negligible mass (8–0 nylon suture, Ethicon Inc, Somerville, NJ) at various points from the portal of a 1.5-T MR imaging unit to deep within the unit and were observed for 2 minutes at each location for any deflection. The amount of deflection from vertical, if any, was measured with a protractor. The orientation of the suspended coils was then changed to approximately 90° from their initial orientation and the coils were again observed for 2 minutes at each location to assess for any rotational motion. In addition, groups of up to five coils were placed on a clean glass slide at multiple locations at 6-inch increments from the portal to deep within the unit with three different orientations at each location to further assess for any realignment within the field.

### *Heat Production*

The Guglielmi detachable coils were placed in 2 mL of saline solution within a capped glass vial (internal diameter of 1.1 cm) and imaged using a radio frequency transmit-receive coil specifically designed for head imaging.

---

Received June 30, 1994; accepted after revision April 25, 1996.

From the Departments of Surgery (J.H.) and Radiology (T.N., D.L., G.P.T.), University of California at San Francisco Medical Center.

Address reprint requests to J. Hartman, MD, Department of Radiology, Beth Israel Medical Center, First Ave at 16th St, New York, NY 10003.

AJNR 18:497–501, Mar 1997 0195-6108/97/1803-0497 © American Society of Neuroradiology

Effect of MR imaging on temperature of five Guglielmi detachable coils in saline measured in vitro\*

Coil	Control†	Fast Spin-Echo Sequence (2500/110)	GRASS Sequences (500/13)	
			7° Flip Angle	67° Flip Angle
1	-0.2	-0.1	-0.2	-0.2
2	0.0	-0.1	-0.1	0.0
3	-0.1	-0.1	-0.1	0.0
4	0.0	-0.1	0.0	+0.1
5	-0.1	-0.3	0.0	+0.1
Mean ± SD	-0.08 ± 0.08	-0.14 ± 0.08	-0.08 ± 0.08	0.0 ± 0.11

\* All values are in degrees centigrade. Measurements are of the difference between the alteration in temperature of the coils in saline after MR imaging and the alteration in temperature of the saline controls after MR imaging.

† Control indicates measurement with no imaging performed.

The coils in the vial were aligned such that their longitudinal axis was parallel to the axis of the scanner to maximize heating effects. Five other vials containing an equal volume of saline solution but no coils were imaged simultaneously as controls. The vials and the coils were allowed to equilibrate to room temperature for at least 6 hours before imaging. Temperature was measured immediately before and immediately after imaging with the thermocouple probe of a digital thermometer sensitive to 0.1°C (John Fluke Manufacturing Co, Everett, Wash). All vials were imaged in a nonferromagnetic polystyrene insulator to minimize any potential heat dissipation. The imaging sequences used were fast spin-echo with T2-weighting (2500/110/2 [repetition time/echo time/excitations]) and fast spoiled gradient-recalled acquisition in the steady state (GRASS; 500/13/2) with flip angles of 7° and 67°.

#### Magnetic Susceptibility Artifact in Vitro

To evaluate the degree to which Guglielmi detachable coils produce magnetic susceptibility artifacts, the coils were placed in a capped plastic vial containing saline solution and imaged with conventional spin-echo T1-weighted (500/16/2), fast spin-echo proton density-weighted (2100/19/2) and T2-weighted (3500/95/2), and inversion recovery (10000/154/4; inversion time, 2300) sequences. All imaging was performed with a 256 × 192 matrix and 5-mm-thick sections. In addition, a three-dimensional time-of-flight gradient-echo sequence was used (48/5.4/1; flip angle, 20°) to evaluate for any artifact produced with these particular imaging parameters; although, naturally, no flow would be expected within this system. Three-dimensional time-of-flight imaging was performed with a section thickness of 0.7 mm with a matrix of 512 × 192.

#### Magnetic Susceptibility Artifact in Vivo

Eight patients with acute or subacute neurologic symptoms relating to rupture or mass effect of an intracranial aneurysm underwent therapeutic placement of Guglielmi detachable coils and were followed up with MR imaging as clinically indicated. In all cases, a 1.5-T MR imaging unit was used with a section thickness of 5 mm and a matrix size of 256 × 256.

## Results

When placed in the magnetic field, the Guglielmi detachable coils showed no magnetic deflection; that is, the angle of deflection of the suspended coils was zero at all locations, indicative of nonmeasurable force exertion upon the coils. Moreover, there was no evidence of rotational force on the suspended coils or on the coils placed on a glass slide within the MR unit.

No significant difference in temperature was measured between the vial containing the Guglielmi detachable coils and the control vials containing saline solution only (Table). Altering the flip angle of the GRASS sequence from 7° to 67° had no effect on temperature.

In vitro, the coils produced minimal artifact on all imaging sequences (Fig 1), seen as a thin, approximately 1-mm-diameter rim of high signal intensity immediately adjacent to the coil. The amount of artifact produced was comparable on all sequences tested.

None of the eight patients who underwent MR imaging suffered any untoward effect, neurologic change, or headache during or immediately after the imaging studies. The degree of artifact seen in vivo was minimal, observed as a rim of increased intensity adjacent to an area of signal void, with obscuration of approximately 2 to 3 mm of surrounding brain parenchyma. As demonstrated in a representative case, the degree of artifact was similar for both T1-weighted (Fig 2A) and T2-weighted (Fig 2B) spin-echo sequences. Plain radiographic and angiographic studies are provided for comparison (Fig 2C and D, respectively).

## Discussion

Although some intracranial therapeutic devices such as aneurysm clips carry a risk of movement with potentially fatal consequences

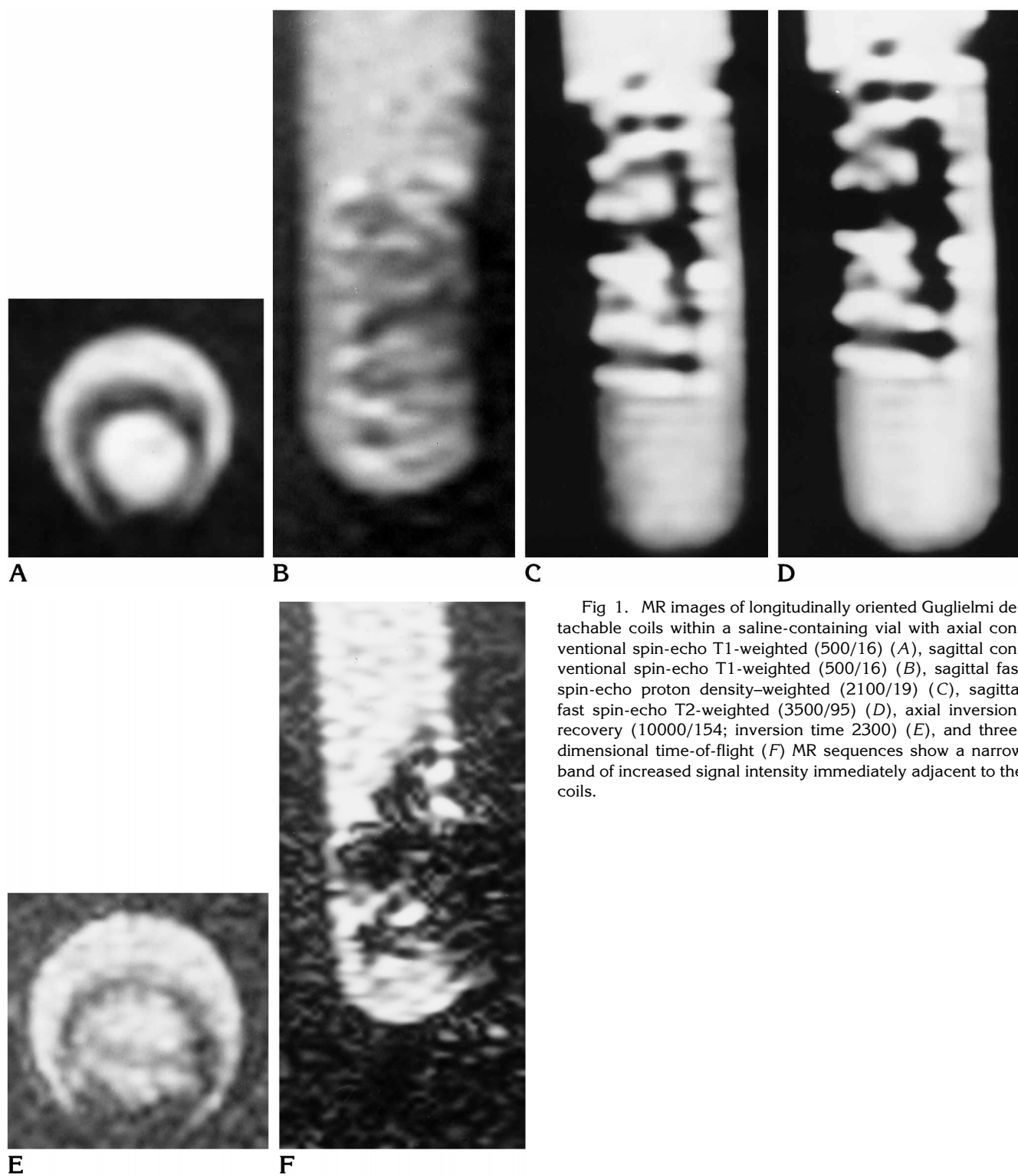


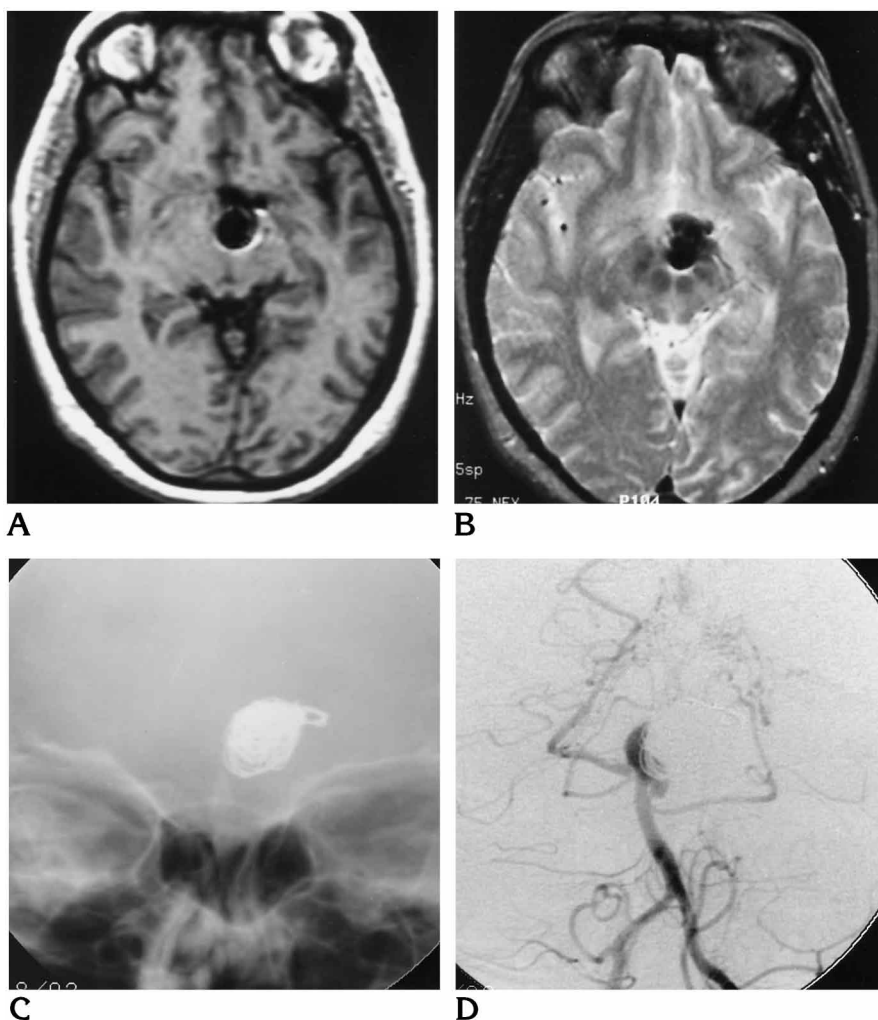
Fig 1. MR images of longitudinally oriented Guglielmi detachable coils within a saline-containing vial with axial conventional spin-echo T1-weighted (500/16) (A), sagittal conventional spin-echo T1-weighted (500/16) (B), sagittal fast spin-echo proton density-weighted (2100/19) (C), sagittal fast spin-echo T2-weighted (3500/95) (D), axial inversion-recovery (10000/154; inversion time 2300) (E), and three-dimensional time-of-flight (F) MR sequences show a narrow band of increased signal intensity immediately adjacent to the coils.

Fig 2. A, Axial T1-weighted (616/16) MR image of a representative case shows a 2- to 3-mm rim of increased signal intensity around Guglielmi detachable coils placed within a basilar tip aneurysm in a 42-year-old woman.

B, Axial T2-weighted (2500/80) MR image of the same patient shows a similar degree of artifact.

C, Anteroposterior view of the head of the same patient shows the plain film appearance of the Guglielmi detachable coil.

D, Anteroposterior view of the head from a left vertebral artery angiogram of the same patient shows approximately 75% occlusion of the aneurysm.



when subjected to the magnetic field of MR imaging (15), the Guglielmi detachable coils we studied exhibited no such movement when placed in a 1.5-T field. Furthermore, there was no appreciable heat production during imaging of vials containing these coils as compared with control vials containing no coils, even when imaging sequences with large radio frequency pulse flip angles were used, which result in relatively greater power deposition.

The magnetic susceptibility artifact that limits the effectiveness of MR imaging as a technique for following up pathologic conditions treated with ferromagnetic devices such as steel embolization coils (3, 4) is not seen to the same degree with the platinum Guglielmi detachable coil. Although some artifact is noted, it is minimal and does not detract significantly from the ability to scrutinize the area surrounding the coils. Finally, none of the patients in this series treated with Guglielmi detachable coils dis-

played any symptoms during or immediately after MR imaging. Thus, placement of these devices for embolization of vascular central nervous system lesions does not preclude the safe and effective use of MR imaging.

## References

1. Guglielmi G, Vinuela F, Sepetka I, Macellari V. Electrothrombosis of saccular aneurysms via endovascular approach, 1: electrochemical basis, technique, and experimental results. *J Neurosurg* 1991;75:1-7
2. Guglielmi G, Vinuela F, Dion J, Duckwiler G. Electrothrombosis of saccular aneurysms via endovascular approach, 2: preliminary clinical experience. *J Neurosurg* 1991;75:8-14
3. Teitelbaum GP, Bradley WG Jr, Klein BD. MR imaging artifacts, ferromagnetism, and magnetic torque of intravascular filters, stents, and coils. *Radiology* 1988;166:657-664
4. Bernardino ME, Steinberg HV, Pearson TC, Gedgaudas-McClees RK, Torres WE, Henderson JM. Shunts for portal hypertension: MR and angiography for determination of patency. *Radiology* 1986;158:57-61
5. Teitelbaum GP, Raney M, Carvlin MJ, Matsumoto AH, Barth KH. Evaluation of ferromagnetism and magnetic resonance imaging

- artifacts of the Strecker tantalum vascular stent. *Cardiovasc Intervent Radiol* 1989;12:125-127
6. Shellock FG, Morisoli S, Kanal E. MR procedures and biomedical implants, materials, and devices: 1993 update. *Radiology* 1993;189:541-550
  7. Marshall MW, Teitelbaum GP, Kim HS, Deveikis J. Ferromagnetism and magnetic resonance artifacts of platinum embolization microcoils. *Cardiovasc Intervent Radiol* 1991;14:163-166
  8. Davis PL, Crooks L, Arakawa M, McRee R, Kaufman L, Margulis AR. Potential hazards in NMR imaging: heating effects of changing magnetic fields and RF fields on small metallic implants. *AJR Am J Roentgenol* 1981;137:857-860
  9. Mark AS, Hricak H. Intrauterine contraceptive devices: MR imaging. *Radiology* 1987;162:311-314
  10. Buchli R, Boesiger P, Meier D. Heating effects of metallic implants by MRI examinations. *Magn Reson Med* 1988;7:255-261
  11. Kanal E, Shellock FG, Talagala L. Safety considerations in MR imaging. *Radiology* 1990;176:593-606
  12. Hall SC, Stevenson GW, Suresh S. Burn associated with temperature monitoring during magnetic resonance imaging. *Anesthesiology* 1992;76:152
  13. Brown TR, Goldstein B, Little J. Severe burns resulting from magnetic resonance imaging with cardiopulmonary monitoring: risks and relevant safety precautions. *Am J Phys Med Rehabil* 1993;73:166-167
  14. New PFJ, Rosen BR, Brady TJ, et al. Potential hazards and artifacts of ferromagnetic and nonferromagnetic surgical and dental materials and devices in nuclear magnetic resonance imaging. *Radiology* 1983;147:139-148
  15. Klucznik RP, Carrier DA, Pyka R, Haid RW. Placement of a ferromagnetic intracerebral aneurysm clip in a magnetic field with fatal outcome. *Radiology* 1993;187:855-856