



**Providing Choice & Value**

Generic CT and MRI Contrast Agents



**FRESENIUS  
KABI**

**CONTACT REP**

**AJNR**

**Diffusion into human intervertebral disks  
studied with MR and gadoteridol.**

G Akansel, V M Haughton, R A Papke and S Censky

*AJNR Am J Neuroradiol* 1997, 18 (3) 443-445

<http://www.ajnr.org/content/18/3/443>

This information is current as  
of July 29, 2025.

# Diffusion into Human Intervertebral Disks Studied with MR and Gadoteridol

Gur Akansel, Victor M. Haughton, R. Anne Papke, and Steve Censky

**PURPOSE:** To determine the feasibility of measuring diffusion into human intervertebral disks by means of MR imaging with an intravenous nonionic gadolinium complex (gadoteridol). **METHODS:** In 18 patients undergoing lumbar spine MR imaging, signal intensity was measured in the intervertebral disks after a dose of 0.1 mmol/kg and after a supplemental dose of 0.2 mmol/kg. **RESULTS:** Signal intensity in the intervertebral disks increased with both gadoteridol doses. A greater increase was consistently achieved with the 0.3 mmol/kg (total) dose than with the 0.1 mmol/kg dose. The increase was greater near the endplates than in the midportion of the disk. **CONCLUSION:** Diffusion into human intervertebral disks can be detected with MR imaging after intravenous administration of gadoteridol. MR imaging with a paramagnetic contrast medium can be used to study diffusion into disk cartilage in vivo and noninvasively.

**Index terms:** Magnetic resonance, contrast enhancement; Spine, intervertebral disks; Spine, magnetic resonance

*AJNR Am J Neuroradiol* 18:443–445, March 1997

Although the normal human intervertebral disk does not enhance with intravenous gadolinium complexes (1), magnetic resonance (MR) imaging studies with paramagnetic contrast media in experimental animals have shown gradually increasing signal intensity in disk cartilage due to the diffusion of contrast medium from the adjacent vertebra into the disk (2–4). In some conditions (eg, the pediatric intervertebral disk), sufficient diffusion takes place that enhancement can be detected by visual inspection (5). Since metabolites reach the disk cartilage by diffusion, MR imaging with gadolinium complexes may be a noninvasive way to study their diffusion into the disk. Studying diffusion may help us to measure the process by which oxygen (6), glucose (7), and other solutes (8–12) are transported to the disk and to understand the pathogenesis of disk degeneration. In this study, we measured the sig-

nal intensity of normal intervertebral disks in a group of patients receiving a nonionic contrast medium in conventional doses. Our purpose was to determine the feasibility of measuring diffusion into healthy human intervertebral disks with conventional doses of an intravenously administered nonionic gadolinium-containing chelate (gadoteridol).

## Materials and Methods

Between March 1994 and September 1995, 10 men and five women (23 to 68 years old; mean, 36 years) had lumbar spine MR imaging with gadoteridol (ProHance, Bracco Diagnostics, Inc; Princeton, NJ). All patients were being treated for continuing back pain after lumbar laminectomy for lumbar disk disease, and were examined by MR imaging as part of a phase IV Food and Drug Administration study to compare enhancement with 0.1 mmol/kg versus 0.3 mmol/kg intravenous gadoteridol. Each patient was imaged in a 0.5-T MR scanner before administration of contrast medium, after 0.1 mmol/kg intravenous gadoteridol, and after an additional 0.2 mmol/kg intravenous gadoteridol. Mean time from the 0.1 mmol/kg dose to the first sagittal image was 9.7 minutes and mean time from the injection of the additional 0.2 mmol/kg dose to the second sagittal image with contrast material was 5 minutes. Average time between the injections was 15 minutes. The sagittal images of the lumbosacral spine were acquired with the following parameters:

---

Received March 28, 1996; accepted after revision July 19.

From the Department of Radiology, Medical College of Wisconsin, Froedtert Hospital, 9200 W Wisconsin Ave, Milwaukee, WI 53226. Address reprint requests to Victor M. Haughton, MD.

AJNR 18:443–445, Mar 1997 0195-6108/97/1803-0443

© American Society of Neuroradiology

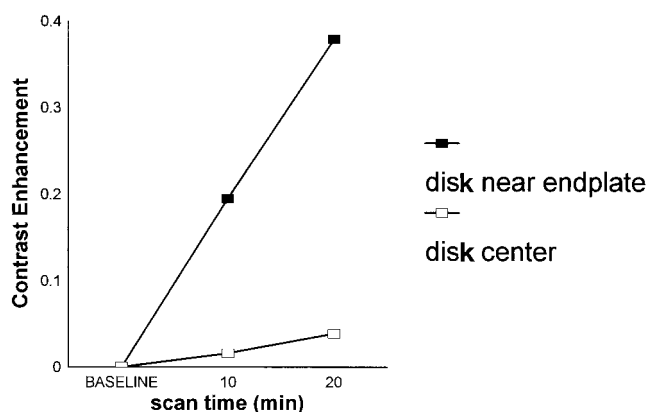


Fig 1. Contrast enhancement in normal human intervertebral disks as a function of time and dose of contrast material. The 10-minute measurement was obtained after a dose of 0.1 mmol/kg; the 20-minute measurement after a supplementary dose of 0.2 mmol/kg.

600/20/2 (repetition time/echo time/excitations), acquisition matrix of  $512 \times 256$ , section thickness of 5 mm, intersection spacing of 0.5 mm, and field of view of 28 mm. In two patients, parameters of 450/20/2 were substituted for 600/20/2. Transmit and receive factors were not adjusted between scans.

On midline sagittal images, the signal intensities of disks were measured at both superior and inferior endplates and in the middle zone of the normal intervertebral disks. The measurement was repeated for each disk on the images obtained after doses of 0.1 and 0.3 mmol/kg intravenous gadoteridol. Only disks with normal height and signal intensity by inspection on both T1- and T2-weighted fast spin-echo images, and with no evidence of bulging, herniation, or annular tear, were used in the tabulation. Contrast enhancement was calculated as the change in signal intensity from baseline divided by baseline signal intensity. Average enhancement after doses of 0.1 and 0.3 mmol/kg gadoteridol were compared and differences tested with a one-tailed *t* test, assuming unequal variances.

## Results

Eighteen disks in 15 patients met the criteria of normalcy. Contrast enhancement was not detected by visual inspection with either dose of gadoteridol in any of the disks. The increase over baseline after a 0.1 mmol/kg dose of gadoteridol was  $0.19 \pm 0.31$  at the endplates, and  $0.01 \pm 0.10$  for the mid zones. After the 0.2 mmol/kg supplementary dose, the average increase over baseline was  $0.37 \pm 0.48$  at the endplates and  $0.03 \pm 0.14$  centrally (Fig 1). The differences in signal intensity between the baseline and the first scan at the endplates, and between the first and second scans were signif-

icant at  $P < .02$ . The differences in signal intensity in the center of the disk between baseline and the second scan were not significant ( $P = .3$ ).

## Discussion

This study demonstrates that changes in signal intensity in the human intervertebral disks are detectable by measurement obtained after intravenous administration of gadoteridol, a nonionic gadolinium-containing chelate. A consistently greater increase in signal intensity is achieved with a 0.3 mmol/kg total dose at the endplates than with 0.1 mmol/kg. With both doses, the disk near the endplates shows greater change than do the midzone areas. Although increases in signal intensity were observed in the midzones from baseline to 0.1 mg/kg and from 0.1 to 0.3 mmol/kg doses, these changes did not reach statistical significance. Owing to the study design, enhancement data were available from only one time point for either gadoteridol dose. We could not determine how much of the increased signal intensity after the additional 0.2 mmol/kg dose of gadoteridol was due to time elapsed after the 0.1 mmol/kg dose alone and how much to the larger total dose. Surface coil inaccuracies and other nonlinearities may have affected the measurements. Only patients who had had back surgery were included in this study. In such a population, altered perfusion of spinal tissues or accelerated cartilage degeneration may be present.

In rabbit intervertebral disks, signal intensity increases progressively after intravenous injection of gadoteridol (3). When the signal intensity increases 25% above baseline, enhancement is detected by visual inspection. In our study, enhancement values remained below the 25% level in most patients, so contrast enhancement was not detected visually. Greater signal intensity changes would be detected if the postinjection images were acquired after greater delay. In the experimental animals, signal intensity increased for 2 hours after injection (3). Nonionic gadolinium complexes enter the disk cartilage at a faster rate than do ionic media, owing to more rapid diffusion (3). Therefore, greater changes in signal intensity are detected after injection of nonionic than ionic media. The changes in signal intensity in rabbit disks are dose related (4). MR imaging can be effective for studying diffusion into human intervertebral

disks, especially if images are obtained at regular intervals, for up to 2 hours after injection of a contrast medium, which is optimally nonionic, in a dose of 0.3 mmol/kg. Measurement of signal intensity change can be facilitated by use of higher field strengths, which are more sensitive to the effect of gadolinium complexes on T1 relaxation (13).

This study supports the hypothesis that gadolinium complexes reach the intervertebral disk cartilage by diffusion from endplates. With MR imaging, the effect of degenerative changes, spinal fusion, or trauma on diffusion can be studied. In particular, the hypothesis that diminished diffusion is a marker of early disk degeneration (14, 15) can be studied. In animals, iatrogenically produced disk degeneration is associated with diminished diffusion (15). Possibly, diffusion studies will help distinguish early degenerative changes from later invasion of the disk with granulation tissue, determine the effect of nicotine or other drugs on disk metabolism (16), and identify abnormal cartilage maturation (chondrodystrophy) that predisposes to disk degeneration (17).

## Acknowledgment

We acknowledge with gratitude Jane Harmeyer's assistance on this project.

## References

1. Breger RK, Williams AL, Daniels DL, et al. Contrast enhancement in spinal MR imaging. *AJNR Am J Neuroradiol* 1989;10:633-637
2. Smith JW, Walmsey R. Experimental incision of the intervertebral disc. *J Bone Joint Surg [Br]* 1951;33B:612-625
3. Ibrahim MA, Haughton VM, Hyde JS. Enhancement of intervertebral disks with gadolinium complexes: comparison of an ionic and nonionic medium in an animal model. *AJNR Am J Neuroradiol* 1994;15:1907-1910
4. Ibrahim MA, Jesmanowicz A, Hyde JS, Estkowski L, Haughton VM. Contrast enhancement of normal intervertebral disks: time and dose dependence. *AJNR Am J Neuroradiol* 1994;15:419-423
5. Sze G, Bravo P, Baieri P, Shimkin PM. Developing spinal column: gadolinium-enhanced MR imaging. *Radiology* 1991;180:497-502
6. Stairman JW, Holm S, Urban JPG. Factors influencing oxygen concentration gradients in the intervertebral disc: a theoretical analysis. *Spine* 1991;16:444-449
7. Maroudas A, Stockwell RA, Nachemson A, Urban JPG. Factors involved in the nutrition of the human lumbar intervertebral disc: cellularity and diffusion of glucose in vitro. *J Anat* 1975;120:113-130
8. Maroudas A. Distribution and diffusion of solutes in articular cartilage. *Biophys J* 1970;10:365-379
9. Maroudas A. Biophysical chemistry of cartilaginous tissues with special reference to solute and fluid transport. *Biorheology* 1975;12:233-248
10. Urban JPG, Holm S, Maroudas A, Nachemson A. Diffusion of small solutes into the intervertebral disc: an in vivo study of solute transport. *Clin Orthop* 1977;129:101-114
11. Urban JPG, Holm S, Maroudas A, Nachemson A. Diffusion of small solutes into the intervertebral disc: an in vivo study. *Biorheology* 1978;15:203-223
12. Urban JPG, Holm S, Maroudas A, Nachemson A. Nutrition of the intervertebral disc: effect of fluid flow on solute transport. *Clin Orthop* 1982;170:296-302
13. Lindsey RO, Yetkin FZ, Prost R, Haughton VM. Effect of dose and field strength on enhancement with paramagnetic contrast media. *AJNR Am J Neuroradiol* 1994;15:1849-1852
14. Maroudas A. Nutrition and metabolism of the intervertebral disc. In: Ghosh P, ed. *The Biology of the Intervertebral Disc*. Boca Raton, Fla: CRC, 1968;2:1-38
15. Nguyen CM, Riley L, Ho K-C, Xu R, An H, Haughton VM. Effect of degeneration of the intervertebral disk on the process of diffusion. *AJNR Am J Neuroradiol* 1997;18:435-442
16. Ghosh P. Influence of drugs, hormones and other agents on the metabolism of the disc and the sequelae of its degeneration. In: Ghosh P, ed. *The Biology of the Intervertebral Disc*. Boca Raton, Fla: CRC Press;1988:122-152
17. Hansen HJ. Comparative views on the pathology of disc degeneration in animals. *Lab Invest* 1959;8:1242-1259