



## Get Clarity On Generics

Cost-Effective CT & MRI Contrast Agents

 FRESENIUS  
KABI

[WATCH VIDEO](#)

# AJNR

This information is current as  
of August 11, 2025.

## **Choristomas of the seventh and eighth cranial nerves.**

M M Smith, J E Thompson, D Thomas, M Castillo, D Carrier, S K Mukherji and D Gilliam

*AJNR Am J Neuroradiol* 1997, 18 (2) 327-329

<http://www.ajnr.org/content/18/2/327>

---

# Choristomas of the Seventh and Eighth Cranial Nerves

Michelle M. Smith, Jill E. Thompson, David Thomas, Mauricio Castillo, David Carrier, Suresh K. Mukherji, and David Gilliam

**Summary:** Choristomas, masses of normal tissues in aberrant locations, contain smooth muscle fibers and fibrous tissues. We describe the MR imaging features of two choristomas located in the internal auditory canals and arising from the facial and vestibulocochlear nerves. Both lesions enhanced with contrast material. In one case, enhancement was seen in the geniculate ganglion and greater superficial petrosal nerve. In the other, a medial component enhanced less than the lateral component did.

**Index terms:** Nerves, neoplasms; Temporal bone, neoplasms

A choristoma is a lesion that contains histologically normal tissues in an ectopic location (1); a hamartoma, on the other hand, is composed of nonneoplastic proliferations of histologically normal tissues and occurs at sites where those tissues are normally found. We describe the magnetic resonance (MR) imaging features of two choristomas, one involving the seventh and one involving the eighth cranial nerve.

## Case Reports

### Case 1

A 63-year-old woman had a 5-year history of tinnitus and progressive right-sided hearing loss, which was confirmed at physical examination. She was otherwise in good health with no significant medical history and no facial paralysis. Audiometry revealed mild low-frequency and moderate mid- to high-frequency sensorineural hearing loss with decreased speech discrimination on the right. Noncontrast and contrast-enhanced MR images were obtained with 3-mm-thick axial and coronal sections through the internal auditory canals (IACs). The MR study showed a uniformly enhancing 6-mm mass deep within the right IAC, subtle enhancement of the geniculate ganglion, and enhancement of the fallopian portion of the right facial nerve (Fig 1A and B). Before surgery, the mass was presumed to be a small facial schwannoma. The patient was

offered surgical removal of the mass or conservative therapy and observation but she requested surgery and underwent right-sided retromastoid craniotomy. The tumor was adherent to the seventh cranial nerve, which was sacrificed. Two months after surgery, the patient was stable with a seventh nerve palsy and she underwent a hypoglossal-to-facial nerve anastomosis.

Examination of the frozen section revealed nerve ganglion and scar tissue. Light microscopy showed small bundles of myelinated fibers intermingled with ganglion cells, smooth muscle, collagenous tissue, and adipocytes. The presence of these elements was confirmed with trichrome stain. Immunohistochemical study showed positive reaction of actin and desmin in the bundles of smooth muscle fibers and positive reaction of S-100 in the nerve fibers. The histologic findings were compatible with choristoma of the seventh cranial nerve.

### Case 2

A 19-year-old woman had a 3-month history of progressive right-sided hearing loss. There was no vertigo or tinnitus. Audiometry revealed a 60-dB right-sided sensorineural hearing loss. Noncontrast and contrast-enhanced MR images with 3-mm-thick axial and coronal sections through the IACs showed a 5-mm homogeneously enhancing lesion deep within the right IAC (Fig 2A). The lesion was removed via retromastoid craniotomy, and the tumor was seen to arise from the cochlear nerve. Light microscopy revealed a tumor composed of ganglion cells, smooth muscle cells, and collagen. Vimentin, S-100, actin, and desmin immunostains confirmed the presence of these cell types (Fig 2B and C). The presence of collagen and smooth muscle components was further supported by trichrome staining (Fig 2D). The diagnosis was choristoma of the eighth cranial nerve.

## Discussion

Three reported choristomas have involved the optic nerves and chiasm, and a fourth the maxillary division of the fifth cranial nerve

---

Received November 30, 1995; accepted after revision March 19, 1996.

From the Department of Radiology (M.M.S., J.E.T., M.C., S.K.M.) and the Division of Neuropathology (D.T.), University of North Carolina School of Medicine, Chapel Hill, and Wilford Hall Hospital, Lackland Air Force Base, San Antonio, Tex (D.C., D.G.).

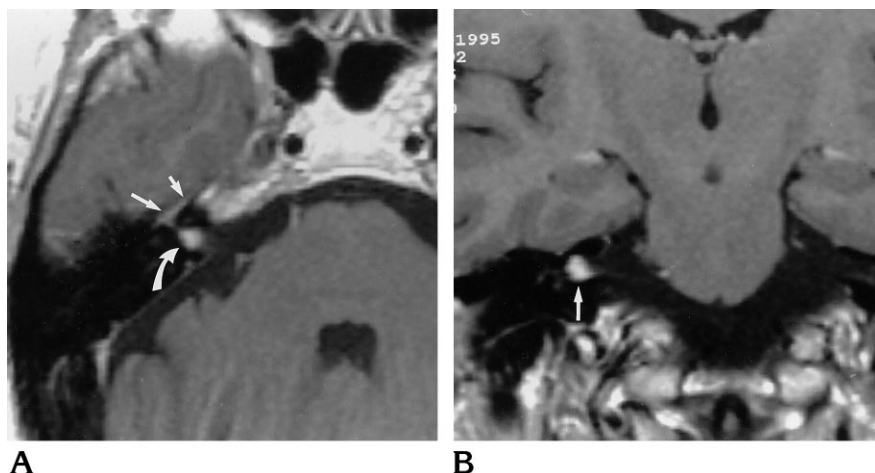Address reprint requests to M. Castillo, MD, Department of Radiology, CB 7510, University of North Carolina, Chapel Hill, NC 27599.

AJNR 18:327-330, Feb 1997 0195-6108/97/1802-0327 © American Society of Neuroradiology

Fig 1. Case 1: 63-year-old woman with 5-year history of tinnitus and progressive right-sided hearing loss.

A, Axial contrast-enhanced T1-weighted (500/15/2 [repetition time/echo time/excitations]) MR image shows 6-mm homogeneously enhancing mass (*curved arrow*) deep in the right IAC. There is enhancement of the geniculate ganglion (*larger straight arrow*) and the greater superficial petrosal nerve (*smaller straight arrow*).

B, Coronal contrast-enhanced T1-weighted MR image shows the mass (*arrow*).



(1–3). Our cases showed histologic features identical to those previously reported for choriomas of the second and fifth nerves, which contained neural tissues from the involved cranial nerve, varying amounts of fibrous tissue, and mature smooth muscle cells. Choriomas containing mature smooth muscle cells have also been reported in ocular structures, including the choroid and ciliary body (4, 5). The cranial nerve choriomas presented here are histologically different from those occurring in the neurohypophysis and infundibular stalk. Pituitary stalk choriomas are also known as granular cell tumors, and are thought to arise from pituicyte progenitor cells (6). Histologically, these tumors contain cells with abundant PAS-positive cytoplasmic granules and foci of perivascular lymphocytes. Granular cell tumors may also occur in the cerebral hemispheres, cranial nerves, third ventricle, and spinal cord meninges (6). Cranial nerve choriomas are also histologically different from the neuromuscular hamartomas, or benign “triton” tumors. Neuromuscular hamartomas arise in the major peripheral nerves and are composed of nerve fibers, fibrous tissue, and well-differentiated striated muscle fibers (7).

The differential diagnosis of an enhancing mass in the fundus of an IAC includes mainly vestibular schwannoma, which is the most common tumor in this location. Primary neurogenic neoplasms involving the facial nerve are rare. The majority of primary tumors of the facial nerve are schwannomas (8). Secondary involvement of the facial nerve by a surrounding neoplasm is much more common. The clinical presentation of tumors of the IAC is variable and includes primarily facial nerve dysfunction,

hearing loss, facial pain or otalgia, and tinnitus (9). Sensorineural hearing loss occurs as a result of pressure on the auditory nerve within the bony confines of the IAC. The facial nerve is more resistant to pressure effects than is the auditory nerve. Thus, a tumor arising from the facial nerve may cause signs and symptoms related only to the eighth cranial nerve and spare the seventh nerve (10).

Contrast-enhanced MR imaging is the study of choice for evaluation of tumors arising in the IAC. Our two patients had imaging findings identical to those of schwannomas arising from either the seventh or eighth cranial nerves. Both tumors enhanced homogeneously after administration of contrast material; however, both were located deep within the IAC. The only effective treatment for facial nerve tumors is surgical removal (10). Because of their benign histologic features and despite the curative results of complete resection, significant morbidity may be seen postoperatively, including facial nerve palsy and hearing loss due to trauma to the eighth cranial nerve. Additional morbidity may result if the tumor involves the area of the geniculate ganglion, which requires intracranial exposure of the labyrinthine segment of the nerve (10).

In summary, choriomas are rare tumors that may arise in the cranial nerves and are indistinguishable from the more common schwannomas by MR imaging. These benign tumors are histologically distinguishable from the neuromuscular hamartoma of major peripheral nerves and the granular cell chorioma of the pituitary infundibulum. At present, the natural course of these rare tumors is unknown; how-

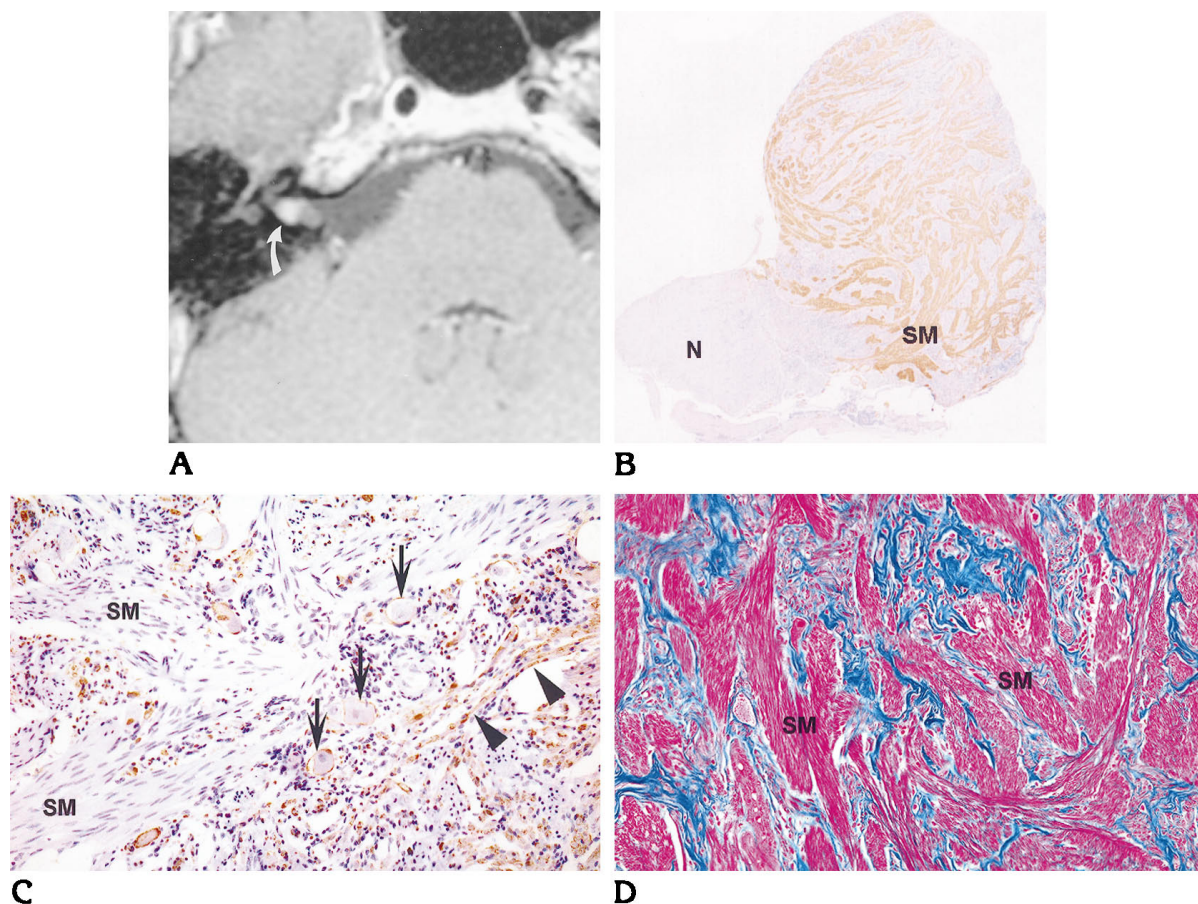


Fig 2. Case 2: 19-year-old woman with 3-month history of progressive right-sided hearing loss, but without vertigo or tinnitus.

A, Axial contrast-enhanced T1-weighted (500/15/1) MR image shows a 5-mm enhancing mass (arrow) deep within the right IAC. There is a questionable medial component to the mass that shows less enhancement than the lateral component.

B, Photomicrograph of histologic section at low magnification shows positive immunoreactivity in mature smooth muscle bundles (SM, brown staining) to actin immunostain. The tumor is the larger mass adherent to a normal-appearing eighth cranial nerve (N).

C, Photomicrograph of histologic section at high magnification shows positive immunoreactivity in nerve fibers (arrowheads, brown staining) to S-100 immunostain. Peripheral reactivity is seen in ganglion cells (arrows). Mature smooth muscle (SM) cell bundles are seen throughout the specimen.

D, High-magnification photomicrograph with trichrome stain shows mature smooth muscle tissue (SM, pink staining) among blue staining, representing nerve and collagen tissues.

ever, complete surgical resection is curative and no further adjuvant therapy is needed.

## References

1. Kazim M, Kennerdell J, Maroon J, Rothfus W, Marquardt M. Choristoma of the optic nerve and chiasm. *Arch Ophthalmol* 1992; 110:236–238
2. Zimmerman L, Arkfeld D, Schenken J, et al. A rare choristoma of the optic nerve and chiasm. *Arch Ophthalmol* 1983;101:766–770
3. Lena G, Dufour T, Gambarelli D, et al. Choristoma of the intracranial maxillary nerve in a child. *J Neurosurg* 1994;81:788–791
4. Jakobeic FA, Iwamoto T. Mesectodermal leiomyoma of the ciliary body associated with a nevus. *Arch Ophthalmol* 1978;96:692–695
5. Peter J, Ezra B. Heterotopic smooth muscle in the choroid of two patients with cryptophthalmos. *Arch Ophthalmol* 1970; 104:1665–1670
6. Burger PC, Scheithauer BW, Vogel FS. Region of the sella turcica. In: *Surgical Pathology of the Nervous System and Its Coverings*. New York: Churchill Livingstone; 1991:550–554
7. Chen K. Neuromuscular hamartoma. *J Surg Oncol* 1984;26:158–160
8. Batsakia J. Tumors of the peripheral nervous system. In: *Tumors of the Head and Neck*. Baltimore: Williams & Wilkins; 1979:322
9. Horn K, Crumley R, Schindler R. Facial neurilemmomas. *Laryngoscope* 1981;91:1326–1331
10. Pillsbury H, Price H, Gardiner L. Primary tumors of the facial nerve: diagnosis and management. *Laryngoscope* 1983;93:1045–1048