



Get Clarity On Generics

Cost-Effective CT & MRI Contrast Agents

 FRESENIUS
KABI

WATCH VIDEO

AJNR

Changes in blood flow velocity and diameter of the middle cerebral artery during hyperventilation: assessment with MR and transcranial Doppler sonography.

J M Valdueza, J O Balzer, A Villringer, T J Vogl, R Kutter and K M Einhäupl

This information is current as of August 4, 2025.

AJNR Am J Neuroradiol 1997, 18 (10) 1929-1934
<http://www.ajnr.org/content/18/10/1929>

Changes in Blood Flow Velocity and Diameter of the Middle Cerebral Artery during Hyperventilation: Assessment with MR and Transcranial Doppler Sonography

José Manuel Valdueza, Jörn Oliver Balzer, Arno Villringer, Thomas Josef Vogl, Raphael Kutter, and Karl Max Einhäupl

PURPOSE: To compare blood flow velocity changes within the middle cerebral artery (MCA) during hyperventilation, as measured with by both transcranial Doppler sonography and MR imaging, with the diameter of the MCA as measured with MR imaging alone. **METHODS:** The studies were performed in six healthy volunteers ranging in age from 22 to 31 years (mean, 27 years). Transcranial Doppler sonography was carried out with a range-gated 2-MHz transducer. MR examinations were done on a 1.5-T imaging unit. MR angiography was performed using the time-of-flight technique. MR flow measurements were carried out by using the phase-mapping technique with an ECG-triggered phase-contrast sequence. **RESULTS:** During hyperventilation, the mean blood flow velocity of the proximal MCA declined by $49.6\% \pm 5.7$ (mean \pm standard deviation) as measured with Doppler sonography, and by $47\% \pm 4.6$ as measured with MR flow calculation. The diameter of the MCA (3.4 ± 0.3 mm) remained unchanged on MR imaging studies (3.3 ± 0.3 mm). **CONCLUSION:** We found a good correlation between relative flow velocity changes measured by transcranial Doppler sonography and MR techniques. MR imaging revealed no significant changes in the diameter of the proximal MCA during normal versus hyperventilation. Relative changes in flow velocity in the MCA would thereby reflect relative changes in cerebral blood flow, at least during hyperventilation.

Index terms: Arteries, cerebral, middle; Cerebral blood flow; Magnetic resonance, flow studies; Ultrasound, Doppler

AJNR Am J Neuroradiol 18:1929–1934, November 1997

Transcranial Doppler sonography has proved to be a suitable noninvasive technique for measuring cerebral blood flow (CBF) velocity in the large cerebral basilar arteries (1). Since the advent of transcranial Doppler sonography, the question of its reliability in evaluating relative changes in CBF has led to much discussion. It has been widely used as a relative indicator of changes in CBF, with the assumption that velocity changes are directly related to variations

in CBF. Studies revealing an intimate relationship between changes in mean blood flow velocity V_{\max} (the time-averaged mean over the cardiac cycle of the spectral outline) in the middle cerebral artery (MCA) and CBF (2–4), as well as the observation that the diameter of the large basilar arteries during angiography is constant during Paco_2 variations (5), have supported this point of view. At constant flow velocity, CBF is proportional to the square of the arterial diameter. Therefore, concern over the validity of the transcranial Doppler sonographic technique has centered on whether basal artery diameters remain stable during insonation, since significant diameter changes could critically alter the relationship between relative changes in flow and relative changes in velocity (6). Direct visualization of the large basilar arteries, recently performed during neurosurgical procedures, has excluded pronounced changes in caliber during fluctuating Paco_2 and blood

Received November 11, 1996; accepted after revision April 29, 1997.

From the Department of Neurology, University Hospital Charité, Humboldt University, Berlin (J.M.V., A.V., K.M.E.), and the Department of Radiology, Virchow Clinic, Humboldt University Berlin (J.O.B., T.J.V., R.K.), Germany.

Address reprint requests to José Manuel Valdueza, MD, Department of Neurology, University Hospital Charité, Schumannstraße 20/21, 10117 Berlin, Germany.

AJNR 18:1929–1934, Nov 1997 0195-6108/97/1810–1929

© American Society of Neuroradiology

pressure. Interpretation of these results, however, has been somewhat limited, owing to study design (7).

The purpose of the present study was to compare blood flow velocity changes in the MCA during hyperventilation, as measured by transcranial Doppler sonography and magnetic resonance (MR) flow measurements, and to concomitantly examine the diameter of the MCA in the M1 segment by MR techniques in six healthy volunteers.

Subjects and Methods

Six healthy volunteers, five men and one woman (22 to 31 years old; mean, 27 years), were studied with both transcranial Doppler sonography and MR imaging techniques. Before the examinations, all volunteers gave written consent to participate in the study. Hyperventilation was performed by each person for a period of 3 minutes after initial values were determined either by transcranial Doppler sonography or MR imaging techniques.

Transcranial Doppler Sonography

Transcranial Doppler sonography was performed in the supine position, using a range-gated 2-MHz transducer (Multidop-X, Firma Elektronische Systeme GmbH DWL, Germany). The proximal M1 segment of the MCA was located at a depth of approximately 50 mm via a trans-temporal approach. V_{\max} was recorded automatically in centimeters per second during rest and during a 3-minute period of hyperventilation using a hand-held probe. To duplicate the hyperventilation technique in the settings of transcranial Doppler sonography and MR imaging, the breathing rate was adjusted to a steady-state level of V_{\max} , which was reached, after an initial drop, within several seconds. Blood pressure, heart rate, and capillary blood gas analysis were obtained at rest and at the end of hyperventilation.

MR Imaging Techniques

MR examinations were carried out on a 1.5-T MR unit equipped with a circular polarized head coil of 30-cm diameter. A standard examination protocol was used for all volunteer examinations as follows. After a sagittal survey, T1-weighted spin-echo images were obtained in both sagittal and transverse planes with parameters of 690/15/2 (repetition time/echo time/excitations), 23 sections, 3-mm section thickness, 256×512 matrix, and 200-mm field of view (FOV) covering the midbrain. Additionally, arterial time-of-flight MR angiography of the circle of Willis was performed by employing a tilted optimized nonsaturating excitation sequence with parameters of 40/8, a 20° flip angle, a 256×512 matrix, and a 200-mm FOV (8). This MR angiographic data set was postprocessed using the maximum intensity projection (MIP) algorithm to ob-

tain fully rotatable projection angiograms in two orientation planes. These sequences were used to ascertain the exact location of the course of the MCA.

To document hyperventilation and measure intravascular flow velocities, we performed MR flow measurements both before and during the hyperventilation process, employing the phase-mapping technique with an ECG-triggered phase-contrast sequence (34/6/6), 20° flip angle, one section, 6-mm section thickness, 256×256 matrix, and 180-mm FOV. Dependent on the heart rate, 122 ± 18 (mean \pm standard deviation) images were acquired in a plane perpendicular to the course of the M1 segment of the MCA. For each volunteer, two MR flow measurements were performed, one before and the other during the hyperventilation period. Each MR flow measurement data set included 122 ± 18 images (61 ± 9 anatomic images; 61 ± 9 phase images).

During MR examination, all volunteers were monitored for blood pressure, heart rate, and oxygen saturation. Hyperventilation was ensured by a significant reduction in V_{\max} in all subjects and by blood gas analysis in two cases.

Evaluation of the MR examination included determining the smallest vessel diameter of the MCA in the M1 segment on T1-weighted images, on the MR angiographic data set, on the MIP angiograms, and on the MR flow images before and during hyperventilation. All anatomic MR flow images (61 ± 9) from one data set were included for the determination of vessel diameter before and during hyperventilation. The obtained vessel diameter of one MR flow data set was summed up (30 for every subject) and the mean vessel diameter was determined. All vessel diameters were examined at a magnification factor of 2.0 in order to improve the delineation of vessel borders. The displayed diameters were interpolated by the evaluation program, resulting in more accurate measurements of vessel diameter than possible by imaging parameters alone. The smallest difference in vessel size reported by the program was 0.1 mm.

The maximal velocity (V_{\max}) was calculated from the fastest blood velocity in the lumen centerline.

For purposes of statistical evaluation, paired *t* tests were performed. A *P* value less than .05 was regarded as significant.

Results

The Table summarizes the physiological and experimental data of our study. Measurements of systolic and diastolic blood pressure and heart rate were not statistically different after hyperventilation; however, Paco_2 declined significantly ($P < .001$).

Typical MCA signals were found on both sides in all six healthy volunteers. For recording purposes, the side revealing the most prominent signal was chosen (the right side four times, and the left side two times). V_{\max} ranged

Data before and during hyperventilation in six healthy subjects

	Before Hyperventilation	During Hyperventilation
Transcranial Doppler Sonography		
Systolic blood pressure, mm Hg	120 \pm 7.6	116.7 \pm 6.9
Diastolic blood pressure, mm Hg	78.3 \pm 4.7	77.5 \pm 3.8
Heart rate, beats/min	60.7 \pm 6.7	64.7 \pm 6.7
Paco ₂ , mm Hg	39.8 \pm 1.3	26.6 \pm 2.7*
V _{max} , cm/s	73.7 \pm 13.3	37.6 \pm 10.6*
Mean % change in V _{max}		49.6 \pm 5.7
MR flow measurement		
Systolic blood pressure, mm Hg	120.8 \pm 6.1	130 \pm 6.5
Diastolic blood pressure, mm Hg	79.2 \pm 1.9	83.3 \pm 2.4
Heart rate, beats/min	64.7 \pm 5.7	72 \pm 6.6
Paco ₂ , mm Hg (n = 2)	39.4 \pm 0.4	27.4 \pm 1.5*
V _{max} , cm/s	59.4 \pm 4.1	31.4 \pm 3.9*
Mean % change in V _{max}		47.3 \pm 4.6
Diameter, mm	3.4 \pm 0.3	3.3 \pm 0.3
Mean % change in diameter		1.0 \pm 1.4

Note.—Values are mean \pm standard deviation

* $P < .01$ by paired t test.

from 62 to 100 cm/s (73.7 ± 13.3 cm/s). Hyperventilation led to a rapid reduction in V_{max} within 10 to 20 seconds until a plateau of low V_{max} was reached, which remained essentially unchanged during continued hyperventilation. The decrease in V_{max} was highly significant ($P < .001$), revealing a range from 29 to 60 cm/s (37.6 ± 10.6 cm/s). The percentage of decrease ranged from 40% to 60% ($49.6\% \pm 5.7$). A typical recording during hyperventilation is shown in Figure 1.

Arterial MR angiography revealed a strong signal intensity in the main arterial vessels of the circle of Willis in all subjects. This facilitated the exact localization of the M1 segment and allowed an appropriate perpendicular placement of the MR flow section (Fig 2). Owing to ECG triggering of the phase-contrast sequence, the number of acquired images varied from 96 to 146, with an overall acquisition time of 2.0 to 3.2 minutes. Baseline blood flow velocities ranged from 53.5 to 65.4 cm/s, with an average of 59.4 ± 4.1 cm/s. In all volunteers, a significant decrease of intravascular flow velocity during the hyperventilation period was noticed. During hyperventilation, blood flow velocities ranged from 23.5 to 36.7 cm/s, with an average of $31.4 \text{ cm/s} \pm 3.9$. The average reduction of flow velocity measured by MR flow was $47.3\% \pm$

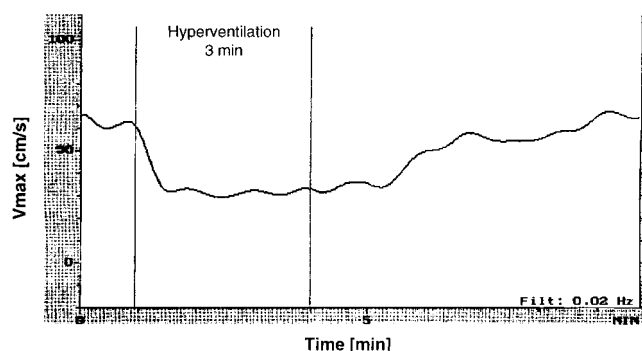


Fig 1. Scatterplot shows time course of decline in blood flow velocity in the MCA from 63 to 31.5 cm/s during hyperventilation in one volunteer. Recording is filtered at 0.02 Hz.

4.6 ($P = .002$). Mean MCA diameters before and during hyperventilation were not significantly changed in any subject (Fig 3).

Discussion

Transcranial Doppler sonography of the basilar arteries has become a well-established method for measuring blood flow velocity since it was introduced in 1982 (1). In the years thereafter, various attempts have been made to validate this technique as a tool for measuring relative changes in CBF. Markwalder et al (9) described an exponential increase in V_{max} associated with a rise in Paco₂. Later, Bishop et al (2) confirmed this by measuring V_{max} and CBF via intravenous xenon-133. In this study, V_{max} and hemispheric CBF showed no correlation at rest; however, a significant correlation was noted in response to hypercapnia. A similar relationship was reported by Lindegaard et al (3) and Newell et al (4). In patients who underwent carotid surgery, a significantly high correlation was found between V_{max} and flow volume in the exposed internal carotid artery (ICA) during changes of blood flow in the ICA, as measured by electromagnetic flowmetry. Upon normalization, mild differences between flow in the ICA and V_{max} in the MCA were related to a less than 5% decrease in the diameter of the MCA. Moreover, the reflected Doppler signal power has been used as an index of MCA diameter. By calculating flow measurements based on velocity indexes and signal power during experimentally induced flow variations, Aaslid et al (10) found a 1.1% change in MCA diameter.

An alternative approach for establishing the validity of transcranial Doppler sonography in the measurement of relative changes in CBF is

Fig 2. T1-weighted sagittal MR image (A) and axial MR angiogram (B) allow the exact location of the right MCA to be determined, with excellent visibility of the vessel course.

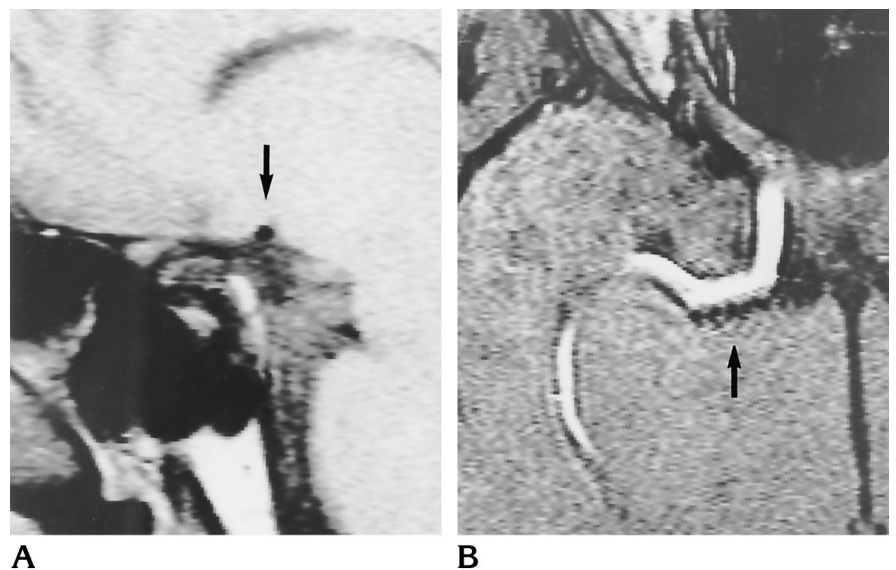
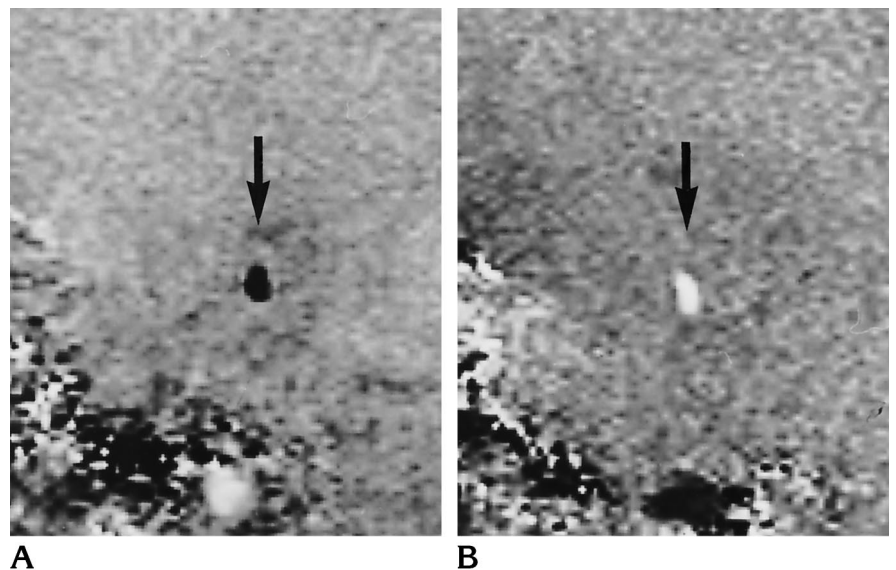


Fig 3. MR flow measurements show unchanged caliber of the MCA before (A) and during (B) hyperventilation. The bright signal intensity of the MCA during hyperventilation is due to slower blood flow. Hypocapnia was assured by reduction of blood flow velocity from 59.4 to 31.4 cm/s.



to demonstrate the lack of diameter change in the insonated vessels. A noninvasive method for measuring instantaneous changes in diameter of the large cerebral arteries would be the best solution.

The most cited publication favoring the view that the diameter of basal arteries in humans does not change during changes in P_{aCO_2} is that by Huber and Handa (5). These authors measured the diameters of the cerebral arteries under different conditions using an angiographic technique. In 10 patients, reactivity to hyperventilation was investigated while they were under general anesthesia. The vessels were di-

vided into five subgroups according to their diameter. Only the ICA revealed a caliber larger than 2.5 mm, whereas the diameter of the MCA was found to range from 1.5 to 2.5 mm, in most instances. During hyperventilation, a constant diameter was reported only for the ICA, whereas the MCA, defined as smaller than 2.5 mm, showed an 8.6% decline in diameter. Limitations of the study included the selection of patients and the use of general anesthesia, both of which may influence cerebral hemodynamics.

Giller et al (7) made the basilar arteries in humans directly visible during neurosurgical

procedures. They found changes in the diameter of the large basilar arteries, less than 4% in the MCA, during moderate variations of PaCO_2 and blood pressure. These findings were obtained in a selected group of patients who were under general anesthesia, and during exposure of the vessels to air. Therefore, these results may not be applicable to healthy awake subjects.

Arguments favoring a marked reactivity of the large basilar arteries have been presented by Bouma et al (11). In the experimental setting, using a closed window technique in cats, these authors reported a significant vasoconstriction of the basilar artery ($12.2\% \pm 7.6$ of the baseline diameter) and a corresponding decline in CBF during hyperventilation. The mean value of the cat basilar artery diameter was 0.5 mm. The experiments were performed with the animals under general anesthesia and after difficult surgical preparations, both of which might have influenced their results. The findings might suggest variations in the vasoreactivity of different species or indicate a general threshold of vasoreactivity that is dependent on vessel diameter.

In our study, involving six healthy young volunteers, V_{max} recorded by transcranial Doppler sonography ranged from 62 to 100 cm/s ($73.7 \text{ cm/s} \pm 13.3$), which is in agreement with the values reported in the literature (12–14). The decline of V_{max} after hyperventilation ($37.6 \text{ cm/s} \pm 10.6$) was within the known limits (15, 16). The diameters of the MCA measured by MR flow ranged from 2.9 to 3.7 mm ($3.4 \text{ mm} \pm 0.3$), which were within the usual range (17). No significant diminution of the diameter was seen after hyperventilation.

So far, MR flow measurements have been used primarily for the determination of flow velocity in normal or pathologically altered carotid arteries, and have shown excellent correlation with Doppler sonographic results (8, 18). Only a few groups have used MR flow to ascertain intracranial flow measurements (19, 20). Our study also showed excellent correlation with results of MR flow studies and transcranial Doppler sonography, both obtained under normal circumstances and physiological alterations. Blood flow velocities measured by transcranial Doppler sonography were found to be slightly higher than those measured by MR flow at rest and during hyperventilation. This difference in V_{max} is not expected, and cannot be explained by the fact that with transcranial Doppler

sonography, the angle between the main stem of the MCA and the ultrasound beam is unknown. Higher velocities obtained with MR angiography compared with transcranial Doppler sonography have been reported in the literature (20).

One of the major problems of this study was the exact positioning of the MR imaging flow section perpendicular to the M1 segment of the MCA, which is essential to achieve correct MR flow data (21). We used T1-weighted images in two section orientations and arterial MR angiography for seeing of the exact vessel course of the MCA and all major vessels of the circle of Willis in order to avoid the superimposition of other arteries in MR flow measurements and to place the section correctly. Also, for purpose of evaluating the MR flow data set, the exact placement of the region of interest within the vessel is essential for the generation of appropriate flow velocity profiles. To facilitate positioning of the region of interest, an additional magnification factor was used. The dependency of blood flow velocities to the square of arterial diameter has to be mentioned as a further limitation of the measurement technique. For example, a 10% decrease in diameter led to a 23% increase in velocity.

No significant deviation of the vessel diameters was observed in any of the MR flow images. Determining the exact diameter of an intracranial vessel with MR imaging is difficult, as the physically achievable resolution depends on the matrix size and the FOV (21). We achieved a physical resolution of approximately 0.7 mm in the MR flow study, and $0.8 \times 0.4 \text{ mm}$ in the MR angiographic and MR imaging studies. But this resolution is improved by interpolation algorithms for on-screen display and by the distance calculation program. These steps result in an increased resolution of on-screen measured distances, which are subdivided into 0.1-mm steps. New technical developments, such as an increased matrix of 1024×1024 , in combination with smaller FOVs, will also increase the physically measurable resolution in the near future. At present, our data can be regarded as preliminary results concerning diameter changes of intracranial blood vessels.

In conclusion, a significant decrease in CBF velocity was observed by transcranial Doppler sonography and MR flow imaging during hyperventilation, although there was no change in vessel diameter. Our data support the hypoth-

esis that flow changes are due to altered resistance caused by diameter changes within the small vessels distal to the M1 segment of the MCA, and that the large vessels mainly serve as conductance channels. Relative changes in MCA flow velocity, as measured by transcranial Doppler sonography, would thereby reflect relative changes in CBF, at least during hypocapnia.

References

1. Aaslid R, Markwalder TM, Nornes H. Non-invasive transcranial Doppler ultrasound recording of flow velocity in basal cerebral arteries. *J Neurosurg* 1982;57:769-774
2. Bishop CCR, Powell S, Rutt D, Browne NL. Transcranial Doppler measurement of the middle cerebral artery blood flow velocity: a validation study. *Stroke* 1986;17:913-915
3. Lindegaard KF, Lundar T, Wiberg J, Sjöberg D, Aaslid R, Nornes H. Variations in middle cerebral artery blood flow investigated with noninvasive transcranial blood velocity measurements. *Stroke* 1987;18:1025-1030
4. Newell DW, Aaslid R, Lam A, Mayberg TS, Winn HR. Comparison of flow and velocity during dynamic autoregulation testing in humans. *Stroke* 1994;25:793-797
5. Huber P, Handa J. Effect of contrast material, hypercapnia, hyperventilation, hypertonic glucose and papaverine on the diameter of the cerebral arteries: angiographic determination in man. *Invest Radiol* 1976;2:17-32
6. Kontos HE. Validity of cerebral arterial blood flow calculations from velocity measurements. *Stroke* 1989;20:1-3
7. Giller CA, Bowman G, Dyer H, Mootz L, Krippner W. Cerebral arterial diameter during changes in blood pressure and carbon dioxide during craniotomy. *Neurosurgery* 1993;32:737-742
8. Fürst G, Sitzler M, Hofer M, Steinmetz H, et al. Quantification of carotid blood flow velocity using MR phase mapping. *J Comput Assist Tomogr* 1994;18:688-696
9. Markwalder TM, Grolimund P, Seiler RW, Roth F, Aaslid R. Dependency of blood flow velocity in the middle cerebral artery on end-tidal carbon dioxide partial pressure: a transcranial ultrasound Doppler study. *J Cereb Blood Flow Metab* 1984;4:368-372
10. Aaslid R, Newell DW, Stooss R, Sorteberg W, Lindegaard KF. Assessment of cerebral autoregulation dynamics from simultaneous arterial and venous transcranial Doppler recordings in humans. *Stroke* 1991;22:1148-1154
11. Bouma GJ, Levasseur JE, Muizelaar P, Wiatt RG, Kontos HA. Description of a closed window technique for in vivo study of the feline basilar artery. *Stroke* 1991;22:522-526
12. Arnold BJ, von Reutern GM. Transcranial Doppler sonography: examination technique and normal reference values. *Ultrasound Med Biol* 1996;12:115-123
13. Hennerici M, Rautenberg W, Sitzler G, Schwartz A. Transcranial Doppler ultrasound for the assessment of intracranial arterial flow velocity, 1. *Surg Neurol* 1987;27:439-448
14. Ringelstein EB, Kahlscheuer B, Niggemeyer E, Otis SM. Transcranial Doppler sonography: anatomical landmarks and normal velocity values. *Ultrasound Med Biol* 1990;16:745-761
15. Kirkham FJ, Padayachee TS, Parsons S, Seargeant LS, House FR, Gosling RG. Transcranial measurement of blood velocities in the basal cerebral arteries using pulsed Doppler ultrasound velocity as an index of flow. *Ultrasound Med Biol* 1986;12:15-21
16. Vriens EM, Kraaijer V, Musbach M, Wieneke GH, van Huffelen AC. Transcranial pulsed Doppler measurements of blood flow velocity in the middle artery: reference values at rest and during hyperventilation in healthy volunteers in relation to age and sex. *Ultrasound Med Biol* 1989;15:1-8
17. Lang J. *Skull Base and Related Structures: Atlas of Clinical Anatomy*. Stuttgart, Germany: Schattauer; 1995
18. Bendel P, Buonocore E, Bockisch A, Besozzi MC. Blood flow in the carotid arteries: quantification by using phase-sensitive MR imaging. *AJR Am J Roentgenol* 1989;152:1307-1310
19. Mattle H, Edelman RR, Reis MA, Atkinson DJ. Flow quantification in the superior sagittal sinus using magnetic resonance. *Neurology* 1990;40:813-815
20. Mattle H, Edelman RR, Wentz KU, Reis MA, Atkinson DJ, Ellert T. Middle cerebral artery: determination of flow velocities with MR angiography. *Radiology* 1991;181:527-530
21. Kane AG, William PD, Barkovich AJ, Norman D, Dowd CF, Kane TT. Reduced caliber of the internal carotid artery: a normal finding with ipsilateral absence or hypoplasia of the A1 segment. *AJNR Am J Neuroradiol* 1996;17:1295-1301