



Get Clarity On Generics

Cost-Effective CT & MRI Contrast Agents



FRESENIUS
KABI

WATCH VIDEO

AJNR

**Wegener granulomatosis of the eustachian tube
and skull base mimicking a malignant tumor.**

R C Helmberger and A A Mancuso

AJNR Am J Neuroradiol 1996, 17 (9) 1785-1790

<http://www.ajnr.org/content/17/9/1785>

This information is current as
of August 9, 2025.

Wegener Granulomatosis of the Eustachian Tube and Skull Base Mimicking a Malignant Tumor

Roxana C. Helmberger and Anthony A. Mancuso

Summary: Wegener granulomatosis is a well-studied yet sometimes difficult-to-diagnose systemic vasculitis. Early treatment with immunosuppressants is the therapy of choice and usually controls the disease. Two cases of Wegener granulomatosis are presented, both with symptoms and imaging findings suggestive of a malignant tumor of the nasopharynx or skull base. The focus of upper respiratory involvement in each case was the eustachian tube.

Index terms: Granuloma; Nasopharynx, neoplasms; Skull, base

Although uncommon, Wegener granulomatosis is an extensively reviewed disease of unknown origin. It belongs to one of the seven forms of vasculitis classified by the American College of Rheumatology (1). The disease is, in its classic form, characterized by a necrotizing granulomatous vasculitis of the upper and lower respiratory tract, focal segmental glomerulonephritis, and variable expressions of small-vessel disease. Wegener granulomatosis can be discriminated from other forms of vasculitis by four criteria; when at least two of these criteria are present, the disorder can be diagnosed with a sensitivity of 88% and a specificity of 92%. The four criteria are oral or nasal inflammation with ulcers; purulent or bloody nasal discharge; the presence of nodules, fixed infiltrates, or cavities on a chest radiograph; nephritic urinary sediment; and granulomatous inflammation on a biopsy; hemoptysis is an acceptable alternative if a biopsy sample is not available (2). Recently, the detection of anticytoplasmatic antibodies (ACPA, a synonym is *c*-ANCA, which stands for *cytoplasmic pattern antineutrophil cytoplasm antibody*) has assumed a central role in confirming the diagnosis of Wegener granulomatosis. Immunosuppressive therapy with corticosteroids and cyclophosphamide can significantly im-

prove the prognosis and produce full remission.

The two cases presented show how the localized form of Wegener granulomatosis can mimic a malignant tumor of the nasopharynx or skull base when the pathologic findings are not specific.

Case Reports

Case 1

A 71-year-old woman had bilateral serous otitis media. A magnetic resonance (MR) image of the brain had been obtained at an outside institution because of an associated peripheral facial weakness; it reportedly showed no abnormalities, but was not focused on the more peripheral course of the facial nerve through the internal auditory canal, temporal bone, and parotid gland. One week later, on admission to our institution, physical examination revealed a small amount of ear drainage bilaterally and no hearing in the left ear; other findings were normal. There was no lymphadenopathy, and the chest was clear. Neurologic examination showed a left-sided, peripheral palsy of the facial nerve in addition to the hearing loss; cranial nerves II through XII were otherwise intact. Findings on a chest radiograph were normal.

Contrast-enhanced computed tomography (CT) of the temporal bone on the day of admission showed an infiltrating, left-sided nasopharyngeal mass (Fig 1A) and abnormal enhancement of the facial nerve at the geniculate ganglion. A nasopharyngeal carcinoma with retrograde spread to the bony eustachian tube and adjacent skull base was the primary working diagnosis. The endoscopic biopsy of the nasopharyngeal mass showed chronic inflammation with fibrosis and no evidence of malignancy, vasculitis, or granulomas. Subsequent CT-guided biopsy yielded the same pathologic results.

MR images obtained 1 week later showed abnormal enhancing tissue spreading from the nasopharynx along the eustachian tube to the hypotympanum and mesotympanum (Fig 1B and C). Abnormal nodular enhancement within the cochlea and at the anterior genu of the facial nerve was also present (Fig 1C and D).

Received July 6, 1995; accepted after revision January 2, 1996.

From the Department of Radiology, Box 100374, University of Florida College of Medicine, Gainesville, FL 32610. Address reprint requests to Anthony A. Mancuso, MD.

AJNR 17:1785-1790, Oct 1996 0195-6108/96/1709-1785 © American Society of Neuroradiology

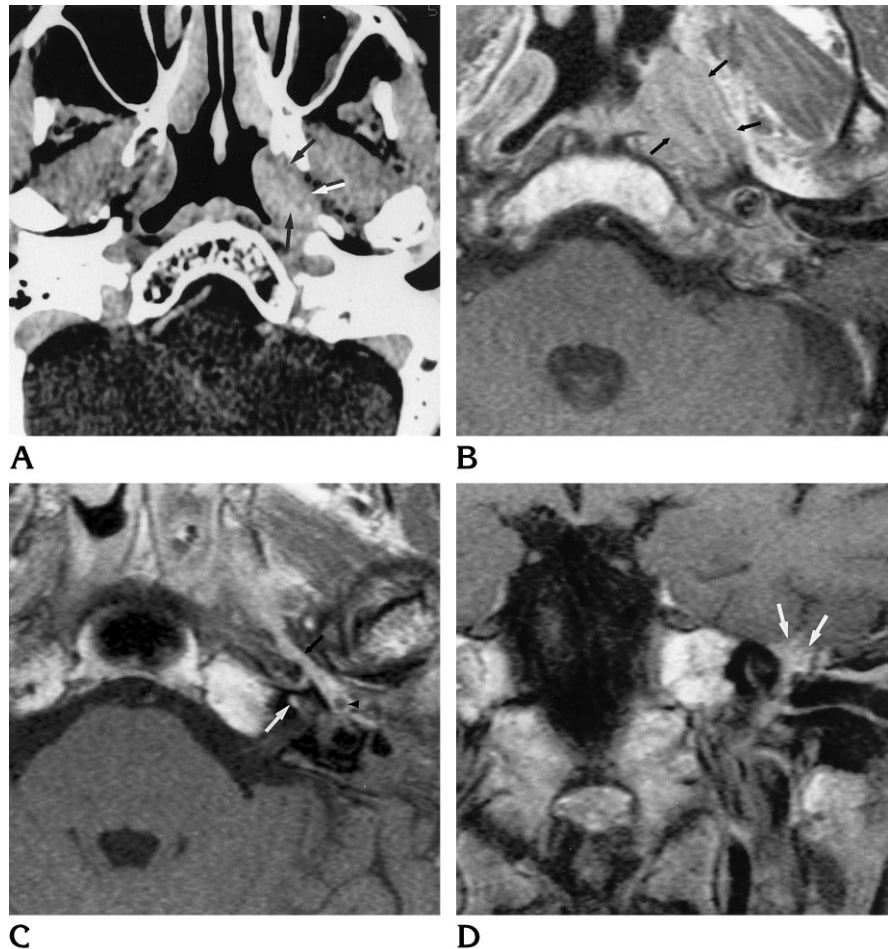
Fig 1. Case 1: 71-year-old woman with bilateral serous otitis media.

A, Axial contrast-enhanced CT scan shows a slightly enhancing mass surrounding the eustachian tube (arrows).

B, Axial T1-weighted contrast-enhanced MR image at approximately the same level as A perhaps more graphically illustrates the infiltrating character of the mass (arrows).

C, Axial contrast-enhanced T1-weighted MR image about 6 mm cephalad to B shows enhancing tissue at the junction of the cartilaginous and bony eustachian tube (black arrow) and in the middle ear (arrowhead). A nodule of enhancement is seen in the cochlea as well (white arrow).

D, Coronal contrast-enhanced T1-weighted MR image shows abnormal enhancing tissue at the anterior genu of the facial nerve (arrows).



A follow-up CT study 1 month later showed no change in the extent of disease. At this time an elevated titer for c-ANCA became available and Wegener granulomatosis was diagnosed. Cyclophosphamide therapy was begun. The patient was gradually tapered off immunosuppressants and a follow-up CT study 2½ years later showed complete resolution of all previously described abnormalities. The facial nerve palsy resolved, but the patient never regained hearing in the left ear. She remains disease free 4 years later.

Case 2

A 24-year old woman had a 1-month history of headache associated with tearing, photosensitivity, and discharge from her nose. The nasal discharge was initially purulent, it then became clear but was still blood-tinged. Loss of appetite, tooth pain, fatigue, coldness, and sweating were also reported. On physical examination, a pale and very swollen nasal mucosa with some purulent discharge on the left side was noted. The diagnosis of sinusitis was made and the patient was discharged on oral antibiotics. On follow-up visits her symptoms remained unchanged.

Her medical history included hospitalization 9 years earlier for progressive renal failure and pneumonia. Renal

and open lung biopsies were done during that hospital stay and vasculitis was diagnosed; however, necrotizing granulomas were not found. Wegener granulomatosis was suspected, but since it was not proved by biopsy, the treatment with cyclophosphamide and steroids was interrupted after 2 months. The discharge diagnosis was nonspecific vasculitis and she remained in remission for 9 years.

An MR examination of the head was done 1 month after the present admission because of worsening headaches and sinus tenderness; this initial MR study was interpreted as normal. In retrospect, the study showed minimal mucosal disease in the mastoid portion of the temporal bone and a subtle infiltrating mass along the course of the eustachian tube (Fig 2A and B).

Six weeks later, she was hospitalized with symptoms of right ear discomfort and headache, neither of which was responsive to narcotics. She reported a low-grade fever and a weight loss of 40 kg. The erythrocyte sedimentation rate (ESR) and platelet count were elevated and there was a leukocytosis. Other laboratory studies were normal and without evidence of renal dysfunction. The c-ANCA study performed by flow cytometry was positive. A diagnosis of Wegener granulomatosis was made and therapy with oral cyclophosphamide therapy started. A biopsy was not attempted because the lesion was considered surgically in-

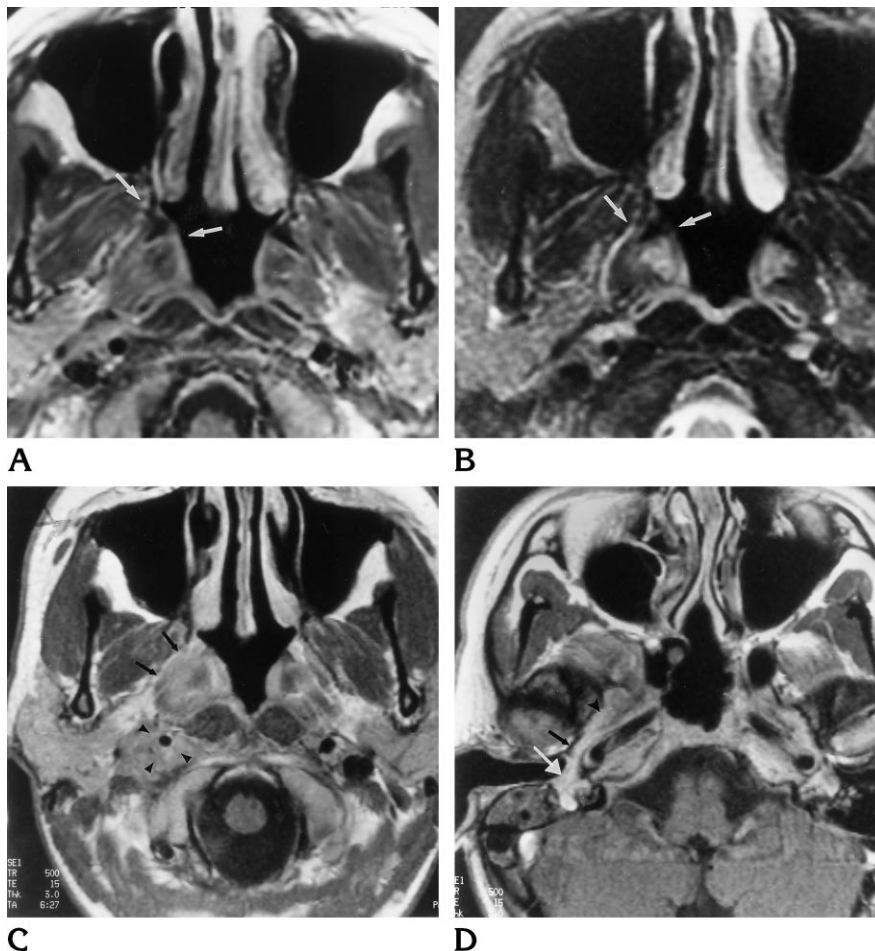


Fig 2. Case 2: 24-year-old woman with 1-month history of headache, tearing, photosensitivity, and nasal discharge.

Axial contrast-enhanced T1-weighted (A) and T2-weighted (B) fast spin-echo MR images obtained at initial presentation show minimal asymmetry of the nasopharynx near the opening of the eustachian tube at the torus tubarius (arrow).

C and D, Axial contrast-enhanced T1-weighted MR images obtained 2 months later, after the patient's symptoms had progressed. In C, abnormal tissue infiltrates the right lateral nasopharyngeal wall at the torus tubarius (arrows) and surrounds the carotid artery in the poststyloid parapharyngeal space (arrowheads). In D, approximately 9 mm cephalad to C, continued spread of abnormal tissue is seen along the cartilaginous (arrowhead) and bony (black arrow) portions of the eustachian tube to the middle ear (white arrow).

accessible and results of CT-guided fine-needle aspiration were not likely to be definitive. Moreover, the clinical service was satisfied with the combination of the patient's history and the c-ANCA-positive result for making the presumptive diagnosis of Wegener granulomatosis.

An MR study done at the time of the present hospitalization revealed an infiltrating mass surrounding the eustachian tube and spreading to the carotid canal. The mass followed the carotid artery inferiorly and spread diffusely within the upper poststyloid parapharyngeal space (Fig 2C and D). A whole-body thallium scan with single-photon emission CT of the skull base confirmed the MR findings, showing extensive radiotracer activity corresponding to the anatomic extent of the mass seen on the MR images. Findings on a chest radiograph were normal.

A follow-up MR study 3 months later showed a 50% to 75% response of the mass to therapy with steroids and pulsed cyclophosphamide.

Discussion

Wegener granulomatosis is a necrotizing granulomatous disease of the upper and lower

respiratory tract that also causes focal, segmental glomerulonephritis and systemic vasculitis (2–5). There is a slight male to female predominance and it rarely occurs under the age of 16 years (6). There is a peak frequency in the fourth to fifth decades of life, and it is much less common in black subjects.

Wegener granulomatosis is an uncommon but well-studied systemic vasculitis; its various manifestations have been extensively reviewed in the literature. Recently, a new classification was proposed adding a third form to the two forms described earlier: (a) the classical generalized systemic or diffuse form that always involves the kidney and causes necrotizing glomerulonephritis, (b) the localized or limited form without involvement of the upper respiratory tract or kidneys, and (c) the third, newly proposed form, is the purely granulomatous (without evidence of vasculitis) Wegener granulomatosis involving primarily the ears, nose,

throat, eyes, or lungs, each of which may be the first and only manifestation of the disease (7).

When described in the early 1930s by Klinger (8) and later by Wegener (9), the mean survival time after the onset of clinical manifestations was 5 months if untreated; 82% of patients died at 1 year, and more than 90% were dead at 2 years. The cause of death usually was renal failure or secondary infection (3, 4, 10). Patients with Wegener granulomatosis commonly experience multiple symptoms, including malaise, fever, cough, rhinorrhea, weight loss, otitis media, arthralgia, and hemoptysis (4). The upper or lower respiratory tract is always involved, and the most commonly affected organs are the lung, paranasal sinuses, nasal cavity, and nasopharynx; the kidneys are affected in 74% to 85% of cases (4, 10). Since it is a systemic disease, it may involve other sites, including the joints, eyes, skin, muscles, heart, or nervous system (4, 5, 10).

Commonly used laboratory tests are not specific for the disease; however, an elevated ESR is seen in 94% (5) to 100% (3, 4) of cases. Anemia may be present in 50% to 70% of cases (4, 5, 10). Circulating immune complexes are present in 90% of cases (5). The platelet count is high in 34% to 64% of cases (4, 5, 10).

When seen as a mass on CT or MR studies, Wegener granulomatosis will enhance moderately. Masses seen on MR images will be isointense to slightly hypointense relative to muscle on T1-weighted images and have anywhere from slightly higher to slightly lower signal intensity relative to muscle on T2-weighted images.

When CT or MR studies show an infiltrating mass such as that described above and biopsy results fail to confirm a malignant tumor as the source (eg, carcinoma, lymphoma, plasmocytoma), other diseases such as Wegener granulomatosis, pseudotumor, reticulosis, and sarcoidosis become more probable diagnoses. The radiologist may be the first to recognize the infiltrating nature of the disease process, and when appropriate tissue sampling has not resulted in a definitive diagnosis, may suggest the alternatives just listed.

The four criteria for diagnosing Wegener granulomatosis defined by the American College of Rheumatology are listed in the introduction. The standard of reference for diagnosis of Wegener granulomatosis remains the histopathologic findings of necrotizing vasculitis (typically affecting the small arteries and veins

or the perivascular and extravascular area) with granulomas. These necrotizing granulomas, although hallmarks of the disease, are rare in the head and neck (5), whereas isolated vasculitis and granulomatous inflammation are seen frequently. This factor further emphasizes the need for the radiologist to suggest appropriate alternative diagnoses when the imaging morphology and clinical circumstances are appropriate.

Von der Woude et al (11) described the presence of autoantibodies directed against a cytoplasmic antigen of human neutrophils and monocytes, c-ANCA. The target antigen of these antibodies is proteinase 3 (11–14). The levels of c-ANCA have a high specificity and sensitivity for Wegener granulomatosis and they parallel the disease activity, being present in 95% of the serum of patients with the active generalized form (14). A single negative c-ANCA finding does not exclude Wegener granulomatosis; several serial determinations are required for exclusion of the disease. Moreover, a positive c-ANCA finding does not entirely replace a biopsy, which is still required for the clinical diagnosis (15). The c-ANCA finding may be positive in a variety of immune-mediated diseases, including systemic lupus erythematosus and polyarteritis nodosa; the test may also be positive in ulcerative colitis and Crohn disease. When repeated biopsy results remain negative and there is strong clinical suspicion of Wegener granulomatosis, the presence of these antibodies is a reasonable basis for a presumptive diagnosis of Wegener granulomatosis and for a therapeutic trial of steroids and cyclophosphamide (14).

In 1954, Fahey reported good therapeutic results with cytotoxic chemotherapy added to the existing treatment with corticosteroids (16). Currently, cyclophosphamide in combination with corticosteroids is the treatment of choice. It is of crucial importance to diagnose Wegener granulomatosis, since treatment with cyclophosphamide seems to be the only reliable way to cure the disease and prevent irreversible renal damage (4, 10, 12).

Otologic manifestations may be the first and only sign of Wegener granulomatosis, whereas otologic involvement during the course of classical, generalized Wegener granulomatosis occurs in 20% to 40% of patients. (17, 18). The serous or suppurative otitis media resulting from the eustachian tube obstruction usually causes a unilateral conductive hearing loss (Fig

1A). In case 1, the MR, CT, and clinical findings mimicked an adenoidcystic carcinoma, as the mass was submucosal and there was perineural disease involving the facial nerve. Multiple biopsy specimens could not confirm either the presence of a tumor or the necrotizing vasculitis with granulomas. The definitive diagnosis of Wegener granulomatosis relied on the demonstration of an elevated titer of c-ANCA. After treatment with cyclophosphamide and corticosteroids was started, the facial nerve palsy resolved within weeks. Facial nerve involvement is unusual, having been reported in only six of 85 patients with generalized Wegener granulomatosis in one series (4) and four of 13 patients with otologic involvement in another series (19). This case would fit into the newly proposed third form of the disease, called purely granulomatous Wegener granulomatosis, or type III.

In case 2, the clinical manifestations of Wegener granulomatosis preceded obvious radiologic findings by 2 months. The patient suffered from severe ear pain probably caused by otherwise subclinical disease adjacent to the skull base. Disease beginning within the eustachian tube and spreading to the poststyloid parapharyngeal space could account for both the pain and serous otitis media. As in case 1, the respiratory tract focus of disease was "hidden" in the eustachian tube, causing some initial confusion in attributing the patient's symptoms to Wegener granulomatosis. The episode of acute renal failure 9 years earlier, at which time vasculitis was diagnosed, could now be interpreted as Wegener granulomatosis. The long period of remission and complete restitution of renal function without treatment is extremely rare. Once the kidneys are involved, the disease, even if treated, may progress to chronic renal failure (12, 20, 21).

MR imaging, CT, and nuclear medicine may be useful in follow-up of these patients. In case 1, the follow-up CT scan showed resolution of all abnormalities. In case 2, follow-up MR imaging is being used to monitor intermittent therapy. Disease processes other than Wegener granulomatosis, such as lymphoma, may show a response to therapy so that imaging or radionuclide studies are limited with regard to specificity. This limitation of specificity does not, however, restrict their value in following the response of otherwise inaccessible disease, especially in patients who are symptomatic.

It is possible that diseases such as pseudotumor, lymphoma, and plasmacytoma could show a response to the immunosuppressive therapy used to treat Wegener granulomatosis. Therefore, if only a presumptive (ie, not biopsy-confirmed) diagnosis has been made on the basis of c-ANCA and other criteria, complete and continued response to the therapy should be documented. If less than complete response is noted on follow-up imaging and laboratory studies, every attempt should be made to obtain histologic confirmation or at least to follow-up the patient at clinically appropriate intervals so as to detect recurrence of the lesion as early as possible. It is our policy to suggest no more than a 3- to 4-month interval between follow-up imaging studies if the diagnosis has not been established with certainty.

In summary, Wegener granulomatosis may present as an isolated inflammatory mass that mimics a malignant tumor of the nasopharynx or skull base. If biopsy results fail to identify a malignant tumor, a noninfectious inflammatory process such as Wegener granulomatosis must be considered, and appropriate laboratory studies, including c-ANCA, should be ordered as an aid to diagnosis. While not absolutely specific for the diagnosis of Wegener granulomatosis, a positive c-ANCA finding in an appropriate clinico-radiologic setting can lead to a therapeutic trial of steroids and cyclophosphamide. Such prompt treatment can help circumvent the potentially life-threatening renal complications of this disease. If there is an unsatisfactory response to such a therapeutic trial, then other diagnostic possibilities, including malignant tumors, must be considered and pursued aggressively.

References

1. Bloch DA, Michel BA, Hunder GG, et al. The American College of Rheumatology 1990 criteria for the classification of vasculitis. *Arthritis Rheum* 1990;33:1068-1073
2. Leavitt RY, Fauci AS, Bloch DA, et al. The American College of Rheumatology 1990 criteria for the classification of Wegener's granulomatosis. *Arthritis Rheum* 1990;33:1101-1107
3. Kornblut AD, Wolff SM, DeFries HO, Fauci AS. Wegener's granulomatosis. *Laryngoscope* 1980;90:1453-1465
4. Fauci AS, Haynes BF, Katz P, Wolff SM. Wegener's granulomatosis: prospective clinical and therapeutic experience with 85 patients for 21 years. *Ann Intern Med* 1983;98:76-85
5. Burlacoff SG, Wong FSH. Wegener's granulomatosis, the great masquerade: a clinical presentation and literature review. *J Otolaryngol* 1993;22:94-105

6. Singer J, Suchet I, Horwitz T. Pediatric Wegener's granulomatosis: two case histories and review of the literature. *Clin Radiol* 1990; 42:50-51
7. Boudes P. Purely granulomatous Wegener's granulomatosis: a new concept for an old disease. *Semin Arthritis Rheum* 1990;19: 365-370
8. Klinger H. Grenzformen der Periarthritis Nodosa. *Z Pathol* 1932; 42:455-480
9. Wegener F. Über generalisierte septische Gefässerkrankungen. *Verh Dtsch Pathol Ges* 1936;29:202-209
10. Cordier JF, Valeyre D, Guillevin MD, Loire R, Brechot JM. Pulmonary Wegener's granulomatosis: a clinical and imaging study of 77 cases. *Chest* 1990;97:906-912
11. Von der Woude FJ, Rasmussen N, Lobatto S et al. Autoantibodies against neutrophils and monocytes: tool for diagnosis and marker of disease activity in Wegener's granulomatosis. *Lancet* 1985;1: 425-429
12. Woodworth TG, Abuelo GJ, Austin HA III, Esparaza A. Severe glomerulonephritis with late emergence of classic Wegener's granulomatosis. *Medicine* 1987;66:181-191
13. Csernok E, Ludemann J, Gross WL, Bainton DF. Ultrastructural localization of proteinase 3 the target antigen of anti-cytoplasmic antibodies circulating in Wegener's granulomatosis. *Am J Pathol* 1990;137:1113-1119
14. Turner A. Anti-neutrophil cytoplasmic antibodies (ANCA): a seromarker for Wegener's granulomatosis. *J Otolaryngol* 1991; 20:274-276
15. Nolle B, Specks U, Ludemann J, Rohrbach MS, DeRemee RA, Gross WL. Anticytoplasmic autoantibodies: their immunodiagnostic value in Wegener's granulomatosis. *Ann Intern Med* 1989; 111:28-40
16. Fahey JL, Leonard E, Churg J, et al. Wegener's granulomatosis. *Am J Med* 1954;17:168-179
17. Bradley PJ. Wegener's granulomatosis of the ear. *J Laryngol Otol* 1983;97:623-626
18. Calonijs IH, Christensen CK. Hearing impairment and facial palsy as initial signs of Wegener's granulomatosis. *J Laryngol Otol* 1980;94:649-657
19. Illum P, Thorling K. Otological manifestations of Wegener's granulomatosis. *Laryngoscope* 1982;92:801-804
20. Anderson CL, Stavrides A. Rapidly progressive renal failure as the primary manifestation of Wegener's granulomatosis. *Am J Med Sci* 1978;275:109-112
21. Kuross S, Davin T, Kjellstrand CM. Wegener's granulomatosis with severe renal failure: clinical course and results of dialysis and transplantation. *Clin Nephrol* 1981;16:172-180