



Get Clarity On Generics

Cost-Effective CT & MRI Contrast Agents



FRESENIUS
KABI

WATCH VIDEO

AJNR

Arterial saccular aneurysm model in the rabbit.

C M Cawley, R C Dawson, G Shengelaia, G Bonner, D L Barrow
and A R Colohan

AJNR Am J Neuroradiol 1996, 17 (9) 1761-1766

<http://www.ajnr.org/content/17/9/1761>

This information is current as
of August 11, 2025.

Arterial Saccular Aneurysm Model in the Rabbit

C. Michael Cawley, Robert C. Dawson, George Shengelaia, Gary Bonner, Daniel L. Barrow, and Austin R. T. Colohan

Summary: Saccular aneurysms arising from the common carotid artery in the neck at the origin of the internal carotid artery were created in male rabbits using the stump of a ligated external carotid artery. These stumps were intraluminally perfused with varying concentrations of porcine pancreatic elastase for 45 minutes via a microcatheter introduced into the femoral artery. The aneurysms were allowed to mature for 2 to 12 weeks. Gross examination and histologic studies confirmed the presence of an aneurysm in all 15 experiments. Ninety-two percent (12 of 13) of the aneurysms studied by postoperative angiography were shown to be angiographically patent; 40% of all aneurysms were noted to be patent at harvest; and the remainder showed evidence of intraluminal thrombus. On histologic examination, all aneurysms showed complete loss of elastic lamina without evidence of fibrosis or scarring.

Index terms: Aneurysm, arteriovenous; Animal studies

Intracranial aneurysms pose a relatively great threat to a small but significant portion of the population. As the most common source of nontraumatic subarachnoid hemorrhage (more than 80% of all cases [1]), these lesions have been estimated to cause death or disability in 18 000 patients per year in North America (2). Several autopsy and angiographic series have estimated the prevalence of intracranial aneurysms in the general population to be between 1% and 8% (3–11).

The time-honored and durable treatment of intracranial aneurysms is open craniotomy with clip ligation of the lesion. With advances in microsurgical techniques, this procedure—in most cases—is straightforward and carries acceptable risks of perioperative morbidity and mortality. A significant minority of patients, however, have complicated aneurysms in areas difficult to access surgically. The field of interventional neuroradiology offers less invasive

treatment options that exclude an aneurysm from the cerebral circulation. Even large non-ruptured aneurysms with mass effect may be partially decompressed by endovascular occlusion of the aneurysmal lumen or sacrifice of the parent artery, resulting in the stabilization or amelioration of neurologic symptoms.

Despite the serious nature of intracranial aneurysms and the advent of these new technologies, few experimental animal models have been devised to compare different modes of treatment and provide an experimental paradigm for further research. Controversy has arisen over the long-term durability of endovascular occlusion of aneurysms. Many studies have shown good initial obliteration rates, but, over time, many endovascularly treated aneurysms will recannulate (12–14). To evaluate further which techniques and occlusive substances might offer lasting luminal obliteration, a reliable model of an animal saccular aneurysm is required.

Anidjar et al (15) developed a novel model of a fusiform abdominal aortic aneurysm in the rat by using intraarterial porcine pancreatic elastase incubation. Adequate concentrations of elastase reliably result in degradation of the internal elastic lamina and macroscopic aneurysmal formation. Applying principles of the work by Anidjar et al, we have developed a wholly arterial model of a saccular aneurysm in rabbits. We believe these experimental aneurysms will more closely approximate the hemodynamics, natural physiology, and response to occlusive agents of human saccular aneurysms than do current models, which rely on vein patch grafts.

Received January 2, 1996; accepted February 7.

Supported in part by a grant from the MBNA America Corporation.

From the Departments of Neurosurgery (C.M.C., G.B., D.L.B., A.R.T.C.) and Radiology (R.C.D., G.S.), Emory University School of Medicine, Atlanta, Ga.

Address reprint requests to C. Michael Cawley, MD, Division of Neurosurgery, the Emory Clinic, Building B, Suite 2200, 1365 Clifton Rd NE, Atlanta, GA 30322.

AJNR 17:1761–1766, Oct 1996 0195-6108/96/1709–1761 © American Society of Neuroradiology

Experimental parameters and results of each enrolled animal

Animal	Elastase Dose, U	Time to Harvest, wk	Angiographically Patent Aneurysm?	Aneurysm at Harvest?	Aneurysm Patent at Harvest?
1	L, 10/R, 10	L, 2/R, 3	L, Yes/R, Yes	L, Yes/R, Yes	L, No/R, No
2	L, 10/R, 10	L, 2/R, 3	L, Yes/R, Yes	L, Yes/R, Yes	L, No/R, No
3	L, 10/R, 10	L, 2/R, 3	L, Yes/R, Yes	L, Yes/R, Yes	L, Yes/R, No
4	R, 10	R, 2	R, Yes	R, Yes	R, Yes
5	L, 60/R, 60	L, 3/R, 6	L, Yes/R, Yes	L, Yes/R, Yes	L, Yes/R, Yes
6	L, 60/R, 20	L, 6/R, 9	L, Yes/R, No	L, Yes/R, Yes	L, Yes/R, No
7	L, 60/R, 20	L, 9/R, 12	L, Yes/R, Yes	L, Yes/R, Yes	L, Yes/R, No
8	R, 60	R, 12	...	R, Yes	R, No
9	R, 60	R, 12	...	R, Yes	R, No

Materials and Methods

Experimental Procedure

Under an approved protocol, rabbits were procured through our Institutional Animal Care and Use Committee. They were maintained in accordance with the National Institutes of Health *Guide to the Care and Use of Laboratory Animals* (16).

A 0.75-cm segment of the proximal external carotid artery was isolated and perfused in nine male rabbits. In six rabbits the procedure was carried out on the contralateral side as well, although not during the same operation. A total of 15 aneurysms were thus created in nine rabbits. The animals were anesthetized for induction and intubation with 1.5 mL of ketamine hydrochloride (50 mg/mL) and 1.5 mL of xylazine hydrochloride (20 mg/mL). Endotracheal intubation was followed by maintenance anesthesia with 0.5% halothane. Under binocular microscopic magnification (Zeiss, Oberkochen, Germany), a midline incision was made extending from the angle of the mandible inferiorly approximately 2 cm. The carotid bifurcation was exposed lateral to the trachea and esophagus. Both the internal and external carotid arteries as well as the superior thyroidal artery were identified. We placed, but did not fasten, 2-0 silk ties (Ethicon, Inc, Somerville, NJ) at the origin of the external carotid artery and 0.75 cm distal to the origin.

A separate 2-cm incision was made over the right side of the groin, and the femoral artery was dissected and isolated with a 2-0 silk tie. An arteriotomy was performed, and a 2F distal outer diameter Tracker-10, 80/15 catheter (Target Therapeutics, San Jose, Calif) was inserted under binocular magnification. The catheter and a Dasher-14 Stereable Guidewire (Target Therapeutics, San Jose, Calif) were then advanced under fluoroscopy to the common carotid artery. Under direct visualization, the catheter tip was advanced into the proximal 0.5 cm of the external carotid artery. The guidewire was removed and the distal silk tie was tied to create the external carotid arterial stump; the proximal tie was cinched down on the catheter at the external carotid origin. After evacuating the blood present in the sac thus created, a vent tube (outer diameter, 0.012 in; Interventional Therapeutics Corp, Fremont, Calif) loaded with 0.13 mL of elastase solution was in-

serted into the catheter. The elastase solution was then infused and allowed to incubate for 45 minutes.

After the incubation period, the proximal external carotid tie was removed and the catheter withdrawn. The femoral artery was tied off proximal to the arteriotomy and both incisions were closed with 3-0 ethilon sutures (Ethicon). The animals were awoken from anesthesia, extubated, and returned to their cages. At postoperative intervals varying from 2 to 12 weeks, C-arm fluoroscopic angiography (NV Philips, Best, the Netherlands) was performed via a left femoral artery cut-down, the common carotid aneurysm segments were harvested, and the animals were killed.

Morphology

Once the aneurysm-bearing common carotid segments were harvested they were fixed in formalin and embedded in paraffin for histologic examination. Longitudinal 5- μ m sections were stained with hematoxylin-eosin and with orcein for elastic tissue.

Experimental Protocol

Fifteen proximal external carotid artery sacs in nine rabbits were perfused with varying concentrations of porcine pancreatic elastase type 1 (Sigma Chemical Co, St Louis, Mo, and ICN Biomedicals Inc, Aurora, Ohio). Rabbits 1 to 4 were perfused with 10 U of elastase (0.13 mL; 80 U/mL) in normal saline solution. Rabbits 5 to 9 were perfused with elastase in normal saline solution varying in concentration from 20 to 60 U/0.13 mL (Table).

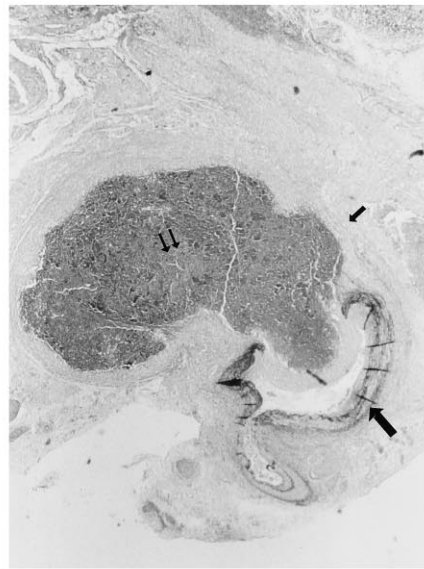
Results

Perfusion with Pancreatic Elastase Solution

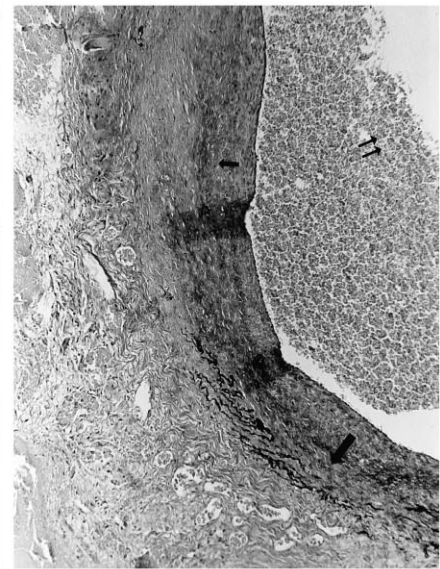
A total of 15 common carotid artery aneurysms were created in nine male rabbits (unilaterally in three animals, bilaterally in six animals). Macroscopic and microscopic aneurysms developed in all external carotid artery sacs perfused with elastase (10 to 60 U per animal) (Table). Histologic study of longitudinal

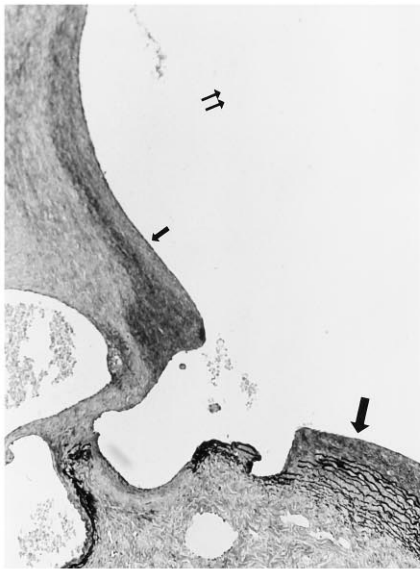

Fig 1. Histologic longitudinal cross section of aneurysm created in animal 3. *Large arrow* indicates parent artery with intact elastic lamina; *small arrow*, aneurysmal wall with absent elastic lamina; and *double arrows*, patent aneurysmal lumen (hematoxylin-eosin and orcein stain).



A



B

Fig 2. Histologic longitudinal cross section of aneurysm created in animals 1 (A) and 6 (B). *Large arrows* indicate parent artery with intact elastic lamina; *small arrow*, aneurysmal wall with absent elastic lamina; and *double arrows*, aneurysmal lumens (hematoxylin-eosin and orcein stain).

sections revealed complete loss of the elastic lamina in the perfused segment of the external carotid stump only (Figs 1 and 2). No elastic lamina breakdown was noted in nonelastase-perfused tissue. Varying the dose of elastase (seven external carotid sacs in four animals received 10 U; two sacs in two animals received 20 U; six sacs in five animals received 60 U) had no effect on the extent of elastic lamina loss seen on histologic orcein stains.

All histologic specimens revealed mild inflammatory infiltrates of both polymorphonuclear lymphocytes and macrophages. All specimens also revealed mild intimal fibrosis and smooth muscle hyperplasia in the aneurysmal wall; the degree of fibrosis or hyperplasia did not vary with incubation time prior to harvest. Otherwise, the aneurysmal wall retained the normal arterial microscopic architecture (Fig 1 and 2).

Aneurysmal Patency

Angiography.—Angiography was performed in 13 of 15 elastase-perfused sacs 2 weeks after surgery. In 92% (12 of 13) of the cases, the angiographic study with C-arm fluoroscopy (Fig 3) revealed a patent common carotid an-

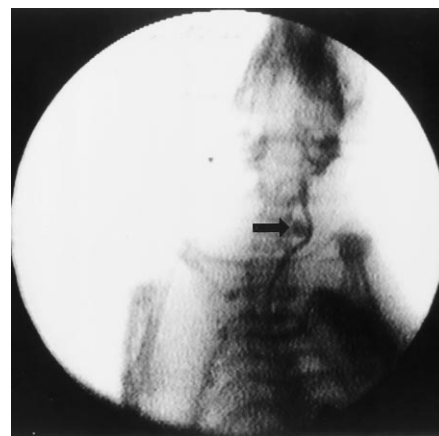

Fig 3. Fluoroscopic C-arm left common carotid arteriogram of animal 2. *Arrow* indicates experimentally created aneurysm.

eurysm at the origin of the internal carotid artery. The one aneurysm not seen at angiography was noted at harvest to be thrombosed.

Gross Histopathology.—All perfused external carotid sacs were harvested at an average of 6 weeks after elastase perfusion (range, 2 to 12 weeks; median, 3 weeks) (Table). As noted, on harvest, all perfused sacs revealed both macroscopic and microscopic aneurysms of varying size. Microscopic patency of the aneurysmal lumen was noted in 40% (6 of 15) of the per-

fused sacs (Table). The remaining nine aneurysms were found to have varying degrees of new and old thrombus, but no fibrotic scarring. Two (40%) of five sacs perfused with 10 U elastase remained patent; none (0%) of two sacs perfused with 20 U elastase remained patent; and four (67%) of six sacs perfused with 60 U elastase remained patent. Of those sacs allowed to mature less than 3 weeks after perfusion, three (38%) of eight showed aneurysmal patency; of those allowed to mature more than 3 weeks, three (43%) of seven remained patent. These differences did not reach statistical significance.

Discussion

The creation of a wholly arterial saccular aneurysm in an animal model would contribute to advances in the exploration of novel endovascular aneurysmal obliteration techniques. German and Black (17) developed a side-wall model of an aneurysm in dogs by using venous patch grafts. Similar models have also been developed in swine (17, 18). These models are currently the most widely used for demonstrating the efficacy of various endovascularly introduced occlusive substances. One serious drawback of such models is that, while the hemodynamics of a venous pouch may be similar to that of a naturally occurring arterial aneurysm, the wall of the pouch is not arterial in nature. A second drawback is that multiple suture lines are necessary to construct the pouch. This manipulation of the arterial and venous pouch endothelium releases, among other proteins, platelet-derived growth factor, which often leads, over time, to scarring of the experimentally produced aneurysm with or without the introduction of obliterating materials, thus confounding any long-term results. We believe our model may eliminate each of these drawbacks and thus provide a substrate for reliable and reproducible study of various obliterative materials.

The specific mechanism underlying the formation of saccular aneurysms is still not clearly understood. Forbus (19) first described congenital discontinuities of the smooth muscle layer of the tunica media of arterial vessels. These medial gaps were thought to represent a focal area of decreased resistance that might, over time, degenerate and dilate into aneurysmal sacs (20). In fact, the medial gaps are similar to the

transition zone seen in histologic sections of naturally occurring aneurysms, where one notices the abrupt loss of elastic lamina, diminished smooth muscle thickness in the tunica media, and intimal fibrosis in the aneurysmal wall proper (21).

Medial gaps, however, are seen not only in cerebral arteries but also in systemic arteries, where aneurysmal formation is rare (22–24). Thus, there is doubt as to whether saccular aneurysms are purely congenital. A second theory of aneurysmal formation proposes that these sacs are the result of degenerative changes in the arterial wall (23, 25–28). Many studies that support this view have shown intimal proliferation, elastic lamina degradation, atherosclerotic changes, extracellular matrix protein alterations, and loss of the normal architectural distribution of type I collagen and fibronectin in aneurysmal walls (23, 29, 30). These changes are thought to be associated with the degenerative changes seen in atherosclerosis and the hemodynamic stresses present at arterial bifurcations (20, 24, 31).

Whether aneurysmal formation is the result of a congenital weakness, a degenerative process, or both, it is clear that to study these lesions it is ideal to use a model histologically consistent with the natural lesion. Anidjar et al (15) studied the pathohistology of the abdominal aortic aneurysm and found it to demonstrate consistently elastic lamina degeneration. Their model, which used porcine pancreatic elastase to duplicate this loss, indicates that elastolytic activity plays a major role in aortic aneurysmal formation. In fact, previous models of aortic aneurysms, employing a variety of methods, all result in some deficiency in the elastin network, perhaps as a final common pathway (32–36). Halpern et al (37) showed that degradation of the elastic lamina with elastase leads to a cascade of changes in extracellular matrix proteins and progressive inflammatory infiltration. All these changes are seen in naturally occurring cerebral and aortic aneurysms. It is this similarity that allows the extension of the work by Anidjar et al to the creation of saccular aneurysms as a model for intracranial berry aneurysms. The use of such a wholly arterial aneurysmal model allows one to study the maturation and physiologic response to embolic materials, which more closely parallel those events that might occur in an individual patient.

On the basis of the work of Anidjar et al, we have isolated an arterial segment and perfused it with varying concentrations of porcine pancreatic elastase. Noting that the formation of abdominal aortic aneurysms requires a latent maturation phase long after elastase levels cease to be measurable, we allowed our aneurysms to mature over varying periods of time. However, unlike Anidjar's group, we have not noted the dose-response properties in the degree of elastic lamina disruption with increasing concentrations of elastase. Indeed, all our perfused sacs showed microscopic evidence of aneurysmal formation with elastic lamina degeneration, mild intimal fibrosis, and mild inflammatory infiltrate. All these aneurysms were histologically intact even up to 12 weeks, and although several were thrombosed, none showed evidence of scarring (an important finding given that the most bothersome long-term problem with venous aneurysmal models is fibrotic scarring). In fact, our lowest dose (10 U) of elastase may have been above the threshold for both microscopic and macroscopic aneurysmal formation.

Angiographic patency was not demonstrated in 93% of the aneurysms studied (the aneurysm that was not seen was evident at harvest and was noted to be thrombosed). However, at harvest only 40% of our aneurysms had a fully patent lumen, the others were filled with fibrin deposits and thrombus of varying age—once again, no aneurysm of any age had fibrotic scarring. The thrombotic problem is most likely due to inadequate flow dynamics within the lumen itself. The ideal proportion of aneurysmal neck to dome diameter that will result in improved flow dynamics and continued thrombosis-free patency remains to be delineated. In addition, experimentation in larger animals, which allows an absolute increase in the size of the aneurysm formed, may also result in greater patency rates. Gadowski et al (38) showed that by using the model developed by Anidjar's group, hypertension may accelerate the growth of aortic aneurysms. Induced hypertension may allow for similar increases in aneurysmal growth in our model, and may also result in higher patency rates. Such experiments are in progress.

In conclusion, while our findings are admittedly preliminary, we have shown the feasibility of creating an animal model of a true arterial saccular aneurysm. Basing our experimental

protocol on models of abdominal aortic aneurysms in rats, we have shown that the perfusion of an arterial stump with porcine pancreatic elastase reliably results in elastic lamina degradation and microscopic and macroscopic aneurysmal formation. The macroscopic and microscopic patency rate after various intervals was 40%; histologic study of the nonpatent lesions revealed intraluminal clot formation. In our opinion, aneurysmal scarring did not occur because the arterial endothelium was undisturbed by surgical manipulation. The problem of thrombosis may be due to inadequate flow dynamics in the aneurysmal lumen resulting from mismatched neck to dome ratios. This problem may be solved by using arterial stumps of varying sizes in larger animals as well as by using induced hypertension during and after sac formation. Once these obstacles are overcome, we believe our model will be superior to vein patch graft models in terms of the rate of scarring along the suture line. We also believe that our model more closely approximates the actual pathophysiology of naturally occurring aneurysms.

Acknowledgments

We gratefully acknowledge the assistance of Gabriella Schlidt and Mary Kay O'Brien in conducting these experiments.

References

1. Ronkainen A, Hernesniemi J. Subarachnoid hemorrhage of unknown etiology. *Acta Neurochir (Wien)* 1992;119:29–34
2. Sahs AL, Nibbelink DW, Torner JC, eds. *Aneurysmal Subarachnoid Hemorrhage: Report of the Cooperative Study*. Baltimore, Md: Urban & Schwarzenberg; 1981
3. Atkinson JL, Sundt TM Jr, Houser OW, Whisnant JP. Angiographic frequency of anterior circulation intracranial aneurysms. *J Neurosurg* 1989;70:551–555
4. Drake CG. Progress in cerebrovascular disease: management of cerebral aneurysms. *Stroke* 1981;12:273–283
5. Kiyohara Y, Ueda K, Hasuo Y, et al. Incidence and prognosis of subarachnoid hemorrhage in a Japanese rural community. *Stroke* 1989;20:1150–1155
6. Lindley JG, Wirth FP. Epidemiology of cerebral aneurysms. In: Ratcheson RA, Wirth FP, eds. *Concepts in Neurosurgery: Vol 6, Ruptured Cerebral Aneurysms: Perioperative Management*. Baltimore, Md: Williams & Wilkins; 1994:15–22
7. McCormick WF, Nofzinger JD. Saccular intracranial aneurysms: an autopsy study. *J Neurosurg* 1965;22:155–159
8. Pakarinen S. Incidence, aetiology, and prognosis of primary subarachnoid hemorrhage: a study based on 589 cases diagnosed in a defined urban population during a defined period. *Acta Neurol Scand (Suppl)* 1967;29:1–128

9. Phillips LH II, Whisnant JP, O'Fallon WM, Sundt TM Jr. The unchanging pattern of subarachnoid hemorrhage in a community. *Neurology* 1980;30:1034-1040
10. Sekhar LN, Heros RC. Origin, growth, and rupture of saccular aneurysms: a review. *Neurosurgery* 1981;8:248-260
11. Stehbens WE. *Pathology of the Cerebral Blood Vessels*. St Louis, Mo: Mosby; 1972:351-470
12. Casasco AE, Aymard A, Gobin P, et al. Selective endovascular treatment of 71 intracranial aneurysms with platinum coils. *J Neurosurg* 1993;79:3-10
13. Molyneux AJ, Ellison DW, Morris J, Byrne JV. Histological findings in giant aneurysms treated with Guglielmi detachable coils: report of two cases with autopsy correlation. *J Neurosurg* 1995;83:129-132
14. Nichols DA, Meyer FB, Piepgras DG, Smith PL. Endovascular treatment of intracranial aneurysms. *Mayo Clin Proc* 1994;69:272-285
15. Anidjar S, Salzmann J-L, Gentric D, Lagneau P, Camilleri J-P, Michel J-B. Elastase-induced experimental aneurysms in rats. *Circulation* 1990;82:973-981
16. Pakes SP. *Guide for the Care and Use of Laboratory Animals: U.S. Department of Health and Human Services, Public Health Service*. Washington, DC: National Institutes of Health; 1985:85-123
17. German WJ, Black PW. Experimental production of carotid aneurysms. *N Engl J Med* 1954;250:104-106
18. Kerber CW, Buschman RW. Experimental carotid aneurysms, I: simple surgical production and radiographic evaluation. *Invest Radiol* 1977;12:154-157
19. Forbus WD. On the origin of miliary aneurysms of the superficial cerebral arteries. *Bull Johns Hopkins Hosp* 1930;47:239-284
20. Stehbens WE. Ultrastructure of aneurysms. *Arch Neurol* 1975;32:798-807
21. Steinberg GK, Chung M. Morphology and structural pathology. In: Awad IA, Barrow DL, eds. *Giant Intracranial Aneurysms*. Park Ridge, Ill: American Association of Neurological Surgeons; 1995:1-12
22. Glynn LE. Medial defects in the circle of Willis and their relation to aneurysm formation. *J Pathol Bact* 1940;51:213-222
23. Stehbens WE. Histopathology of cerebral aneurysms. *Arch Neurol* 1963;8:272-285
24. Stehbens WE. Etiology of intracranial berry aneurysms. *J Neurosurg* 1989;70:823-831
25. Akimoto Y. A pathological study of intracranial aneurysms particularly of aneurysms other than saccular ones. *Acta Pathol Jpn* 1980;30:229-239
26. Crawford T. Some observations on the pathogenesis and natural history of intracranial aneurysms. *J Neurol Neurosurg Psychiatry* 1959;22:259
27. Crompton MR. Mechanism of growth and rupture in cerebral berry aneurysms. *Br Med J* 1966;1:1138-1142
28. Hegedus K, Molnar P. Age-related changes in reticulin fibers and other connective tissue elements in the intima of major intracranial arteries. *Clin Neuropathol* 1989;8:92-97
29. Austin G, Fisher S, Dickson D, Anderson D, Richardson S. The significance of extracellular matrix in intracranial aneurysms. *Ann Clin Lab Sci* 1993;23:97-105
30. Kittelberger R, Davis PF, Stehbens WE. Distribution of type IV collagen, laminin, nidogen, and fibronectin in the haemodynamically stressed vascular wall. *Histol Histopathol* 1990;5:161-167
31. Lang ER, Kidd M. Electron microscopy of human cerebral aneurysms. *J Neurosurg* 1965;22:554-562
32. Andrews EJ, White WJ, Bullock LP. Spontaneous aortic aneurysms in Blotchy mice. *Am J Pathol* 1975;78:199-210
33. Economou SG, Taylor CB, Beattie EJ, Davis CB. Persistent experimental aortic aneurysms in dogs. *Surgery* 1960;47:21-28
34. Gertz SD, Kurgan A, Eisenberg D. Aneurysm of the rabbit common carotid artery induced by periarterial application of calcium chloride in vivo. *J Clin Invest* 1988;81:649-656
35. Lalich JJ. Aortic aneurysms in experimental lathyrism. *Arch Pathol* 1967;84:528-535
36. Yokoyama H, Matsuoka R, Bruyere HJ, Gilbert EF, Uno H. Light and electron-microscopic observations of theophylline-induced aortic aneurysms in embryonic chicks. *Am J Pathol* 1983;112:258-266
37. Halpern VJ, Nackman GB, Gandhi RH, et al. The elastase infusion model of experimental aortic aneurysms: synchrony of induction of endogenous proteinases with matrix destruction and inflammatory cell response. *J Vasc Surg* 1994;20:51-60
38. Gadowski GR, Ricci MA, Hendley ED, Pilcher DB. Hypertension accelerates the growth of experimental aortic aneurysms. *J Surg Res* 1993;54:431-436