



Get Clarity On Generics

Cost-Effective CT & MRI Contrast Agents



FRESENIUS
KABI

WATCH VIDEO

AJNR

MR features of an intracerebellar chloroma.

K Parker, M Hardjasudarma, R L McClellan, M R Fowler and J W Milner

AJNR Am J Neuroradiol 1996, 17 (8) 1592-1594

<http://www.ajnr.org/content/17/8/1592>

This information is current as
of August 19, 2025.

MR Features of an Intracerebellar Chloroma

Keith Parker, Mardjohan Hardjasudarma, Russell L. McClellan, Marjorie R. Fowler, and Joseph W. Milner

Summary: Granulocytic sarcoma (chloroma) is a rare tumor almost always associated with leukemia. Intraaxial brain lesions are rare, and can mimic infection or primary neoplasm. This intracerebellar chloroma arose after autologous bone marrow transplantation in a 29-year-old woman with leukemia. On T1-weighted MR images, the lesion was isointense with gray matter, and enhanced homogeneously. On T2-weighted and proton density-weighted MR sequences, the center was isointense with gray matter and the periphery was isointense with white matter. The lesion's tendency to remain isointense on sequences with long repetition times is presumably attributable to the presence of myeloperoxidase.

Index terms: Cerebellum, neoplasms; Chloroma

Granulocytic sarcoma (chloroma) of the brain is a rare finding. We report the magnetic resonance (MR) imaging features of this lesion before and after administration of contrast material.

Case Report

Acute myelogenous leukemia was diagnosed in a 29-year-old woman in October 1994. She was started on chemotherapy and received an autologous bone marrow transplant 3 months later. In June 1995, she was admitted to our institution after a 2-month history of headaches that had been increasing in intensity. Apart from the headaches, her physical and neurologic examinations were normal. Findings at MR imaging (at 1.5 T) revealed a completely intraaxial superior vermician mass, which measured $17 \times 17 \times 15$ mm. The lesion was isointense with gray matter on T1-weighted sequences (600/16/2 [repetition time/echo time/excitations]) (Fig 1A). Proton density-weighted (2500/30/1) and T2-weighted (2500/90/1) images (Fig 1B) showed the center to be isointense with gray matter, and the periphery of the lesion was isointense with white matter. There was marked homogeneous enhancement (Fig 1C). Results of a computed tomography (CT)-guided stereotactic brain biopsy revealed an almost solid mass of tumor cells. Pathologic examination was

consistent with chloroma (Fig 1D). The cells were histologically similar to those seen in a bone marrow biopsy specimen obtained several days later. Radiation treatment was initiated, but the headaches worsened. A CT scan showed no change from the previous studies. Within the next 24 hours, a left-sided hemiparesis and a right-sided palsy of the third cranial nerve developed. Repeat CT studies revealed massive intracranial hemorrhage in the right parietal lobe. Laboratory evaluation confirmed a blast crisis; the patient died en route to the operating room.

Discussion

Extramedullary soft-tissue masses are well-known complications of leukemia. Hemorrhage, infection, secondary neoplasm, and granulocytic sarcoma are the primary diagnostic considerations. The differential diagnosis is important, since all require specific therapy (1).

Granulocytic sarcoma is a solid tumor composed of immature granulocytes found in association with systemic leukemia, usually the myelogenous type (2). It can develop before, during, or after the onset of systemic leukemia (3). Granulocytic sarcoma can occur at any site, but is most commonly found in association with bone and nerve tissue. The orbit and epidural space are particularly likely to be involved (2). The term *chloroma* was coined by Kings in 1853 in reference to the lesion's typical green color (chlorine gas is green), which is caused by high levels of myeloperoxidase in immature cells (3, 4). Rappaport renamed the tumor granulocytic sarcoma, since approximately 25% of them are white, brown, or gray, depending on the variety of cell types involved (5).

Infiltration of the dura and subarachnoid space by leukemic cells via superficial arachnoidal veins and adventitia probably underlies the occurrence of intracranial chloromas. Dis-

Received September 5, 1995; accepted after revision December 15.

From the Departments of Radiology (K.P., M.H., R.L.M., J.W.M.) and Pathology (M.R.F.), Louisiana State University Medical Center, Shreveport.

Address reprint requests to M. Hardjasudarma, MD, Department of Radiology, Louisiana State University Medical Center, 1501 Kings Highway, Shreveport, LA 71130.

AJNR 17:1592-1594, Sep 1996 0195-6108/96/1708-1592 © American Society of Neuroradiology

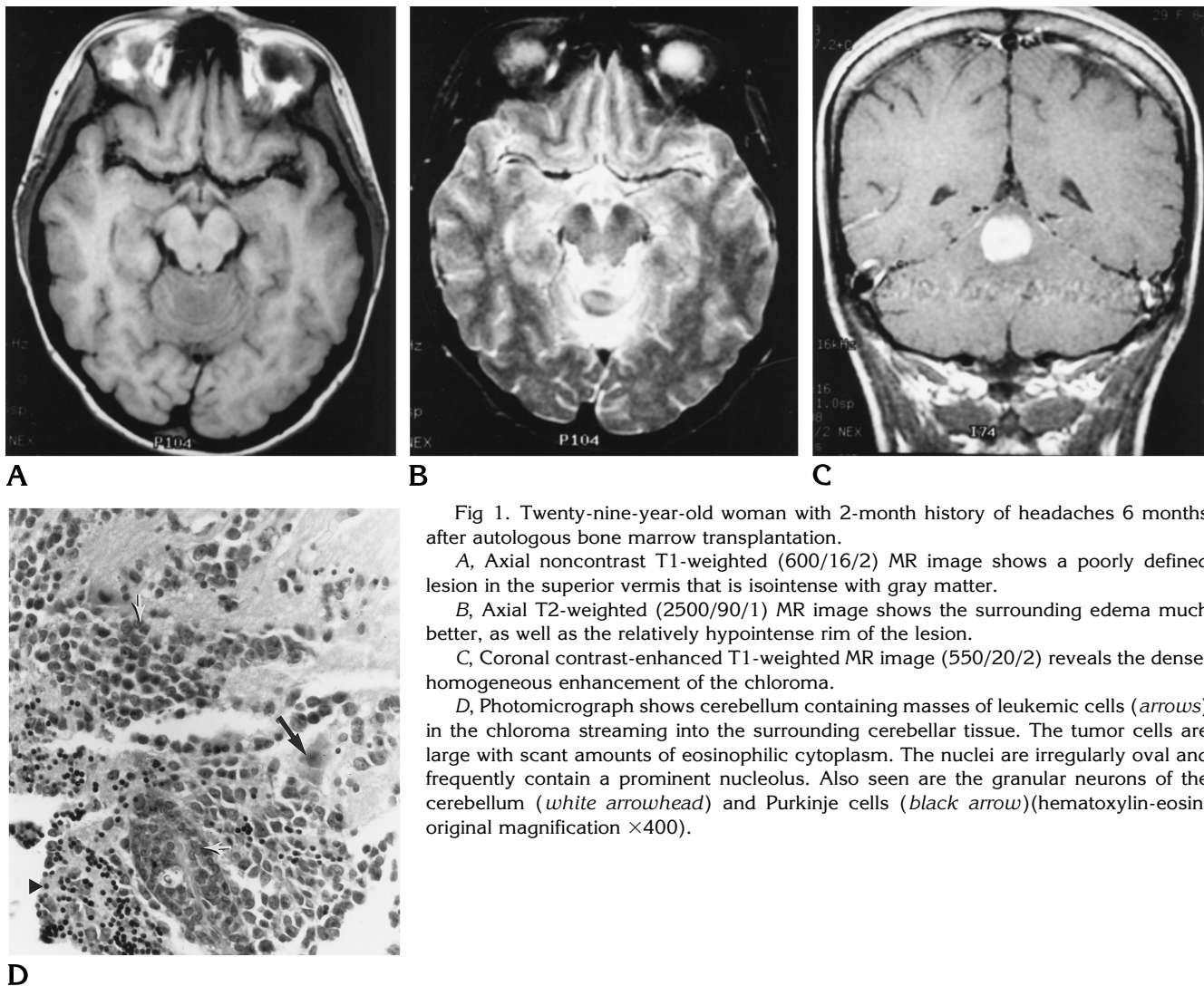


Fig 1. Twenty-nine-year-old woman with 2-month history of headaches 6 months after autologous bone marrow transplantation.

A, Axial noncontrast T1-weighted (600/16/2) MR image shows a poorly defined lesion in the superior vermis that is isointense with gray matter.

B, Axial T2-weighted (2500/90/1) MR image shows the surrounding edema much better, as well as the relatively hypointense rim of the lesion.

C, Coronal contrast-enhanced T1-weighted MR image (550/20/2) reveals the dense, homogeneous enhancement of the chloroma.

D, Photomicrograph shows cerebellum containing masses of leukemic cells (arrows) in the chloroma streaming into the surrounding cerebellar tissue. The tumor cells are large with scant amounts of eosinophilic cytoplasm. The nuclei are irregularly oval and frequently contain a prominent nucleolus. Also seen are the granular neurons of the cerebellum (white arrowhead) and Purkinje cells (black arrow)(hematoxylin-eosin; original magnification $\times 400$).

ruption of the pia-glial membrane may then allow the chloroma to become intraaxial (3). Chloromas of the brain are rare, and few have been reported in the literature (6)(J. P. Kochan, R. G. Peyster, B. H. Hershey, E. D. Hoover, "Chloroma: CT and MR Appearance of an Iron Laden Lesion," *AJNR Am J Neuroradiol* 1988; 9:1018, abstract). Interestingly, all intracerebral chloromas we found were reported in women. In an autopsy study of women with chloroma, a high rate of ovarian tumors was noted. This suggests that an endocrine factor may be responsible for the formation of these intraaxial masses (2).

The development of granulocytic sarcoma in patients with leukemia is a poor prognostic sign, and it almost always heralds an impending

blast crisis (7), as was the case in the patient reported here. Because of this, despite the radiosensitivity of the tumor, patients usually die within months after the lesion is discovered.

The MR characteristics of intracranial (not intraaxial) chloromas are fairly well established. In most reported cases, the lesions are hypointense to isointense on both T1-weighted and T2-weighted images (1, 3), with marked, homogeneous enhancement following contrast administration (1). Similar findings were seen in our case (Fig 1A, B, and C). The signal intensity of the lesion on the long-repetition-time sequences (Fig 1B) was presumably due to high levels of myeloperoxidase, an iron-containing enzyme normally found in white blood cells (Kochan et al, "Chloroma").

References

1. Pui MH, Fletcher BD, Langston JW. Granulocytic sarcoma in childhood leukemia: imaging features. *Radiology* 1994;190:698–702
2. Liu PI, Ishimaru T, McGregor DH, Okada H, Steer A. Autopsy study of granulocytic sarcoma (chloroma) in patients with myelogenous leukemia: Hiroshima-Nagasaki, 1949–69. *Cancer* 1973;31:948–955
3. Freedy RM, Miller KD Jr. Granulocytic sarcoma (chloroma): sphenoidal sinus and paraspinal involvement as evaluated by CT and MR. *AJNR Am J Neuroradiol* 1991;12:259–262
4. Kings A. A case of chloroma. *Month J Med Soc* (London and Edinburgh) 1853;19:97
5. Rappaport H. *Atlas of Tumor Pathology*, Sec 3, Fasc 8. Bethesda, Md: Armed Forces Institute of Pathology, 1966:241–243
6. Woo E, Yue CP, Mann KS, Cheung FMF, Chan TK, Todd D. Intracerebral chloromas. *Clin Neurol Neurosurg* 1986;88–2:135–139
7. Neuman RS, Barcos M, Berard C, et al. Granulocytic sarcoma: a clinicopathological study of 61 biopsied cases. *Cancer* 1981;48:1426–1437