



**Get Clarity On Generics**

Cost-Effective CT & MRI Contrast Agents

**FRESENIUS  
KABI**

**WATCH VIDEO**

**AJNR**

**Intracranial dural arteriovenous fistulas with spinal venous drainage: relation between clinical presentation and angiographic findings.**

L Brunereau, Y P Gobin, J F Meder, C Cognard, J M Tubiana and J J Merland

This information is current as of August 7, 2025.

*AJNR Am J Neuroradiol* 1996, 17 (8) 1549-1554  
<http://www.ajnr.org/content/17/8/1549>

# Intracranial Dural Arteriovenous Fistulas with Spinal Venous Drainage: Relation between Clinical Presentation and Angiographic Findings

Laurent Brunereau, Y. Pierre Gobin, Jean-François Meder, Christophe Cognard, Jean-Michel Tubiana, and Jean-Jacques Merland

**PURPOSE:** To investigate why some patients with an intracranial dural arteriovenous fistula (DAVF) with spinal venous drainage have myelopathy and others do not. **METHODS:** We reviewed the clinical and radiologic data for 12 patients who had a DAVF with spinal venous drainage diagnosed at our institutions from 1982 to 1995. **RESULTS:** Six patients had progressive spinal cord indications of disease (patients with myelopathy) and six others (patients without myelopathy) had cerebral indications (five had intracranial hemorrhage and one had a seizure). Cerebral angiography showed a posterior fossa DAVF with spinal venous drainage in all cases. The clinical presentation of DAVFs with spinal venous drainage was compared with the extent of the drainage. In patients without myelopathy, the spinal venous drainage exited the intradural canal via the cervical medullary-radicular veins and was therefore limited to the cervical perimedullary veins. In patients with myelopathy, no medullary-radicular vein was seen, and the venous drainage descended along the perimedullary veins of the entire spinal cord toward the conus medullaris. **CONCLUSION:** We found an exact relation between clinical presentation and venous drainage of DAVFs with spinal venous drainage. Patients had no myelopathy when the venous drainage was limited to the cervical cord; myelopathy was present when the venous drainage descended toward the conus medullaris.

**Index terms:** Fistula, arteriovenous; Spinal cord, myelopathy

*AJNR Am J Neuroradiol* 17:1549–1554, September 1996

Intracranial dural arteriovenous fistulas (DAVFs) are made up of a meshwork of arteriovenous shunts located within the intracranial dura. DAVFs are considered to be acquired, probably as a result of venous thrombosis (1), and may be located anywhere in the dura. Their angioarchitecture is that of an “arteriolo-venous fistula,” with multiple arteries converging into a single venous structure (2). DAVFs are primarily fed by dural

arteries, but high-flow DAVFs can recruit pial branches. Different patterns of venous drainage have been described, including drainage into a sinus with or without flow restriction or into cortical veins either directly or by reflux from a sinus (3–5). Signs and symptoms of DAVFs vary greatly. In adults, they can be divided into minor indications, such as bruit, cranial nerve paresis, and ocular signs, or major (aggressive) indications, such as hemorrhage, neurologic deficit, and signs of intracranial hypertension (3–6). The venous drainage of DAVFs is responsible for most signs and symptoms, especially the major ones, which is why DAVFs have been classified according to their venous drainage (3, 5).

DAVFs that have spinal perimedullary venous drainage and associated ascending myelopathy have recently been recognized (7). We found fewer than 25 cases in the literature (8–17). While reviewing a series of 258 patients with intracranial DAVFs with spinal venous drainage, we found six

---

Received August 22, 1995; accepted after revision February 21, 1996.

From the Service de Neuroradiologie et Angiographie Thérapeutique, Hôpital Lariboisière, Paris, France (L.B., C.C., J.J.M.); the Endovascular Therapy Service, UCLA Medical Center, Los Angeles, Calif (Y.P.G.); the Service de Neuroradiologie, Hôpital Saint-Anne, Paris, France (J.F.M.); and the Service de Radiologie, Hôpital Saint-Antoine, Paris, France (L.B., J.M.T.).

Address reprint requests to Laurent Brunereau, MD, Service de Radiologie, Hôpital Saint-Antoine, 184 Rue du Faubourg Saint-Antoine, 75012 Paris, France.

AJNR 17:1549–1554, Sep 1996 0195-6108/96/1708–1549

© American Society of Neuroradiology

patients who had an ascending myelopathy and, to our puzzlement, six others who had only cerebral indications, with no spinal cord disease. Therefore, we asked ourselves why some DAVFs with spinal venous drainage manifested with spinal cord disease and others did not. We found that a specific angiographic pattern was associated with spinal cord myelopathy.

## Materials and Methods

We reviewed the clinical and radiologic data for 12 patients who had intracranial DAVFs with spinal venous drainage. These patients were selected from 258 cases of intracranial DAVFs seen at our institutions between 1982 and 1995. Five of the patients who had myelopathy have been described previously (14).

Computed tomography (CT) was performed in the six patients with cerebral disorders. Myelography or spinal magnetic resonance (MR) imaging was the first examination performed in the six patients who had myelopathy. Cerebral angiograms were obtained in all cases and consisted of injections of the internal carotid, external carotid, and vertebral arteries. Superselective catheterizations were performed when appropriate. We reviewed the angiograms to ascertain the location of the DAVFs, the arterial feeders, and the draining veins. Particular attention was given to the extent of the

spinal perimedullary venous drainage of the DAVFs and its exit toward the epidural space. The perimedullary venous drainage was considered to be extensive when it continued below the cervical spinal cord.

Spinal angiography was performed in the six patients who had myelopathy. In five patients, this was done by selective catheterization of all the intercostal, lumbar, and sacral arteries and injection of 3 to 5 mL of contrast material over a period of 2 seconds. In one patient, the technique of bifemoral reflux was used (18), which consists of puncturing both femoral arteries with a 5F sheath and simultaneously injecting retrogradely 40 mL of contrast material at a rate of 20 mL/s. This technique enabled injection of the bilateral hypogastric, lumbar, and lower thoracic arteries without the need for selective catheterization, and was particularly useful in older patients. Venous drainage of the artery of Adamkiewicz was studied in three patients. Angiography in these cases was performed by injection of 8 mL of contrast material over 4 seconds in the intercostal or lumbar artery. Normally, venous drainage of the artery of Adamkiewicz occurs between 8 and 12 seconds (19).

## Results

The patients were divided into two groups: those with spinal cord signs and symptoms (group with myelopathy) and those with other

TABLE 1: Intracranial dural arteriovenous fistulas (DAVFs) with spinal venous drainage in patients without myelopathy

| Case | Age, y/<br>Sex | Clinical<br>Indications                       | Location<br>of DAVF    | Arterial<br>Feeders              | Cerebral Venous<br>Drainage                                                            | Spinal Venous Drainage                                                                       |
|------|----------------|-----------------------------------------------|------------------------|----------------------------------|----------------------------------------------------------------------------------------|----------------------------------------------------------------------------------------------|
| 1    | 44/M           | Transient<br>aphasia                          | Torcular               | Bilateral<br>occipital<br>artery | Reflux into main<br>sinuses, cortical<br>veins, and<br>peripontomesencephalic<br>veins | Peribulbar veins, cervical<br>ASV; drainage into the<br>epidural space at C-6                |
| 2    | 59/F           | SAH: mild<br>meningeal<br>symptoms            | Tentorium<br>cerebelli | R MMA,<br>R MHT                  | Reflux into cortical<br>veins and<br>peripontomesencephalic<br>veins                   | Peribulbar veins, cervical<br>PSV; drainage into<br>epidural space at C-4                    |
| 3    | 36/F           | SAH and<br>ventricular<br>hemorrhage,<br>coma | Tentorium<br>cerebelli | L MHT                            | Venous ectasia and<br>reflux into<br>peripontomesencephalic<br>veins                   | Peribulbar veins, cervical<br>ASV and PSV; drainage<br>into epidural space at C-4<br>and C-6 |
| 4    | 48/M           | SAH: mild<br>meningeal<br>symptoms            | Tentorium<br>cerebelli | R MMA                            | Reflux into cortical<br>veins and<br>peripontomesencephalic<br>veins                   | Peribulbar veins, cervical<br>ASV; drainage into<br>epidural space at C-6                    |
| 5    | 55/M           | SAH: mild<br>meningeal<br>symptoms            | Foramen<br>magnum      | L and R<br>PMA                   | Reflux into cortical<br>veins and<br>peripontomesencephalic<br>veins                   | Peribulbar veins, cervical<br>ASV; drainage into<br>epidural space at C-7                    |
| 6    | 63/F           | SAH and<br>ventricular<br>hemorrhage,<br>coma | Foramen<br>magnum      | L and R<br>PMA                   | Venous ectasia<br>draining into<br>peribulbar veins                                    | Peribulbar veins, cervical<br>ASV and PSV; drainage<br>into epidural space at C-6            |

Note.—SAH indicates subarachnoid hemorrhage; MMA, middle meningeal artery; MHT, meningohypophyseal trunk; PMA, posterior meningeal artery; ASV, anterior spinal vein; and PSV, posterior spinal vein.

TABLE 2: Intracranial dural arteriovenous fistulas (DAVFs) with spinal venous drainage in patients with myelopathy

| Case | Age, y/<br>Sex | Clinical<br>Indications                                                                 | Location of<br>DAVF    | Arterial<br>Feeders        | Cerebral Venous<br>Drainage                            | Spinal Venous Drainage                                                                                               |
|------|----------------|-----------------------------------------------------------------------------------------|------------------------|----------------------------|--------------------------------------------------------|----------------------------------------------------------------------------------------------------------------------|
| 1    | 35/F           | Progressive<br>tetraparesis<br>with bulbar<br>signs                                     | L transverse<br>sinus  | L MMA                      | Reflux into cortical<br>veins and<br>peripontine veins | Peribulbar veins, cervical ASV and<br>PSV descending toward thoracic,<br>conus medullaris, and cauda<br>equina veins |
| 2    | 37/M           | Progressive<br>tetraparesis<br>with bulbar<br>signs                                     | L petrosal<br>sinus    | L MMA                      | Reflux into peripontine<br>veins                       | Peribulbar veins, cervical ASV and<br>PSV descending toward conus<br>medullaris veins                                |
| 3    | 53/M           | Progressive<br>tetraparesis,<br>tetraplegic and<br>bulbar signs<br>after<br>laminectomy | Tentorium<br>cerebelli | L MHT                      | Reflux into periponto-<br>mesencephalic veins          | Peribulbar veins, cervical ASV and<br>PSV descending toward cauda<br>equina veins                                    |
| 4    | 69/M           | Progressive<br>paraplegia                                                               | L petrosal<br>sinus    | L APA, L<br>OccA           | Reflux into peripontine<br>veins                       | Peribulbar veins, cervical ASV and<br>PSV descending toward conus<br>medullaris veins                                |
| 5    | 68/F           | Progressive<br>paraplegia                                                               | L petrosal<br>sinus    | L APA, L<br>MMA, L<br>OccA | Reflux into peripontine<br>veins                       | Peribulbar veins, cervical PSV<br>descending toward cauda equina<br>veins                                            |
| 6    | 69/M           | Progressive<br>paraparesis                                                              | Tentorium<br>cerebelli | L MHT                      | Reflux into<br>perimesencephalic<br>veins              | Peribulbar veins, cervical ASV and<br>PSV descending toward conus<br>medullaris veins                                |

Note.—MMA indicates middle meningeal artery; MHT, meningohypophyseal trunk; APA, ascending pharyngeal artery; OccA, occipital artery; ASV, anterior spinal vein; and PSV, posterior spinal vein.

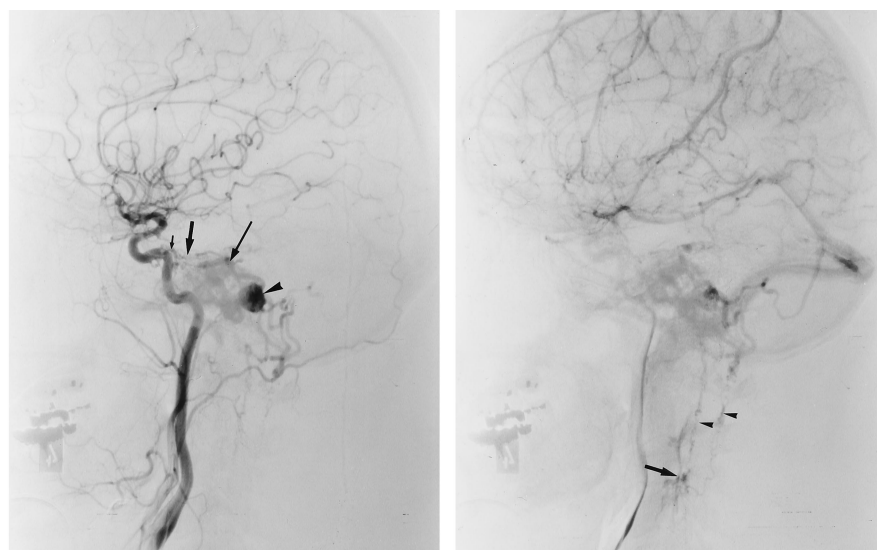


Fig 1. Lateral views of left common carotid artery angiograms in a 36-year-old woman with posterior fossa hemorrhage.

A, The arterial phase shows a DAVF of the tentorium cerebelli (*wide arrow*) fed by the left meningohypophyseal trunk (*short arrow*) and draining into the perimesencephalic and peripontine veins (*long arrow*). A venous varix (*arrowhead*) was probably the cause of the hemorrhage.

B, The venous phase shows the spinal perimedullary venous drainage into the anterior and posterior spinal veins (*arrowheads*) and their drainage into the epidural plexus (*arrow*).

indications (group without myelopathy). The findings of the two groups are summarized in Tables 1 and 2.

#### Clinical Data

Six patients had no myelopathy; these included three men and three women, 36 to 63

years old (mean, 50 years). Five of the patients had subarachnoid hemorrhage; three of these had mild to moderate meningeal syndrome and two were comatose. CT scans showed a posterior fossa subarachnoid hemorrhage in all five, with blood in the fourth ventricle in the two who were comatose. The sixth patient had an apha-

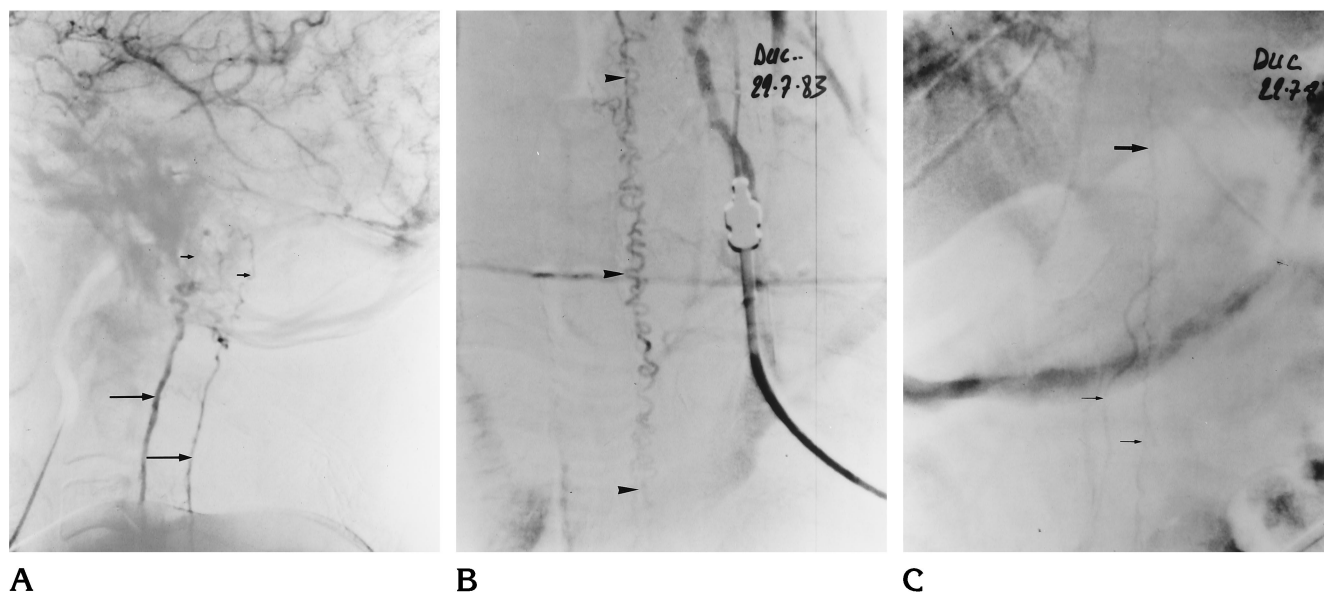


Fig 2. Left common carotid artery angiograms in a 53-year-old man with a progressive ascending myelopathy leading to tetraplegia. A, Lateral view shows a DAVF of the tentorium cerebelli draining into the anterior and posterior spinal veins (*long arrows*) via the pontomesencephalic veins (*short arrows*).

B, Anteroposterior view of the cervical spine shows the venous drainage into the spinal perimedullary veins of the cervical cord (*arrowheads*). No medullary-radicular vein was seen and the venous drainage continued toward the thoracic spinal cord.

C, Anteroposterior view of the lower thoracic spine 60 seconds after start of the injection shows opacification of thoracic spinal perimedullary veins (*large arrow*) and the drainage into veins of the cauda equina (*small arrows*).

sia that lasted less than 24 hours. Noncontrast CT findings in this patient were normal.

Six patients had progressive ascending myelopathy; these included four men and two women, 35 to 69 years old (mean, 55 years). All six had a progressive sensorimotor deficit of the lower extremities with urinary dysfunction. In three patients, the deficit had ascended to the extent that there was a deficit in the upper extremities and the patients had trouble swallowing. One patient deteriorated abruptly after a cervical laminectomy. Five of these patients had myelography, which showed filling defects caused by enlarged perimedullary veins.

In three of these cases, T1-weighted MR images of the spinal cord showed perimedullary flow voids; in one case, T2-weighted images showed perimedullary flow voids and a central hyperintense signal of the cervical spinal cord.

#### Angiographic Data

In the six patients with cerebral signs and symptoms (without myelopathy), cerebral angiography revealed a DAVF with spinal venous drainage located at the torcular in one case, at the tentorium cerebelli in three cases, and at the foramen magnum in two cases. The DAVFs

were fed by dural branches of the external carotid, internal carotid, and vertebral arteries (Table 1). The initial venous drainage reached the perimesencephalic, peripontine, or peribulbar veins and descended into the cervical spinal perimedullary veins: the anterior spinal vein (three cases), the posterior spinal vein (one case), or both (two cases). The cervical spinal perimedullary veins drained into the cervical epidural venous plexus between the C-4 and C-7 levels (Fig 1).

In the group of six patients with myelopathy, angiographic exploration began with a spinal angiogram. This did not show any abnormality during the arterial phase. However, the venous drainage of the artery of Adamkiewicz was studied in four of the six cases, and in three of these, normal venous drainage was not seen, raising the possibility of spinal cord venous hypertension and prompting a cerebral angiogram. In the fourth case, spinal angiography was performed during a period of remission after a bout of paraparesis. Normal venous drainage of the artery of Adamkiewicz was seen, which stopped the angiographic exploration. However, the patient deteriorated again a few weeks later, and as the second spinal angiogram showed stagnation in the artery of Adamkiewicz, we ob-

tained a cerebral angiogram in addition to the spinal angiogram.

Cerebral angiography showed a DAVF with spinal venous drainage located at the left transverse sinus in one case, at the left superior petrosal sinus in three cases, and at the tentorium cerebelli in two cases. The DAVFs were fed by dural branches of the external and internal carotid arteries (Table 2). The initial venous drainage reached the perimesencephalic, peripontine, or peribulbar veins and descended into the cervical spinal perimedullary veins: the posterior spinal vein in one case and both the anterior and posterior spinal veins in five cases.

The cervical spinal perimedullary veins did not drain into the cervical epidural venous plexus. Rather, the venous drainage slowly descended along the thoracic perimedullary veins. It took 40 to 60 seconds for the contrast medium to reach the thoracic spinal cord or the veins of the cauda equina. When it reached the lower thoracic area, the venous drainage was so stagnant that no exit toward the epidural veins could be seen. In three cases, additional drainage into the veins of the cauda equina was demonstrated (Fig 2).

## Discussion

As in previously reported cases, this series shows that DAVFs with spinal venous drainage involve men and women equally (7–17). Onset of signs and symptoms is most common between the third and sixth decade of life. There was no significant difference in gender or age between the patients who exhibited myelopathy and those who did not. The two groups of patients were clearly delineated and no patient had mixed signs and symptoms.

In the group with myelopathy, the main clinical presentation was a slowly progressive ascending myelopathy involving first the lower then the upper limbs. Bulbar symptoms, like trouble swallowing, were the last to appear. Because of the myelopathy, myelography or, in the recent cases, spinal MR imaging was the first examination performed, and was followed by spinal angiography. The myelograms were always abnormal in our series, as in the literature (7, 9–17).

Of 12 cases in the literature (10, 13–17), spinal T2-weighted MR images showed a central hyperintense signal of the cervical spinal cord in 3 cases (10, 13), of the thoracic spinal

cord in one case (15), and of the conus medullaris in one case (16). T1- or T2-weighted MR images showed perimedullary flow voids corresponding to the enlarged perimedullary veins in seven cases (10, 14–17). Spinal MR findings were considered normal in one case (17). According to the literature, spinal MR in our series showed perimedullary flow voids in two cases and a central hyperintense signal of the cervical spinal cord on T2-weighted images in one case.

The thorough spinal angiographic studies could not locate the DAVFs. However, a study of the venous drainage of the artery of Adamkiewicz showed stagnation of contrast material in the artery of Adamkiewicz, and the draining veins could not be seen when the patient was symptomatic. This finding has also been reported in other cases of spinal DAVFs with perimedullary venous drainage (20, 21), and is highly suggestive of spinal cord venous hypertension.

Cerebral angiography with catheterization of internal carotid, external carotid, and vertebral arteries was the key to the diagnosis. It showed the DAVFs with spinal venous drainage to be located in the posterior fossa. Drainage of the DAVFs through the enlarged spinal perimedullary veins could be followed downward along the entire spinal cord. While normally there are numerous medullary-radicular veins draining the blood from the spinal cord to the epidural space in the cervical and thoracic areas (22), none was seen in these cases. Such slow and extensive venous drainage has also been described in spinal DAVFs, in which there is lack of drainage of the perimedullary veins into the epidural veins (21). The consequence is spinal cord venous hypertension, which is observed not only in spinal or intracranial DAVFs with spinal perimedullary venous drainage but also in a few intradural arteriovenous fistulas and arteriovenous malformations that have an extensive ascending or descending perimedullary venous drainage (23).

The other six patients had intracranial hemorrhage ( $n = 5$ ) or a focal neurologic deficit ( $n = 1$ ) but no myelopathy. Because attention was drawn to an intracranial disorder, CT and cerebral angiography were performed rapidly. Cerebral angiography found the DAVF, but no particular attention was paid to the spinal perimedullary venous drainage. It was not until we were reviewing our series of intracranial DAVFs that we spotted the spinal venous drainage. These six patients are similar to two other patients reported previously who had a DAVF with

TABLE 3: Classification of intracranial dural arteriovenous fistulas

| Type | Description                                                                                      |
|------|--------------------------------------------------------------------------------------------------|
| 1    | Drainage into a sinus without flow restriction                                                   |
| 2    | Drainage into a sinus with flow restriction and reflux into other sinuses or into cortical veins |
| 3    | Drainage into a cortical vein                                                                    |
| 4    | Drainage into a cortical vein with a large varix                                                 |
| 5    | Spinal perimedullary venous drainage                                                             |

spinal venous drainage but no myelopathy (13, 24). The common angiographic characteristic of these patients is that the spinal perimedullary veins draining the DAVF could be followed down to the cervical spinal cord only. At the cervical level, the perimedullary veins drained into the epidural veins via a medullary-radicular vein. This drainage prevented the spinal cord venous hypertension.

A classification of intracranial DAVFs according to their venous drainage was introduced in 1978 by Djindjian and Merland (3). The original classification included three types (types 1, 2, and 3 in Table 3). Later, two additional types were defined, type 4 (DAVF with a giant venous varix) and type 5 (DAVF with spinal venous drainage), because their clinical presentation was so uncommon. A recent review associated precisely the five types in this classification with the clinical presentation, the prognosis, and the therapeutic options for intracranial DAVF (5).

This series of 12 patients reveals the importance of the venous drainage of arteriovenous shunts in the central nervous system. There was an exact relation between the clinical presentation and the venous drainage of DAVFs: the patients who had myelopathy had extensive spinal venous drainage descending toward the lower thoracic spinal cord and the cauda equina, whereas the patients without myelopathy had venous drainage limited to the cervical spinal cord.

## References

- Mullan S. Reflections upon the nature and management of intracranial and intraspinal vascular malformations and fistulae. *J Neurosurg* 1994;80:606–616
- Houdart E, Gobin YP, Casasco A, Aymard A, Herbreteau D, Merland JJ. A proposed angiographic classification of intracranial arteriovenous fistulae and malformations. *Neuroradiology* 1993;35:381–385
- Djindjian R, Merland JJ. *Superselective Arteriography of the External Carotid Artery*. Berlin, Germany: Springer-Verlag; 1978:405
- Halbach VV, Higashida R, Hieshima G, Rosenblum M, Cahan L. Treatment of dural arteriovenous malformation involving the superior sagittal sinus. *AJNR Am J Neuroradiol* 1988;9:337–343
- Cognard C, Gobin YP, Pierot L, et al. Cerebral dural arteriovenous fistulas: clinical and angiographic correlation with a revised classification of venous drainage. *Radiology* 1995;194:671–680
- Awad I, Little J, Akrewi W, Ahl J. Intracranial dural arteriovenous malformations: factors predisposing to an aggressive neurological course. *J Neurosurg* 1990;72:839–850
- Woimant F, Merland JJ, Riche MC, et al. Syndrome bulbo-médullaire en rapport avec une fistule artério-veineuse méningée du sinus latéral à drainage veineux médullaire. *Rev Neurol (Paris)* 1982;138:559–566
- Symon L, Kuyama H, Kendall B. Dural arteriovenous malformations of the spine: results in 55 cases. *J Neurosurg* 1984;60:238–247
- Picard L, Bracard S, Moret J, Per A, Giacobbe HL, Roland J. Spontaneous dural arteriovenous fistulas. *Semin Intervent Radiol* 1987;4:219–241
- Wrobel CJ, Oldfield EH, Di Chiro G, Tarlov EC, Baker RA, Doppman JL. Myelopathy due to intracranial dural arteriovenous fistulas draining intrathecally into spinal medullary veins: report of three cases. *J Neurosurg* 1988;69:934–939
- Gaensler EH, Jackson DE, Halbach VV. Arteriovenous fistulas of cervicomedullary junction as a cause of myelopathy: radiographic findings in two cases. *AJNR Am J Neuroradiol* 1990;11:518–521
- Willinski R, Terbrugge K, Lasjaunias P, Montaner W. The variable presentation of craniocervical and cervical dural arteriovenous malformations. *Surg Neurol* 1990;34:118–123
- Rivierez M, Gazengel J, Chiras J, et al. Les fistules artério-veineuses vertébro-durales du trou occipital à drainage médullaire: deux observations. *Neurochirurgie* 1991;37:179–184.
- Gobin YP, Rogopoulos A, Aymard A, et al. Endovascular treatment of intracranial dural arteriovenous fistulas with spinal perimedullary venous drainage. *J Neurosurg* 1992;77:718–723
- Partington MD, Rufenacht DA, Marsh WR, Piepgras DG. Cranial and sacral arteriovenous fistulas as a cause of myelopathy. *J Neurosurg* 1992;76:615–622
- Vasdev A, Lefournier V, Besson P, Dematteis M, Crouzet G. Les fistules durales intracrâniennes à drainage perimédullaire: a propos de deux observations. *J Neuroradiol* 1994;21:134–154
- Versari PP, D'Aliberti G, Talimonti G, Branca V, Boccardi E, Collice M. Progressive myelopathy caused by intracranial dural arteriovenous fistula: report of two cases and review of the literature. *Neurosurgery* 1993;33:914–919
- Melki JP, Riche M, Reizine D, Merland JJ. Approche de la vascularisation médullaire par artériographie bifémorale. *Presse Med* 1985;14:1152–1153
- Launay M, Chiras J, Bories J. Angiography of the spinal cord venous phase: normal features, pathological application. *J Neuroradiol* 1979;6:287–315
- Willinsky R, Lasjaunias P, Terbrugge K, Hurth M. Angiography in the investigation of spinal dural arteriovenous fistula: a protocol with application of the venous phase. *Neuroradiology* 1990;32:114–116
- Merland JJ, Riche MC, Chiras J. Intraspinale extramedullary arteriovenous fistulae draining into the medullary veins. *J Neuroradiol* 1980;7:271–320
- Thron A. *Vascular Anatomy of the Spinal Cord*. Berlin, Germany: Springer-Verlag; 1988:11
- Gobin YP, Houdart E, Casasco A, Merland JJ. Endovascular therapy for arteriovenous malformations and fistulas of the spinal cord. *Semin Intervent Radiol* 1993;10:227–242
- Houser OW, Baker HL, Rhoton AL, Okazaki H. Intracranial dural arteriovenous malformations. *Radiology* 1972;105:55–64