



## Get Clarity On Generics

Cost-Effective CT & MRI Contrast Agents

**FRESENIUS  
KABI**

[WATCH VIDEO](#)

# AJNR

### **Congenital arhinia.**

V S Albernaz, M Castillo, S K Mukherji and I H Ihmeidan

*AJNR Am J Neuroradiol* 1996, 17 (7) 1312-1314

<http://www.ajnr.org/content/17/7/1312>

This information is current as  
of August 13, 2025.

---

# Congenital Arhinia

Vanessa S. Albernaz, Mauricio Castillo, Suresh K. Mukherji, and Ismail H. Ihmeidan

**Summary:** In a case of congenital absence of the nose, spiral axial CT showed a tiny piriform anterior aperture on the right that ended blindly. Three-dimensional reformation of CT data showed an atretic bony plate, blind-ending right nostril, absent nasal bones, and inferior continuation of the metopic suture. Noncontrast MR findings in the brain were normal.

**Index terms:** Infants, newborn; Nose, abnormalities and anomalies

Congenital absence of the nose (arhinia) is extremely rare. In our review of the literature, we found 17 cases. Arhinia leads to severe airway impairment and poor feeding in the neonate. CT is helpful in determining the thickness of the atretic plate and the size of the underlying nasal cavities. Because arhinia may also be associated with multiple cerebral anomalies, magnetic resonance (MR) imaging of the brain should be performed in these patients.

## Case Report

A full-term boy was born via an uncomplicated vaginal delivery. The 26-year-old mother reported a normal pregnancy. Prenatal care, including sonographic findings, was normal. At birth, the baby showed absence of the nose with presence of a rudimentary and blind-ending right nostril. The root of the nose was also absent. Slight hypertelorism was present. Owing to severe respiratory difficulty, a tracheostomy was performed. Spiral axial computed tomographic (CT) scans with 3-mm-thick sections were obtained (Fig 1). Axial CT scans showed a tiny piriform (anterior) aperture on the right that ended blindly. The distance between the medial walls of the maxillary sinuses was diminished, and the nasal septum and turbinates were absent. Soft tissue filled the small and rudimentary nasal cavities. The posterior choanae were also reduced in diameter. The hard palate was well formed but arched superiorly. The ethmoidal sinus complexes and maxillary sinuses were not present. Three-dimensional reformation of CT data showed the atretic bony plate, blind-ending right nostril, absent nasal bones, and inferior continuation

of the metopic suture. Findings on noncontrast MR images of the brain were normal. It was decided to postpone reconstruction of the nose until the patient reaches preschool age.

## Discussion

The formation of the face is preceded by wavelike migrations of cranial neural crest cells from the region of the trigeminal nerves to the face (1). These cells establish the mesodermal elements that later develop into the face. Development of the nose and its cavities occurs between 3 and 10 weeks of life (1). At 24 days of life, the face consists of a superior frontal process, paired bilateral maxillary processes in the midface, and paired bilateral mandibular processes caudally (2). The maxillary and mandibular processes are separated by the primitive mouth (stomodeum) (1). The nasal alae are formed by fusion of the nasal lateral and medial processes (2). The medial nasal processes fuse in the midline with the frontal prominence and result in the formation of the frontonasal process that gives origin to the columella, philtrum, upper lip, nasal bones, cartilaginous nasal capsule, and superior alveolar ridge (2). The nasal placodes, which are local thickenings of surface ectoderm, develop laterally to form the frontal process between the lateral and medial nasal processes during the 4th week of life (1). The nasal placodes invaginate to form the nasal pits during the 5th week of life. The nasal pits form the nostrils. Deeper within the face, fusion of the maxillary and frontal processes forms the rudimentary palatal shelves at 6 weeks of life. Cells within the nasal pits continue to migrate posteriorly to form the primitive nasal cavities, which are separated from the buccal cavity by the rudimentary palatal shelves (3). By the 9th

---

Received August 1, 1995; accepted after revision October 30.

From the Department of Radiology, University of North Carolina at Chapel Hill (V.S.A., M.C., S.K.M.), and the Department of Radiology, Sparks Regional Medical Center, Fort Smith, Ark (I.H.I.).

Address reprint requests to M. Castillo, MD, Radiology CB# 7510, University of North Carolina, 3324 Old Infirmary, Chapel Hill, NC 27599.

AJNR 17:1312-1314, August 1996 0195-6108/96/1707-1312 © American Society of Neuroradiology

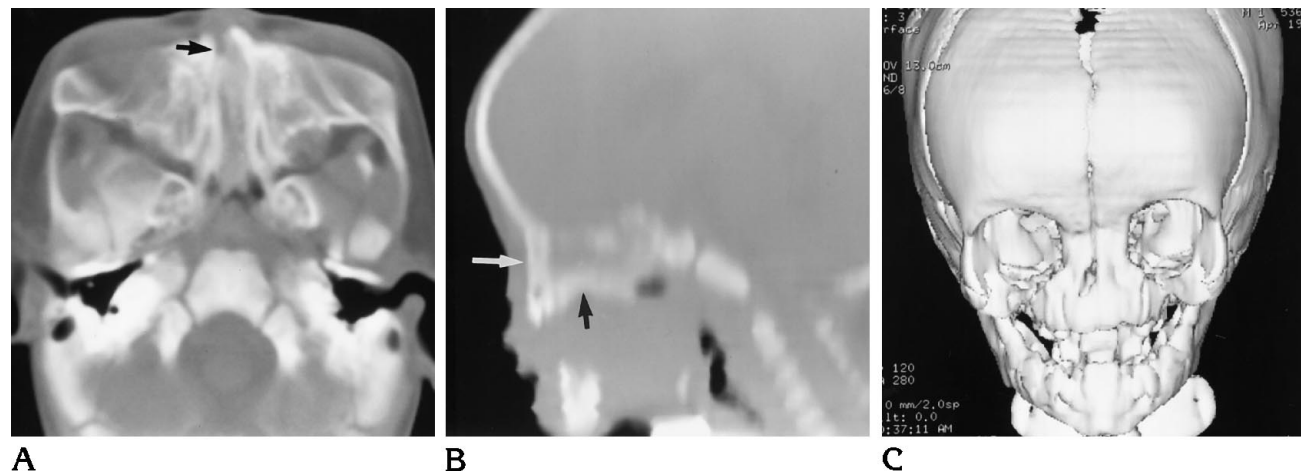


Fig 1. A, Axial CT scan shows blind-ending right nostril (*arrow*). Piriform aperture is narrowed and nasal cavities are filled by a combination of soft tissue/bone density. The nasal cavities are also narrowed.

B, Midsagittal CT reformation shows a high-arching hard palate (*black arrow*) and a thick, atretic, bony plate (*white arrow*) anteriorly.

C, Three-dimensional CT reformation shows an atretic bony plate and absence of piriform aperture and nasal bones. The metopic suture extends inferiorly into the atretic plate. The rudimentary right nostril and hypertelorism are well seen.

week of life, the cartilaginous nasal septum, which results from persistence of neural crest cells between the nasal cavities, directly overlies the buccal cavity (3). The palatal shelves of the maxillae migrate medially as the septum migrates inferiorly. By the 10th week of life, the palatal shelves and the inferior septum fuse to form the secondary palate (1). At this point, the posterior nasal cavities are separated from the buccal cavity by the buconasal membrane. This membrane ruptures, establishing communication between the nasal and buccal cavities. The primary posterior choanae, which are formed as the nasal cavities canalize, are promptly filled by epithelial plugs. These plugs eventually resorb to form the secondary (permanent) posterior choanae and establish the patency of the nasal cavities (3). It has been traditionally accepted that the epithelial plugs are present until the 24th week of life (1). However, recent evidence suggests that these plugs may actually resorb as early as the 15th week of life (3).

The pathogenesis of arhinia is poorly understood. It has been postulated that lack of development of the nose results from failure of the medial and lateral nasal processes to grow, but it is also possible that overgrowth and premature fusion of the nasal medial processes result in formation of an atretic plate. Arhinia may also result from lack of resorption of the nasal epithelial plugs during the 13th to 15th weeks of gestation. Another explanation may be related

to abnormal migration of neural crest cells to this region, resulting in aberrant flow of the multiple mesodermal structures required to establish the nose and its cavities normally.

In a review by Nishimura (3), 14 published cases of congenital absence of the nose were summarized. Subsequently, Nothen et al (4) and Muhlbauer et al (5) have reported additional cases of arhinia. The patient described by Muhlbauer et al (5) had arhinia in conjunction with a hereditary syndrome of multiple congenital abnormalities, including alobar holoprosencephaly and cleft lip and palate (5). The association between arhinia and cleft lip and palate is well established (3). One reported case of arhinia was associated with microphthalmia on the right and anophthalmia on the left (6). Two previously reported patients had chromosome 9 abnormalities (4). The remaining patients had no associated congenital malformations and were otherwise healthy (5, 7, 8).

The clinical consequences of congenital arhinia are severe airway obstruction and inability to feed. Placement of an oral airway should be performed in an acute setting (8). A surgically created nasal airway or a tracheostomy tube is an important part of early management, as either allows the infant to feed orally and precludes the complications associated with orogastric tubes (8). Most authors agree that surgical reconstruction of the external nose and inner cavities should be delayed at least until preschool years, when facial development is

nearly complete (6, 8). One case has been reported in which simultaneous reconstruction of both the internal and external nose was undertaken in the newborn period (5).

The degree of nasal absence varies from case to case. In our case, a thick bony atretic plate was present anteriorly in place of the nostrils. Within the bony plate, on the right, was a small bony depression representing a rudimentary nostril. The hard palate was well formed but it was located high and was arched superiorly. The ethmoidal sinuses were not aerated. Slight hypertelorism was present and the brain appeared normal on MR images. CT was helpful because it determined the thickness of the atretic plate and the small size of the nasal cavities, reinforcing the decision to delay reconstruction until these structures grow.

## References

1. Lee KJ. *Embryology of Clefts and Pouches: Essential Otolaryngology Head and Neck Surgery*. 3rd ed. New York, NY: Medical Examination Publishing; 1983:304–306
2. Castillo M. Congenital abnormalities of the nose: CT and MR findings. *AJR Am J Roentgenol* 1994;162:1211–1217
3. Nishimura Y. Embryological study of nasal cavity development in human embryos with reference to congenital nostril atresia. *Acta Anat (Basel)* 1993;147:140–144
4. Nothen MM, Knopile G, Fodisch HJ, Zerres K. Steinfeld syndrome: report of a second family and further delineation of a rare autosomal dominant disorder. *Am J Med Genet* 1993;46:467–470
5. Muhlbauer W, Schmidt A, Fairley J. Simultaneous construction of an internal and external nose in an infant with arhinia. *Plast Reconstr Surg* 1993;91:720–725
6. Weinberg A, Neuman A, Benmeir P, Lusthaus S, Wexler MR. A rare case of arhinia with severe airway obstruction: case report and review of the literature. *Plast Reconstr Surg* 1993;91:146–149
7. Cohen D, Groiten K. Arhinia revisited. *Rhinology* 1987;25:237–242
8. Cole RR, Myer CM, Bratcher GO. Congenital absence of the nose: a case report. *J Pediatr Otorhinolaryngol* 1989;17:171–177