



Providing Choice & Value
Generic CT and MRI Contrast Agents

**FRESENIUS
KABI**

CONTACT REP

AJNR

Traumatic luxation of the stapes evidenced by high-resolution CT.

P Herman, J P Guichard, T Van den Abbeele, C T Tan, J L Bensimon, R Marianowski and P Tran Ba Huy

AJNR Am J Neuroradiol 1996, 17 (7) 1242-1244
<http://www.ajnr.org/content/17/7/1242>

This information is current as of July 21, 2025.

Traumatic Luxation of the Stapes Evidenced by High-Resolution CT

P. Herman, J. P. Guichard, T. Van den Abbeele, C. T. Tan, J. L. Bensimon, R. Marianowski,, and Tran Ba Huy P

Summary: We encountered a case of acquired perilymphatic fistula in which the origin of the disease, namely, the stapes being medially displaced into the vestibule, was shown by thin-section CT. Accordingly, we recommend that every patient with suspected perilymphatic fistula of traumatic origin undergo high-resolution CT of the petrous bone.

Index terms: Ear, fistula; Ear, injuries; Temporal bone, computed tomography

Acquired perilymphatic fistula, which consists of an abnormal communication between the inner ear fluids and the middle air space, is one of the most challenging problems in otologic practice (1). Injury to the membranes of the oval window, round window, or both, results in fluid leakage and subsequent cochlear and/or vestibular symptoms, such as sudden or fluctuating hearing loss, tinnitus, dizziness, or vertigo. There is no universally accepted diagnostic technique, so that either this entity is often missed (2) or misdiagnosis leads to unnecessary surgery, since most authors recommend exploratory tympanotomy in every case of suspected perilymphatic fistula. Symptoms and clinical history of previous exogenous trauma or physical exertion remain the more reliable indicators of this abnormality (2). We report a case of posttraumatic perilymphatic fistula in which the origin was apparent on high-resolution, thin-section computed tomographic (CT) scans of the oval window.

Case Report

A 47-year-old woman experienced a brutal pain in the ear while cleaning with a cotton tip. Otoloscopic examination revealed a mild tympanic perforation and a moderate mixed hearing loss. She had moderate dizziness, but no nystagmus was observed. Conservative treatment was

chosen, and the patient was subsequently lost to follow-up.

Three years later, the patient was referred to our institution because of a disabling vertigo triggered by head movements and sneezing. At that time, complete deafness was diagnosed on the right side. Surprisingly, caloric and posturographic tests were normal. A fistula test, which consists of the application of external pressure to the external acoustic meatus (3), failed to elicit any vertigo or nystagmus. High-resolution CT of the middle ear was performed, in which joined 1-mm-thick sections in the axial and coronal plans were obtained (Figs 1 and 2).

The footplate of the stapes was found to be slightly displaced medially, with the presence of an opacity at the site of the oval window. This ear had no serviceable hearing, and as the patient's chief complaint was vertigo, a labyrinthectomy was performed through a posterior trans-labyrinthine approach under general anesthesia.

Drilling of the semicircular canals provided a wide exposure into the vestibule from behind, revealing an inward luxation of the stapes (Fig 3). Gentle palpation of the incus in the aditus induced a marked protrusion of the stapes into the inner ear. After complete removal of any vestibular structure, the cavity was filled with fat, and the postauricular wound was closed. Complete relief of symptoms was obtained, and follow-up examination was unremarkable.

Discussion

First reports of acquired perilymphatic fistula were as complications of otosclerotic surgery (4). Since then, various causes of perilymphatic fistula have been recognized, such as cholesteatoma or neoplasms of the middle ear. However, the most frequent cause is trauma, described by Fee in 1968 (5). Trauma might be from either external (blast or direct trauma to the tympanic drum) or internal (forced Valsalva maneuver, physical exertion) origin. In the case of suspected congenital perilymphatic fistula, CT is often performed to detect malformations

Received July 25, 1995; accepted after revision November 16.

From the Departments of ENT (P.H., R.M., T.B.H.) and Radiology (J.P.G.), Hôpital Lariboisière, Paris, France; the Department of ENT, Hôpital Robert Debré, Paris, France (T.V.D.A.); the Department of ENT, National Taiwan University Hospital, Taipei, Taiwan (C.T.T.); and Imagerie ORL, Paris, France (J.L.B.).

Address reprint requests to Philippe Herman, MD, Hôpital Lariboisière, Service ORL, 2, rue Ambroise Paré, 75010 Paris, France.

AJNR 17:1242-1244, Aug 1996 0195-6108/96/1707-1242 © American Society of Neuroradiology

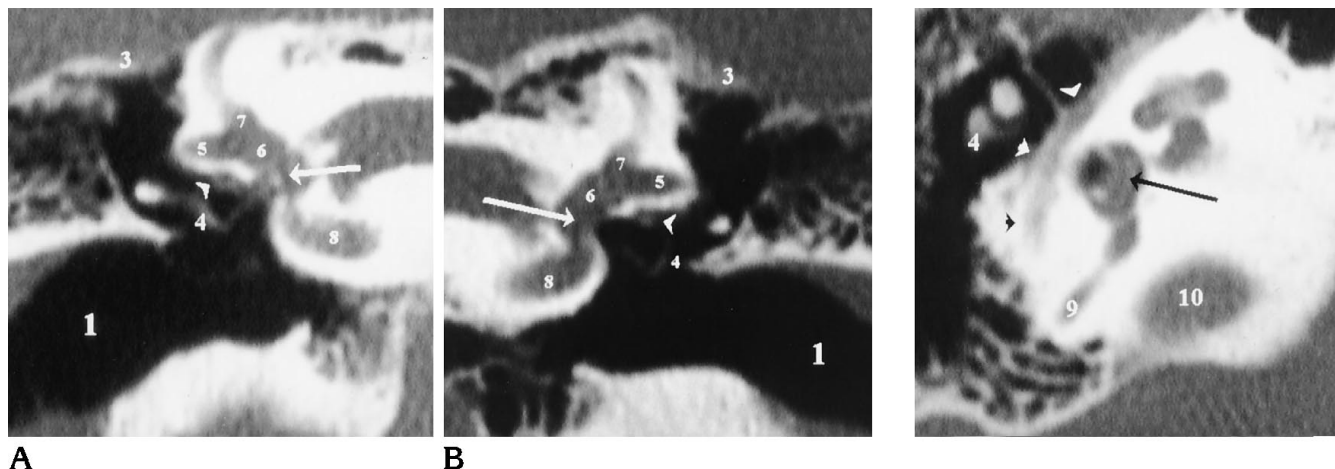


Fig 1. High-resolution coronal CT scans of the oval window.

Note the prolapse of the footplate of the stapes into the vestibule (*A*, *arrow*), as compared with the contralateral view (*B*, *arrow*). An opacity underneath the second portion of the seventh nerve (*arrowhead*, *A* and *B*) attests for the presence of fibrous tissue around the wound. The latter might be correlated with the high signal seen on MR images in some cases. 1 indicates external auditory canal; 3, tegmen antri; 4, incus; 5, external semicircular canal; 6, vestibular cavity; 7, ampulla of the superior semicircular canal; and 8, basal turn of the cochlea.

Fig 2. High-resolution axial CT scan of the oval window and second portion of the seventh nerve (*arrowheads*). Disruption and bulging of the footplate of the stapes into the vestibule (*arrow*) can be seen, while arches of the stapes remain intact. 4 indicates incus; 9, posterior semicircular canal; and 10, jugular fossa.

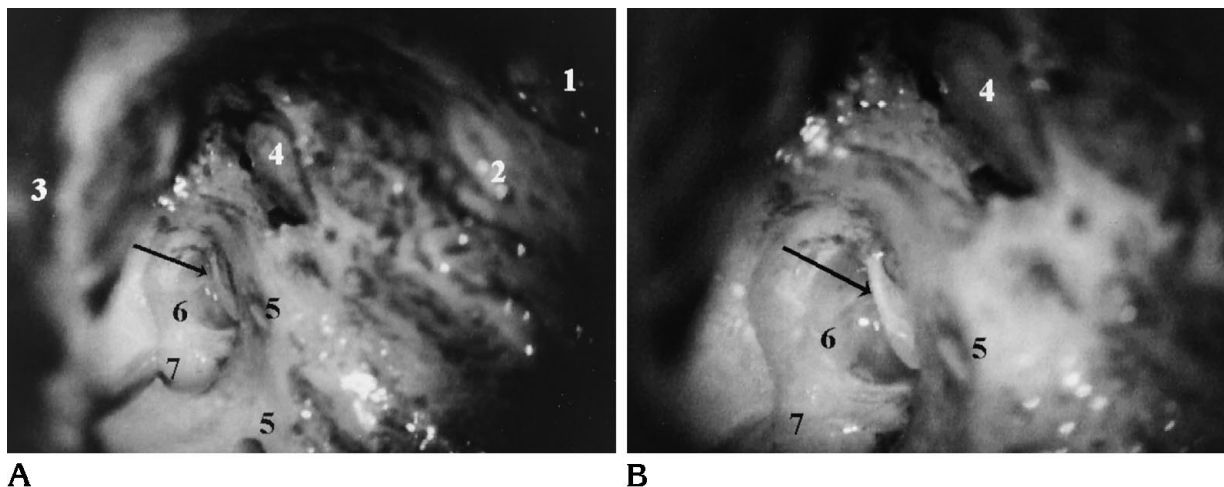


Fig 3. Intraoperative views of the labyrinthectomy cavity.

A, After mastoidectomy and removal of the bone between the amputated and nonamputated portions of the semicircular canals, vestibule is exposed from behind. Note prolapse of the footplate of the stapes (*arrow*) into the labyrinth cavity, which coincides with the CT findings.

B, Detail of the footplate bulging in the inner ear.

1 indicates external auditory canal; 2, posterior wall of the auditory canal; 3, tegmen antri; 4, incus; 5, external semicircular canal; 6, vestibular cavity; and 7, ampulla of the superior semicircular canal.

of the middle (6) or inner (7) ear, which might be predictive of perilymphatic fistula. In adults, while congenital bone abnormalities are thought to be absent, high-resolution CT, performed because of a history of head or tympanic trauma, may demonstrate fractures of the oval window

or of the footplate of the stapes, luxation of the footplate, or fractures involving the round window.

Our case establishes that high-quality, high-resolution CT of the temporal bone with very thin sections might facilitate an accurate diag-

nosis in cases of suspected perilymphatic fistula of traumatic origin, as evidenced by the relationship we found between the CT and surgical findings. Unfortunately, specially in the case of barotrauma (8), some cases may be related to membranous lesions at the round window, without detectable bone abnormality. In those cases, much is expected from the progress of magnetic resonance imaging, which, in these patients, might show indirect evidence of perilymphatic fistula, such as segmental enhancement of the cochlea on contrast-enhanced images (9, 10).

References

1. Podoshin L, Fradis M, Ben-David J, Berger SI. Perilymphatic fistula: the value of diagnostic tests. *J Laryngol Otol* 1994;108:560–563
2. House WJ, Morris MR, Kramer JS, Shesky GL, Coggan BB, Putter JS. Perilymphatic fistula: surgical experience in the United States. *Otolaryngol Head Neck Surg* 1991;105:51–59
3. Daspit CP, Churchill D, Linthicum FH. Diagnosis of perilymph fistula using ENG and impedance. *Laryngoscope* 1980;90:217–223
4. Lewis ML Jr. Inner ear complications of stapes surgery. *Laryngoscope* 1961;71:377–384
5. Fee GA. Traumatic perilymphatic fistula. *Arch Otolaryngol* 1968;88:477–480
6. Weber PC, Perez BA, Bluestone CD. Congenital perilymphatic fistula and associated middle ear abnormalities. *Laryngoscope* 1993;103:160–164
7. Vignaud J, Marsot-Dupuch K, Pharaboz C, Derosier C, Cordoliani Y. Imaging of the vestibule. *Otolaryngol Head Neck Surg* 1995;112:36–49
8. Pullen FW. Perilymphatic fistula induced by barotrauma. *Am J Otol* 1992;13:270–272
9. Morris MS, Kil J, Carvlin MJ. Magnetic resonance imaging of perilymphatic fistula. *Laryngoscope* 1993;103:729–733
10. Mark AS, Fitzgerald D. Segmental enhancement of the cochlea on contrast-enhanced MR: correlation with the frequency of hearing loss and possible sign of perilymphatic fistula and autoimmune labyrinthitis. *AJNR Am J Neuroradiol* 1993;14:991–996