



Providing Choice & Value

Generic CT and MRI Contrast Agents



**FRESENIUS
KABI**

CONTACT REP

AJNR

Accuracy of coregistration of single-photon emission CT with MR via a brain surface matching technique.

R E Hogan, M J Cook, C J Kilpatrick, D W Binns, P M Desmond and K Morris

This information is current as of July 31, 2025.

AJNR Am J Neuroradiol 1996, 17 (4) 793-797
<http://www.ajnr.org/content/17/4/793>

Accuracy of Coregistration of Single-Photon Emission CT with MR via a Brain Surface Matching Technique

R. Edward Hogan, Mark J. Cook, Christine J. Kilpatrick, David W. Binns, Patricia M. Desmond, and Kevin Morris

Summary: We describe a technique of brain surface matching of single-photon emission CT and MR images in human subjects and document the accuracy of this technique with the use of fiduciary markers. The mismatch averaged 4.3 mm as measured by the fiduciary markers and 2.1 mm as measured by the root mean square distance.

Index terms: Computed tomography, technique; Magnetic resonance, technique; Single-photon emission computed tomography

Numerous methods for coregistering images obtained by different techniques have been described. These include use of head-fixation devices (1), manual coregistration of images with computer assistance (2), use of fiduciary markers (3), use of fiduciary markers attached to a stereotaxic frame (4), and surface matching using the scalp surface (5–8). Turkington et al (9) described a surface-fitting algorithm to coregister images obtained with positron emission tomography (PET), single-photon emission computed tomography (SPECT), and magnetic resonance (MR) imaging using the surface of the brain, and documented the accuracy of this technique by using a brain phantom. We describe a technique for matching the brain surfaces on MR and SPECT images, and document the accuracy of this technique in human subjects by using fiduciary markers.

Materials and Methods

Image Acquisition and Fiduciary Marker Preparation

MR imaging was performed on a 1.5-T scanner. Whole brain acquisitions were obtained in the coronal plane with a fast spoiled gradient-echo technique and parameters of 14/3/2 (repetition time/echo time/excitations). Voxel dimensions were $0.859 \times 0.859 \times 1.5$ mm, the field of view was 22×22 cm, and the matrix size was 256×256 .

SPECT was performed on a triple-headed gamma camera with high-resolution parallel-hole collimators. Each detector rotated through a circular arc of 120° at a 13-cm radius of rotation. In total, 96 frames of 128×128 word data were acquired over 360° . Each frame was acquired for 80 seconds with a zoom factor of 1.45. Tomographic reconstruction was done by means of a filtered back-projection technique. Filtering incorporated a Shepp-Logan-Hanning (Siemens, Hoffman Estates, Ill) filter with a cut-off of 0.65 cycles per centimeter. Chang's first-order attenuation correction was performed on the transaxial sections. The cubic voxel dimension of acquired and reconstructed data was 2.46 mm. Data were converted to an unsigned character eight-bit format.

Technetium point sources for fiduciary markers were manufactured by introducing 1 Mbq of technetium-99m solution into 10 cm of vinyl tubing with an internal diameter of 0.6 mm. This requires a specific activity of approximately 20 Mbq/mL. Five-millimeter sections of tubing were then produced by cutting and sealing using a soldering iron. Each length of tubing was then placed inside a 5-mm length of 3-mm-internal-diameter vinyl tubing, cut, and sealed with a soldering iron. The optimal activity of the technetium point sources attached to the scalp of patients undergoing brain SPECT studies was approximately 0.02 Mbq per source. This was sufficient to enable accurate location of the position of the source without throwing ray-sum artifacts into adjacent cerebral tissue during the reconstruction process.

Technetium-labeled point sources were inserted into a 0.95-mL gelatin capsule that was filled with petrolatum (Vaseline) to make the fiduciary markers. Six to eight fiduciary markers were attached to the patient's scalp (two in the midline, the others distributed over the scalp) with high-viscosity collodion. Consecutive Tc hexamethylpropylenamine oxime (HMPAO) SPECT and MR studies were obtained after placement of the markers in five patients.

Coregistration of Data

Data were incorporated into a dedicated workstation for coregistration using the Analyze (Biomedical Imaging Re-

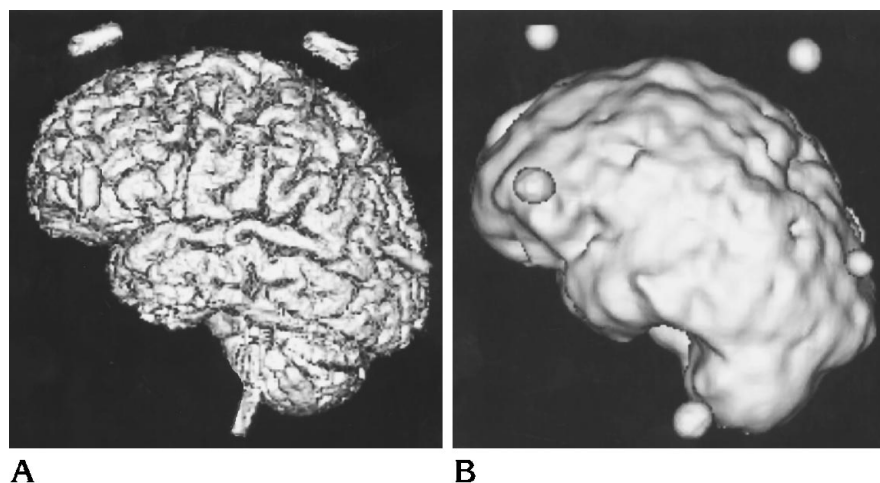
Received May 19, 1995; accepted after revision August 28.

From the Departments of Neurology (R.E.H., M.J.C., C.J.K.), Nuclear Medicine (D.W.B.), and Radiology (P.M.D.), The Royal Melbourne Hospital, Parkville, Victoria, Australia; and the Australian Computing and Communications Institute, Ltd, Carlton, Victoria, Australia (R.E.H., M.J.C., K.M.).

Address reprint requests to R. Edward Hogan, MD, Department of Neurology, St Louis University, 3635 Vista Ave, St Louis, MO 63110.

AJNR 17:793–797, Apr 1996 0195-6108/96/1704-0793 © American Society of Neuroradiology

Fig 1. Three-dimensional representations of coregistered binary MR (A) and SPECT (B) scans with superimposed fiduciary markers.



source, Mayo Foundation, Rochester, Minn) version 6.2 software system.

Acquired MR images were converted to eight-bit images and reformatted to cubic voxel dimensions. Binary images were produced to best emphasize the cortical surface of the brain by manually adjusting intensity thresholds. Interactive three-dimensional segmentation of the brain was then used, as described by Höhne and Hanson (10). *Erosion* and *autoconnect* steps were performed in one or two iterations, depending on the presence of signal from extraparenchymal structures after the first iteration. We then performed multiple conditional dilate operations, usually using one more iteration than the erosion and autoconnect iterations. Whole brain volumes were recorded from the binary reformatted MR image.

SPECT scans were converted to binary, again using thresholding to best approximate the cortical brain surface, followed by an autoconnect step. The SPECT brain volume was then measured. Steps were repeated, changing threshold values as needed, until the binary SPECT volume matched the MR volume to within 3% of the MR volume.

Binary MR and SPECT three-dimensionally rendered studies were then surface matched using the binary MR study as the base volume and the binary SPECT study as the match volume. This coregistration uses a chamfer matching technique. Chamfer matching is accomplished by performing a distance transformation that converts a binary-level image into a gray-level image. This technique has been fully described previously (11). Pixel dimensions from both images were considered during the fit. Default parameters were used for surface matching, with the exception of increasing the number of points sampled to 250. The final voxel dimension of the processed SPECT scans matched the MR imaging voxel dimension, which was 0.859 mm.

A single observer measured the coordinates of each marker on the MR and transformed SPECT scans independently. On MR scans, the technetium markers were visible within the vaseline. The middle of the marker was manu-

ally measured. On SPECT scans, the coronal section showing the greatest marker intensity was taken as the middle of that marker. The center of the marker on that section was measured manually. Measurements were obtained after transformation of the SPECT scans to MR imaging pixel dimensions. The differences in coordinates between a marker on the MR image and that on the transformed SPECT scan were then used to calculate distances between the marker on each image using voxel dimensions.

Results

Five patients had MR and SPECT studies with fiduciary markers in place. Examples of three-dimensionally reconstructed MR and transformed SPECT studies, with superimposed markers, are shown in Figure 1.

Results are summarized in the Table. A total of 33 points (from all patients) coregistered with an average error of 4.3 mm. The mismatch as measured by root mean square distance averaged for all studies was 2.1 mm. The largest

MR and SPECT coregistration mismatch data

Patient	Mean Discrepancy Between Markers, mm	Range of Discrepancies between Markers, mm	Root Mean Square Distance between Coregistered Binary MR and SPECT Scans, mm
1	2.9	1.7-4.6	1.9
2	4.6	0.9-8.0	2.3
3	4.4	1.7-7.0	1.9
4	4.1	2.8-6.9	2.1
5	5.3	3.6-7.6	2.4

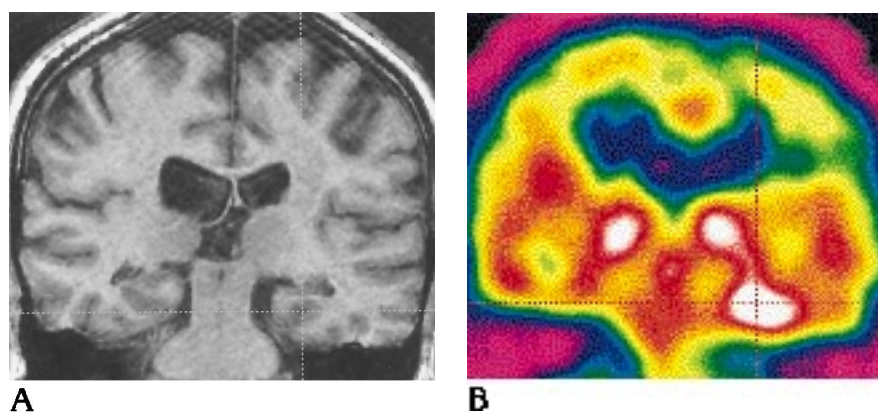


Fig 2. These MR (A) and coregistered ictal SPECT (B) scans show clear hyperperfusion over the mesial structures of the left temporal lobe.

error between a marker on a SPECT scan and one on an MR image was 8.0 mm.

Figure 2 shows a coronal MR view through the body of the hippocampus with a coregistered SPECT scan acquired after ictal injection of Tc HMPAO. This clearly shows hyperperfusion over the mesial structures of the left temporal lobe.

Discussion

There are several methods by which MR or CT scans can be used as anatomic templates for functional imaging studies. The use of fiducial markers (3), head-holding devices (1), or stereotaxic frames (4) provides fixed reference points for coregistration of images. The mismatch error in coregistration of SPECT and MR studies done with the use of fiducial markers has been documented with a phantom model to be no greater than 3 mm (3). However, marker techniques require acquisition of scans soon after application of the reference points, which can be impractical, as when obtaining ictal or periictal SPECT studies. Head-holding devices provide another means of coregistration, but precise positioning during each scan is difficult. The use of stereotaxic frames is invasive, which obviates its use in routine image coregistration. All the above methods require prospective planning of studies, making retrospective analysis of scans without markers impossible.

Registration techniques using surface-fitting methods have the advantage of requiring no special preparation or equipment at the time of image acquisition. Kapouleas et al (2) studied a computer-assisted manual coregistration technique that used the interhemispheric fissure as a reference point in axially sectioned scans. They

validated this technique by using an estimate of disagreement between multiple registrations of the same scans, and showed an average error of 3.8 mm. Fox et al (12) used a stereotaxic atlas to map PET studies. Both these methods require subjective decisions about PET anatomy. These techniques are more useful in PET than SPECT, given the higher resolution of PET.

Pelizzari et al (6) coregistered PET and MR images by means of a surface-fitting technique that used the scalp surface (6). They documented the accuracy of this method by using a phantom model. The mismatch error, using the residual root mean square distance, was 1.83 mm. This technique requires definition of the scalp surface on PET studies, which is time consuming. Holman et al (8) used this technique with SPECT and MR images, but did not quantify the coregistration error.

Turkington et al (9) documented the accuracy of the registration of PET, SPECT, and MR images using a brain phantom and brain surface matching. They used a surface-fitting technique that matched the brain surface of the phantom taken with the different imaging methods. Brain surfaces were determined by means of simple thresholding on MR images and first-derivative maxima on PET and SPECT images. Translational errors were less than 2 mm in each direction, and rotational errors were less than 2° in every case using this technique. However, they did not test their technique in human subjects.

Our technique of coregistration of SPECT and MR images also uses the brain surface for matching. Setting thresholds to best define the cortical surface on MR images was not difficult, since MR images are of high resolution. Be-

cause we used the total brain volume of the MR image to guide the final total brain SPECT volume, we did not have to make subjective decisions about the SPECT brain surface.

Validation of some of the above studies has depended on the use of a rigid phantom model to depict the human brain, presuming the brain is a solid, immobile object. Because the brain is a semisolid organ and is suspended in cerebrospinal fluid, it moves within the cranial vault with changes in position of the head. The intraparenchymal fluid and electrolyte content (and therefore the size) of the brain also vary with fluid and electrolyte changes (13). Therefore, these phantom models may not be representative of the true accuracy of these techniques in the clinical setting. Because changes in the brain vascular component volume can occur as a result of changes in blood flow (14), perictal SPECT scans are especially subject to volume changes. Use of the brain surface for coregistration has been described as less accurate than scalp surface matching because of inaccuracies in surface rendering of the brain surface on MR images (6). However, it will partially compensate for changes in brain position within the cranial vault.

The average error of our coregistrations is higher than that reported in other studies (3, 6, 9). This may be the result of several factors in addition to changes in brain size and shape as discussed above. The markers introduce a degree of error relating to the elasticity of the skin and to distortions caused by the head clamps. Also, since rotations around the x-axis cause the greatest error in coregistration of the brain surface (9), the position of our markers on the scalp will produce a greater error measurement than would occur at structures near the center of the brain. Given the above factors, our average error of 4.2 mm is probably an overestimation of the coregistration mismatch. This degree of accuracy is greater than the resolution of our SPECT images, which was approximately 10 mm. The root mean square distance calculated by the mismatch of the binary rendered images is somewhat less than that measured by the markers in each coregistered study. Since this value is determined by calculating the error in the matching of transformed images, it may not reflect the true accuracy of the coregistration. Artifacts in the acquisition or processing of image data will artificially increase the root mean square distance, while matching of symmetrical

surfaces can artificially decrease the root mean square distance. An extreme example of the latter circumstance would be a sphere, which would show a small root mean square distance regardless of its rotational mismatch. Because of these factors, the fiducial markers are a better test of true coregistration mismatch. Further studies using fiducial markers fixed to unmovable structures may show better results using a brain surface matching technique.

We have demonstrated a technique for coregistration of SPECT and MR scans that is accurate to approximately 4 mm. Using our semiautomated technique, an experienced operator took 40 minutes to coregister the MR and SPECT images. A considerable amount of this time was consumed by computer processing, so the technique will be faster on newer-generation computers. We have included an example of coregistered ictal SPECT and MR scans that clearly shows a region of hyperperfusion over the left mesial temporal area. This technique is useful in coregistration of MR images with ictal Tc-HMPAO SPECT scans in patients with epilepsy, because it helps to show patterns of ictal perfusion. Further study of coregistered SPECT and MR studies in larger numbers of patients with epilepsy may help identify perfusion patterns to better locate the region of seizure onset.

References

1. Coubes P, Kotski PO, Baldy-Moulinier M, Frerebeau P, Rossi M. Superimposing anatomical and functional brain images: a reference system method for localization of the epileptogenic zone. In: Baldy-Moulinier M, Lassen NA, Engel J, Askienazy S, eds. *Current Problems in Epilepsy: Focal Epilepsy: Clinical Use of Emission Tomography*. 7th ed. London: John Libbey and Company Ltd, 1990:53-63.
2. Kapouleas I, Alavi A, Alves WM, Gur RE, Weiss DW. Registration of three-dimensional MR and PET images of the human brain without markers. *Radiology* 1991;181:731-739.
3. Erickson BJ, Jack CR Jr. Correlation of single photon emission CT with MR image data using fiducial markers. *AJNR Am J Neuroradiol* 1993;14:713-720.
4. Zhang J, Levesque MF, Wilson CL, et al. Multimodality imaging of brain structures for stereotactic surgery. *Radiology* 1990;175:435-441.
5. Levin DN, Hu XP, Tan KK, et al. The brain: integrated three-dimensional display of MR and PET images. *Radiology* 1989;172:783-789.
6. Pelizzari CA, Chen GT, Spelbring DR, Weichselbaum RR, Chen CT. Accurate three-dimensional registration of CT, PET, and/or MR images of the brain. *J Comput Assist Tomogr* 1989;13:20-26.
7. Levin DN, Pelizzari CA, Chen GT, Chen CT, Cooper MD. Retrospective geometric correlation of MR, CT, and PET images. *Radiology* 1988;169:817-823.

8. Holman BL, Zimmerman RE, Johnson KA, et al. Computer-assisted superimposition of magnetic resonance and high-resolution technetium-99m-HMPAO and thallium-201 SPECT images of the brain. *J Nucl Med* 1991;32:1478-1484
9. Turkington TG, Jaszcak RJ, Pelizzari CA, et al. Accuracy of registration of PET, SPECT and MR images of a brain phantom. *J Nucl Med* 1993;34:1587-1594
10. Höhne KH, Hanson WA. Interactive 3D segmentation of MRI and CT volumes using morphological operations. *J Comput Assist Tomogr* 1992;16:285-294
11. Robb RA. *Three-dimensional Biomedical Imaging*. New York: VCH Publishers, Inc, 1995:165-206
12. Fox PT, Perlmutter JS, Raichle ME. A stereotactic method of anatomical localization for positron emission tomography. *J Comput Assist Tomogr* 1985;9:141-153
13. Fishman RA. Brain edema. *N Engl J Med* 1975;293:706-711
14. Purves MJ. *The Physiology of the Cerebral Circulation*. London: Cambridge University Press, 1972:69-96