



## Get Clarity On Generics

Cost-Effective CT & MRI Contrast Agents



FRESENIUS  
KABI

WATCH VIDEO

# AJNR

## **The effect of flow arrest on distal embolic events during arterial occlusion with detachable coils: a canine study.**

S R Hughes, V B Graves, P P Kesava and A H Rappe

*AJNR Am J Neuroradiol* 1996, 17 (4) 685-691

<http://www.ajnr.org/content/17/4/685>

This information is current as  
of August 14, 2025.

# The Effect of Flow Arrest on Distal Embolic Events during Arterial Occlusion with Detachable Coils: A Canine Study

Steven R. Hughes, Virgil B. Graves, Prabhakar P. Kesava, and Alan H. Rappe

**PURPOSE:** To determine the effect of proximal flow arrest on the frequency and timing of distal embolic events during occlusion of the common femoral artery with detachable coils. **METHODS:** Twenty-three complex fibered platinum coils were delivered into 10 common femoral arteries without proximal flow arrest. The arteries were continuously monitored for flow and embolic events by Doppler sonography during delivery and for at least 10 minutes after delivery of each coil. Thirty-four coils were delivered into 6 arteries after proximal flow arrest by inflation of a nondetachable balloon. After balloon deflation, each artery was monitored by Doppler sonography for 10 minutes. **RESULTS:** In the 10 arteries occluded without flow arrest, 87 events (8.7 per artery) occurred, of which 47 were embolic and 40 were indeterminate. In the 6 arteries with flow arrest, the number of emboli detected was 3 (0.5 per artery). Embolic events occurred only if there was residual flow. In those arteries that were occluded when the flow-arrest balloon was deflated, no emboli were detected. **CONCLUSIONS:** Proximal flow arrest virtually eliminates the risk of distal emboli during arterial occlusion with detachable fibered coils. The use of fibered coils, in conjunction with proximal flow arrest, allows for safe arterial occlusion when detachable balloons are not available or their use is not feasible.

**Index terms:** Animal studies; Arteries, therapeutic blockade; Interventional instruments, coils

*AJNR Am J Neuroradiol* 17:685–691, April 1996

Endovascular occlusion of the carotid artery is an accepted and effective form of treatment for various types of aneurysms and pseudoaneurysms and for some direct carotid-cavernous fistulas (1, 2). The most widely used device for carotid occlusion has been detachable balloons. Recently, though, availability of these balloons has been limited. Moreover, in some patients, the arterial anatomy precludes safe delivery of balloons to the internal carotid artery. Case reports have also described the successful use of detachable coils as occlusive devices in the carotid and vertebral arteries (3, 4). However, many physicians continue to question the safety of coil occlusion in the arteries to the central nervous sys-

tem. A primary concern is that the gradual occlusion of the artery by coils, as compared with the immediate occlusion attained with the use of a balloon, could result in a distal embolism.

The purpose of this study was to determine the effect of proximal flow arrest on the frequency and timing of distal embolic events during occlusion of the common femoral artery with detachable coils. The first part of the study consisted of coil occlusion of the artery without flow arrest. During the second part of the study, coil occlusion was performed with flow arrest that was achieved by inflation of a proximal nondetachable balloon. A transcranial Doppler probe was placed distal to the occlusion site to detect, record, and analyze embolic events. The sonographic characteristics of arterial emboli have been well studied and in vitro and in vivo, allowing some characterization of their type and size (5–9).

## Materials and Methods

### Subject Preparation

In compliance with guidelines established by the Research Animal Resources Center, beagle dogs weighing 15

---

Received June 21, 1995; accepted after revision October 19.

From the Department of Radiology, Memorial Medical Center, Springfield, Ill (S.R.H.), and the Department of Radiology, University of Wisconsin Medical School, Madison (V.B.G., P.P.K., A.H.R.).

Address reprint requests to Virgil B. Graves, MD, Department of Radiology, University of Wisconsin Medical School, 600 Highland Ave, Madison, WI 53792.

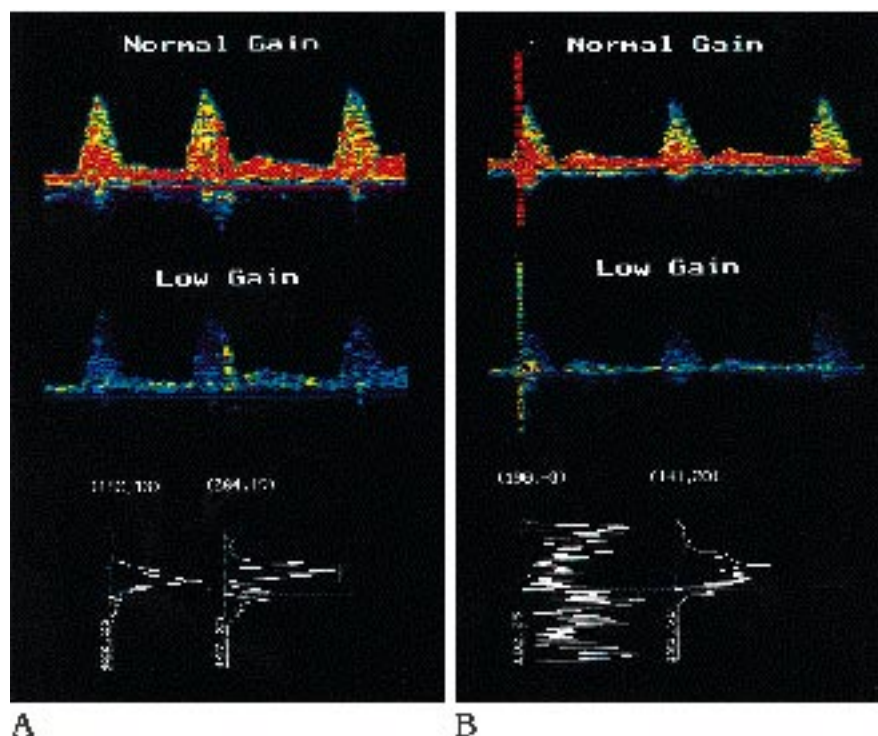
*AJNR* 17:685–691, Apr 1996 0195-6108/96/1704-0685

© American Society of Neuroradiology

Fig 1. Comparison of spectral display of an embolus and an indeterminate event at normal and low-gain settings.

A, The embolus is more evident at the low-gain setting. Two individual fast Fourier transforms (FFTs) are shown at the bottom along with their velocity and maximum amplitude, which are marked by the *plus sign*. The left FFT is the baseline and the right FFT is the embolus. The relative amplitude increase is the difference of the maximum amplitude at baseline and the maximum amplitude during the embolus, with amplitudes obtained at the same point in the cardiac cycle.

B, Spectral display of an indeterminate event.



kg were used in the study. Anesthesia was induced with intravenous administration of 5% pentothal solution at a dose of 1 mL per 2.25 kg of body weight and maintained with mechanical ventilation and inhalation of 1% halothane after endotracheal intubation. No heparin was administered during the study.

#### Sonographic Evaluation of Embolic Events

An 8-MHz EME TC 2000 pulsed-wave Doppler ultrasound probe (Nicolet, Madison, Wis) and an EMF flow probe (Carolina Medical, King, NC) were placed on the distal common femoral artery. The audio Doppler signal, spectral display, and flow velocities were continuously monitored with the two probes. The depth was 7 mm and the angle of insonation was 20° to 50°. The sample volume was 15 mm, the high-pass filter was 200 Hz, and the pulse repetition frequency was 12.05 kHz.

The Doppler signal, color-coded spectral display, and EMF velocity data were recorded by an IBM-compatible microcomputer for off-line analysis of the spectral display and individual time frames of the Fourier transforms. Using postprocessing software, we decreased the gain on the spectral displays until the base line arterial signal was 3 dB (dark blue). Embolic signals were more easily detected as short-duration events with amplitudes of at least 15 dB above baseline (red). Emboli thus detected were further analyzed by examination of their Fourier transform frames with respect to time of occurrence, duration, and maximum relative power amplitude (MRPA). Baseline relative power amplitude (BRPA) was determined by analyzing the Fourier transform frame from an adjacent cardiac cycle

without emboli at the same location in the cardiac cycle and at the same velocity as the MRPA. The relative amplitude increase (RAI) was determined by the equation  $RAI = MRPA - BRPA$ .

An event was classified as an embolus if it was unidirectional, of short duration, and of high amplitude ( $RAI > 14$  dB) (Fig 1A). An event was classified as indeterminate if it was bidirectional, of short duration, and of high amplitude ( $RAI > 14$  dB) (Fig 1B). Indeterminate events could represent mechanical artifacts or very reflective or large emboli that overloaded the electronic circuitry of the Doppler ultrasound probe.

The mean duration and mean RAI of these groups were statistically analyzed and  $\chi^2$  tests were performed to assess equality.

#### Arterial Preparation

The right common carotid artery was exposed and cannulated with a 6F sheath through which a 6F guiding catheter (10 arteries) or a 5F guiding catheter with a double lumen nondetachable balloon (6 arteries) was passed into the distal external iliac artery. A Tracker 18 catheter (Target Therapeutics, Fremont, Calif) was passed in a coaxial manner into the proximal common femoral artery (Fig 2).

#### Coil Delivery without Flow Arrest

A total of 23 complex fibered platinum coils (Target Therapeutics, Fremont, Calif) were delivered into 10 common femoral arteries without proximal flow arrest. In 7

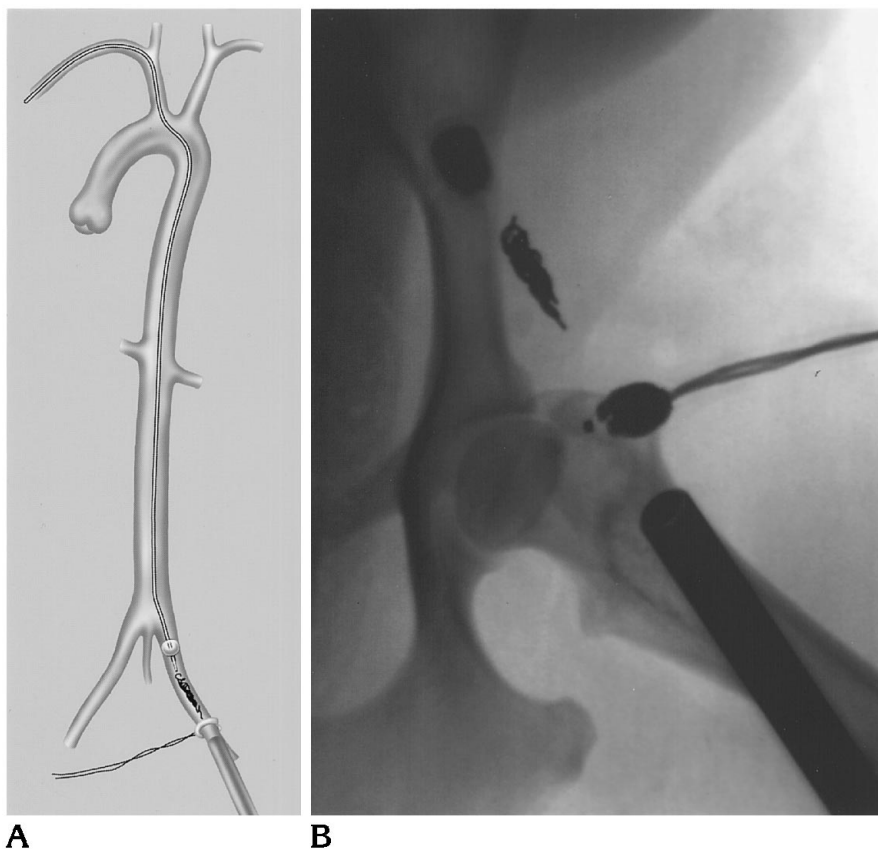


Fig 2. A, Schematic diagram shows the guiding catheter with occlusion balloon and coaxially delivered microcatheter, fiberoptic coils, EMF probe, and ultrasound probe.

B, Radiograph of iliac and femoral arteries after arterial occlusion distal to a flow-arresting balloon.

arteries, two  $3 \times 30$ -mm coils were delivered at 10-minute intervals. In 3 arteries, three  $3 \times 30$ -mm coils were delivered. The arteries were continuously monitored sonographically for flow and embolic events during delivery and for at least 10 minutes after delivery of each coil.

#### *Coil Delivery with Flow Arrest*

A total of 34 complex fiberoptic platinum coils were delivered into 6 common femoral arteries after proximal flow arrest was accomplished by inflation of a nondetachable 5F double lumen balloon (Medi-tech Inc, Watertown, Mass).

In one artery, two  $3 \times 30$ -mm coils were delivered and 10 minutes later the balloon was deflated, with persistent flow evident. The balloon was then reinflated and two  $2 \times 20$ -mm coils were delivered. Fifteen minutes later, the balloon was deflated, without evidence of flow. There was no sign of emboli after 10 minutes of sonographic monitoring following deflation.

In the remaining five arteries, sequential delivery of one  $3 \times 30$ -mm, one  $2 \times 20$ -mm, one  $3 \times 30$ -mm, and three  $2 \times 20$ -mm coils was followed by 15 minutes of monitoring and then by deflation of the balloon. After balloon deflation, each artery was monitored sonographically for 10 minutes.

## Results

### *Events in Arteries Occluded without Flow Arrest*

In the 10 arteries occluded without flow arrest, 87 events occurred, of which 47 were embolic and 40 were indeterminate (Table 1). Because the mean RAI and duration of embolic and indeterminate events were statistically equivalent, no subgroup of indeterminate events could be considered more likely to represent an embolus or artifact.

Twenty-three events (6 embolic, and 17 indeterminate) occurred as a coil was delivered. There was no continuous shower of emboli and no event occurred later than 334 seconds (5 minutes 34 seconds) after delivery of a coil. Delivery of 14 (61%) of the 23 coils resulted in 1 to 7 events, for a total of 47 (54%) of the 87 events.

Thirty-four events occurred with delivery of 2 (9%) of the 23 coils. Thus, 26% of the 87 events were related to just 2 coils. Five (22%) of the 23 coils were delivered without any event. Two of these were in one artery (artery 4), which had

**TABLE 1: Number of embolic and indeterminate events occurring during and after delivery of coils during arterial occlusion without flow arrest**

Artery	No. of Coils	No. of Events per Coil						Total No. of Events	Flow or Occlusion
		Coil 1		Coil 2		Coil 3			
		E	I	E	I	E	I		
1	2	2	4	1	0	...		7	O
2	2	3	2	1	1	...		7	O
3	2	0	3	1	0	...		4	O
4	2	0	0	0	0	...		0	F
5	3	0	1	15	0	4	1	21	O
6	2	2	3	1	3	...		9	O
7	3	3	0	0	4	0	1	8	O
8	2	1	5	11	8	...		25	O
9	3	2	3	0	0	0	0	5	O
10	2	0	0	0	1	...		1	O

Note.—E indicates embolic; I, indeterminate; O, occluded, and F, persistent flow.

**TABLE 2: Number of embolic and indeterminate events occurring during and after delivery of coils during arterial occlusion with flow arrest**

Artery	No. of Coils	No. of Events		Flow or Occlusion
		E	I	
1*	4	1	0	F
2	6	0	0	F
3*	6	2	0	F
4	6	0	0	O
5	6	0	0	O
6	6	0	0	O

Note.—E indicates embolic; I, indeterminate; O, occluded; and F, persistent flow.

\* With artery 1, two coils were initially placed, with persistent flow at balloon deflation. The balloon was reinflated and two more coils were placed, with resultant occlusion. With artery 3, the two emboli occurred with the first deflation of the balloon.

persistent flow. This artery was monitored for 14 minutes after delivery of the second coil.

#### *Events in Arteries Occluded with Flow Arrest*

In the first artery (artery 1) occluded with flow arrest, two coils were placed and 10 minutes later the balloon was deflated, resulting in considerable residual arterial flow. One embolus occurred 8 seconds after the deflation. The balloon was reinflated and two more coils were delivered (Table 2). No emboli were detected as the balloon was reinflated. The artery was monitored for 15 minutes and the balloon was once again deflated, with resultant occlusion of the artery. There was no evidence of emboli after 10 minutes of monitoring following deflation.

Six coils were delivered in each of the next

five arteries, and after 15 minutes, the balloon was deflated. Two arteries had initial minor residual systolic flow, but both occluded spontaneously within 60 seconds. In one of the arteries, two emboli were detected 5 and 10 seconds, respectively, after balloon deflation. No events occurred in the other artery. In the final three arteries, no detectable arterial flow was present when the occlusion balloon was deflated, and no embolic or indeterminate events occurred.

No embolic or indeterminate events occurred in an artery occluded by means of flow arrest if the artery was occluded at the time of balloon deflation. One of the three arteries with residual flow went on to occlude even though no detectable event occurred.

The mean duration and mean RAI of the three emboli that did occur after deflation of the occlusion balloon were statistically equal to the mean duration and mean RAI of the events occurring in the arteries occluded without flow arrest.

## **Discussion**

### *Balloon Occlusion of Carotid or Vertebral Arteries*

The more common indications for carotid and vertebral artery occlusion in our practice and in the literature include treatment of aneurysms or pseudoaneurysms that carry an unacceptably high surgical risk; preoperative arterial occlusion before head and neck surgery, in which surgical management of the artery would be problematic; treatment of carotid cavernous

fistulas not amenable to other endovascular therapies; and arterial injury (1–4). Such vascular occlusion is usually accomplished by the use of detachable balloons (3, 4, 10).

Because of their ability to close large vessels abruptly at a precise site, detachable balloons are believed to be the device of choice in treating traumatic or congenital single-hole fistulas and in occluding large vessels (10). The primary disadvantages of balloons include deflation, distal migration, and the relatively large guiding catheter needed to deliver the balloon (which in some cases of tortuous or diseased vessels precludes delivery).

Furthermore, before occlusion of a carotid or vertebral artery, a test balloon occlusion is performed, which stagnates the column of arterial blood proximal to the balloon for 20 to 120 minutes. Then, before the detachable balloon can be placed, the test balloon must be deflated and removed. These maneuvers present at least a theoretical risk of distal embolization of any thrombus that may form during the test occlusion.

A recent review of 500 test occlusions reported at least one asymptomatic embolus after test occlusion and, although the majority of symptomatic complications occurred during the occlusion, there were rare neurologic events noted after the test occlusion was terminated (11). These may have been due to embolization of thrombus formed during the test occlusion and released when flow was reestablished after balloon deflation.

#### *Coil Occlusion of Carotid or Vertebral Arteries*

Coils have also been used to occlude the carotid and vertebral arteries. However, in the two cases reported by Braun et al (3), coils were not the device of choice. In one case, balloons were used initially. Coils were used only after balloon deflation and migration were documented, and the authors reported no complications with the use of the coils. Bergsjordet et al (4) reported on coil occlusion of a vertebral artery to control bleeding from a posttraumatic pseudoaneurysm, also without complication. The authors of both these case reports, though, expressed concern about the risk of distal embolization during arterial occlusion.

Despite these isolated case reports, no detailed investigation has been undertaken on the use of coils as an occlusive device in the arteries

to the central nervous system. Because coils can be delivered through the same 5F balloon catheter used for test occlusion, they offer potential advantages over detachable balloons in very tortuous vessels, in which the larger guiding catheter required to deliver the detachable balloon might preclude safe arterial access.

#### *Use of Doppler Sonography to Detect Emboli*

In vitro and in vivo studies have demonstrated that Doppler sonography has a very high sensitivity for detection of emboli (12–17). There is general agreement that amplitude increases with size (6, 7, 10). Intensity depends on emboli velocity, with perhaps as much as 20% variance in intensity associated with velocity (6). An inverse relationship exists between embolic velocity and duration, accounting for 10% to 60% of duration variance (9).

A complex association exists between embolic composition, angle of insonation, profile of the ultrasound beam, and duration, as described by Droste et al (6). In light of the intricate relationship between the physical properties of emboli and the ultrasound beam, it is not surprising that precise emboli characterization based on amplitude and duration of the Doppler signal has not been possible in in vitro or in vivo models. Thus, in this study, the exact nature of any given emboli is not known. However, Doppler sonography is very sensitive in detecting all events.

#### *Embolic versus Indeterminate Events*

Indeterminate events may arise from a variety of mechanical interactions with the arterial wall related to the coil or the catheter within the artery. Alternatively, they may relate to saturation of the video amplifiers of the transcranial Doppler monitor caused by the high reflectivity or large size of an embolus. The percentage of reflectance of an ultrasound beam depends on the acoustic impedance of an object and its background, which in turn depend on density (see the Appendix).

The mean RAI for emboli has been shown to be greater than that for artifacts, but the difference was not great enough to differentiate the two (8).

In this study, 34 coils were delivered in arteries occluded by flow arrest, each with the potential to disturb the arterial wall mechanically.

However, no indeterminate events occurred. Thus, it seems likely that the indeterminate events detected in this investigation represent emboli. Seventeen of the 40 indeterminate events that occurred without flow arrest had durations less than 0.025 seconds, indicating a small size. These most likely represented an air embolus introduced with the coil, since a small embolus must be highly reflective to overload the video circuitry.

#### *Comparison of Events without and with Flow Arrest*

Without proximal flow arrest, the number of embolic and indeterminate events that occurred during arterial occlusion with fibered coils averaged 8.7 per artery. These occurred most often at the time of coil delivery and decreased in number with time. No events occurred later than 334 seconds (5 minutes 34 seconds) after coil delivery. Although relatively small in number, these events could represent a significant embolic burden, particularly in arteries that have a high propensity for emboli. In a worst-case scenario, even one embolus could have serious consequences.

Arterial occlusion performed distal to a flow-arresting balloon dramatically decreased the average number of emboli per occluded artery. With proximal flow arrest, the number of emboli occurring during arterial occlusion with fibered coils averaged 0.5 per artery. No emboli occurred before or more than 10 seconds after balloon deflation. Embolic events occurred only if there was residual flow. In those arteries that were occluded when the flow-arrest balloon was deflated, no emboli were detected.

#### *Conclusions*

The results of this study show that proximal flow arrest virtually eliminates the risk of distal emboli during arterial occlusion with detachable fibered coils. Clinically, an attempt should be made to pack the artery tightly so that no residual flow is present when the flow-arrest balloon is deflated. Flow arrest facilitates precise coil delivery. In addition, the coil can be delivered coaxially through the nondetachable test occlusion balloon without deflating the balloon (which may be adjacent to a column of blood that has been static for 20 to 120 minutes). The use of fibered coils, in conjunction with proximal

flow arrest, allows for safe arterial occlusion when detachable balloons are not available or their use is not feasible. Although the precise composition of detected emboli is not possible, Doppler sonography can be used in vivo to quantify embolic events during endovascular procedures.

#### **Appendix**

The equation for determining the percentage of reflectance of an ultrasound beam is

$$R = (Z_2 - Z_1 / Z_2 + Z_1) \times 100 ,$$

where R represents percentage of reflectance, Z<sub>1</sub> represents the acoustic impedance of an embolus, and Z<sub>2</sub> represents the acoustic impedance of the background.

The equation for calculating acoustic impedance is  $Z = DV$ , where Z represents acoustic impedance, D represents density, and V represents velocity of sound.

#### **References**

1. Larson JL, Tew JM, Tomsick TA, van Loveren HR. Treatment of aneurysms of the internal carotid artery by intravascular balloon occlusion: long-term follow-up of 58 patients. *Neurosurgery* 1995; 36:23-30
2. Lewis AI, Tomsick TA, Tew JM. Management of 100 consecutive direct carotid-cavernous fistulas: results of treatment with detachable balloons. *Neurosurgery* 1995;36:239-244
3. Braun IF, Hoffman JC, Casarella WJ, Davis PC. Use of coils for transcatheter carotid occlusion. *AJNR Am J Neuroradiol* 1985;6: 953-956
4. Bergsjordet B, Strother CM, Crummy AB, Levin AB. Vertebral artery embolization for control of massive hemorrhage. *AJNR Am J Neuroradiol* 1984;5:201-203
5. Bunegin L, Wahl D, Albin MS. Detection and volume estimation of embolic air in the middle cerebral artery using transcranial Doppler sonography. *Stroke* 1994;25:593-600
6. Droste DW, Markus HS, Nassiri D, Brown MM. The effect of velocity on the appearance of embolic signals in transcranial Doppler models. *Stroke* 1994;25:986-991
7. Markus HS, Brown MM. Differentiation between different pathological cerebral embolic materials using transcranial Doppler in an in vitro model. *Stroke* 1993;24:1-5
8. Markus HS, Loh A, Brown MM. Computerized detection of cerebral emboli and discrimination from artifact using Doppler ultrasound. *Stroke* 1993;24:1667-1672
9. Russell D, Madden KP, Clark WM, Sandset PM, Zivin JA. Detection of arterial emboli using Doppler ultrasound in rabbits. *Stroke* 1991;22:253-258
10. Lasjaunias P, Berenstein A. Technical aspects of surgical neuroangiography. In: Lasjaunias P, Berenstein A, eds. *Surgical Neuroangiography*. Berlin, Germany: Springer-Verlag; 1987:13-14
11. Mathis JM, Barr JD, Jungreis CA, et al. Temporary balloon test occlusion of the internal carotid artery: experience in 500 cases. *AJNR Am J Neuroradiol* 1995;16:749-754
12. Spencer MP, Thomas GI, Nicholls SC, Sauvage LR. Detection of middle cerebral artery emboli during carotid endarterectomy using transcranial Doppler ultrasonography. *Stroke* 1990;21:415-423

13. Dagirmanjian A, Davis DA, Rothfus WE, Deeb ZL, Goldberg AL. Silent cerebral microemboli occurring during carotid angiography: frequency as determined with Doppler sonography. *AJR Am J Roentgenol* 1993;161:1037-1040
14. Ginsberg LE, Stump DA, King JC, Deal DD, Moody DM. Air embolus risk with glass versus plastic syringes: in vitro study and implications for neuroangiography. *Radiology* 1994;191:813-816
15. Grosset DG, Georgiadis D, Abdullah I, Bone I, Lees KR. Doppler emboli signals vary according to stroke subtype. *Stroke* 1994;25:382-384
16. Grosset DG, Georgiadis D, Kelman AW, Lees KR. Quantification of ultrasound emboli signals in patients with cardiac and carotid disease. *Stroke* 1993;24:1922-1924
17. Georgiadis D, Grosset DG, Lees KR. Transhemispheric passage of microemboli in patients with unilateral internal carotid artery occlusion. *Stroke* 1993;24:1664-1666