



Get Clarity On Generics

Cost-Effective CT & MRI Contrast Agents



FRESENIUS
KABI

WATCH VIDEO

AJNR

The usefulness of MR in establishing the diagnosis of parotid pleomorphic adenoma.

K Ikeda, T Katoh, S K Ha-Kawa, H Iwai, T Yamashita and Y Tanaka

AJNR Am J Neuroradiol 1996, 17 (3) 555-559

<http://www.ajnr.org/content/17/3/555>

This information is current as
of August 21, 2025.

The Usefulness of MR in Establishing the Diagnosis of Parotid Pleomorphic Adenoma

Koshi Ikeda, Tsutomu Katoh, Sang Kil Ha-Kawa, Hiroshi Iwai, Toshio Yamashita, and Yoshimasa Tanaka

PURPOSE: To assess the usefulness of MR findings in establishing a specific diagnosis of parotid pleomorphic adenoma. **METHODS:** T1-weighted and T2-weighted MR images with and without contrast enhancement were obtained in 82 patients with parotid tumors. Imaging findings in the 38 patients in whom surgery subsequently revealed pleomorphic adenomas were compared with findings in the 44 patients who had other types of tumor. Specifically, the homogeneity, signal intensity, contrast enhancement, capsule thickness, lobulation, adenopathy, and infiltration of adjacent fat were compared among the different types of tumor. The sensitivity, specificity, positive predictive value, and negative predictive value were calculated. **RESULTS:** A low-signal capsule on T2-weighted images and a lobulated contour characterized most pleomorphic adenomas. The sensitivity of the first finding for pleomorphic adenoma was 82%; specificity, 85%; positive predictive value, 82%; and negative predictive value, 84%. For the second finding, the sensitivity was 53%; specificity, 84%; positive predictive value, 74%; and negative predictive value, 67%. **CONCLUSION:** None of the signs evaluated had perfect sensitivity and specificity. The MR findings of a complete capsule, lobulated contour, or high T2 signal intensity have a high predictive value for the diagnosis of pleomorphic adenoma.

Index terms: Adenoma; Salivary glands, magnetic resonance; Salivary glands, neoplasms

AJNR Am J Neuroradiol 17:555-559, March 1996

Benign pleomorphic adenomas, the most common tumor of the parotid gland, must be differentiated from malignant parotid lesions. Parotid pleomorphic adenomas can be cured by surgery if the capsule is completely removed. Biopsy without resection may increase the risk of recurrence. Therefore, preoperative diagnosis is important for obtaining optimal results from surgery (1-6). Pleomorphic adenomas have been described as generally showing increased signal intensity and well-defined margins on T2-weighted magnetic resonance (MR) images (7-10). The purpose of this study was to determine the sensitivity, specificity, and predictive value of the MR features of parotid gland tumors for the diagnosis of pleomorphic adenoma.

Materials and Methods

The study group consisted of 82 patients examined between January 1990 and August 1993 for a suspected solitary parotid gland tumor at a referral center for head and neck tumors. Patients with recurrent tumors were excluded from the study. Among the 82 patients, 38 had pleomorphic adenomas, which were diagnosed at histologic examination; the remaining patients had Warthin tumor (16 cases) or other benign or malignant tumors (Table 1). The MR images in each case were reviewed retrospectively without knowledge of the histologic diagnosis. MR images were acquired on a 1.5-T scanner with a quadrature head coil. Acquisitions in each case included a T1-weighted sequence in the axial plane (500/15-20/2 [repetition time/echo time/excitations]), 3- or 5-mm thick sections, and 256 × 256 matrix; plus a T2-weighted sequence with parameters of 2000/80/1, 5-mm-thick sections, and 256 × 256 matrix (Figs 1-4). Flow-compensation techniques were used. Supplementary images in the coronal plane were acquired in some cases. Additional T1-weighted MR images were acquired in 23 cases after intravenous injection of gadopentetate dimeglumine (0.1 mmol/kg). These cases included 8 pleomorphic adenomas, 5 benign parotid tumors, and 10 malignant tumors.

In each study, eight MR features were evaluated and dichotomized. The capsule was classified as complete or incomplete, as lobulated or not lobulated, as well defined

Received March 21, 1995; accepted after revision August 15.

From the Departments of Radiology (K.I., T.K., S.K.H.-K., Y.T.) and Otolaryngology (H.I., T.Y.), Kansai Medical University, 1, Fumizonochi, Moriguchi, Osaka, 570 Japan.

Address reprint requests to Koshi Ikeda, MD.

AJNR 17:555-559, Mar 1996 0195-6108/96/1703-0555

© American Society of Neuroradiology

TABLE 1: Histologic diagnosis in 82 parotid tumors

Histologic Findings	No. of Patients
Benign tumors	
Pleomorphic adenoma	38
Warthin tumor	16
Lymphoepithelial cyst	5
Lipoma	2
Hemangioma	1
Lymphangioma	1
Malignant tumors	
Malignant lymphoma	4
Squamous cell carcinoma	3
Carcinoma ex pleomorphic adenoma	3
Adenoid cystic carcinoma	2
Adenocarcinoma	2
Acinic cell tumor	2
Mucoepidermoid tumor	1
Mucin-producing adenocarcinoma	1
Metastasis	1
Total	82

or not well defined. The signal intensity within the tumor was classified as homogeneous or inhomogeneous on the basis of findings on T2-weighted images. The tumor was classified as being of high signal intensity on T2-weighted images if it had a signal intensity greater than fat and as being of low signal intensity on T1-weighted images if it had a signal intensity equal to or lower than muscle. The appearance of lymph nodes adjacent to the parotid gland was noted. Adenopathy was classified as present or absent on the basis of conventional criteria for abnormal lymph nodes (11, 12). The fat adjacent to the parotid gland was evaluated as being infiltrated or not infiltrated.

The frequency of each finding was calculated for the group with pleomorphic adenoma and for the group that included all other tumor types. The frequencies of findings

were also calculated for the group that included all benign lesions and for the group that included all malignant tumors. The sensitivity of each finding was calculated as the proportion of cases of pleomorphic adenoma that had the sign (true positive) relative to all cases of pleomorphic adenoma. The specificity was calculated as the proportion of tumors that were not pleomorphic adenomas that lacked the sign. The predictive value of each sign was calculated as the proportion of pleomorphic adenomas among all tumors that had the sign; the negative predictive value was calculated as the proportion of cases that were not pleomorphic adenomas among all cases that lacked the sign.

Results

The tabulations of sensitivity and specificity and positive and negative predictive values for each of the signs evaluated are listed in Tables 2 and 3. In Table 2, pleomorphic adenomas are compared with other tumor types; in Table 3, benign and malignant tumors of the parotid gland are compared.

A complete capsule surrounding the tumor characterized 31 of 38 pleomorphic adenomas and 7 of 44 of the other tumors. Most of the malignant tumors lacked a complete capsule. The sensitivity of the complete capsule sign for pleomorphic adenomas was 82% and the sensitivity of this sign for benign tumors was 59%. The specificity of the sign was 85% relative to other parotid tumors and 95% in differentiating malignant from nonmalignant parotid tumors. The predictive value of a complete capsule for a

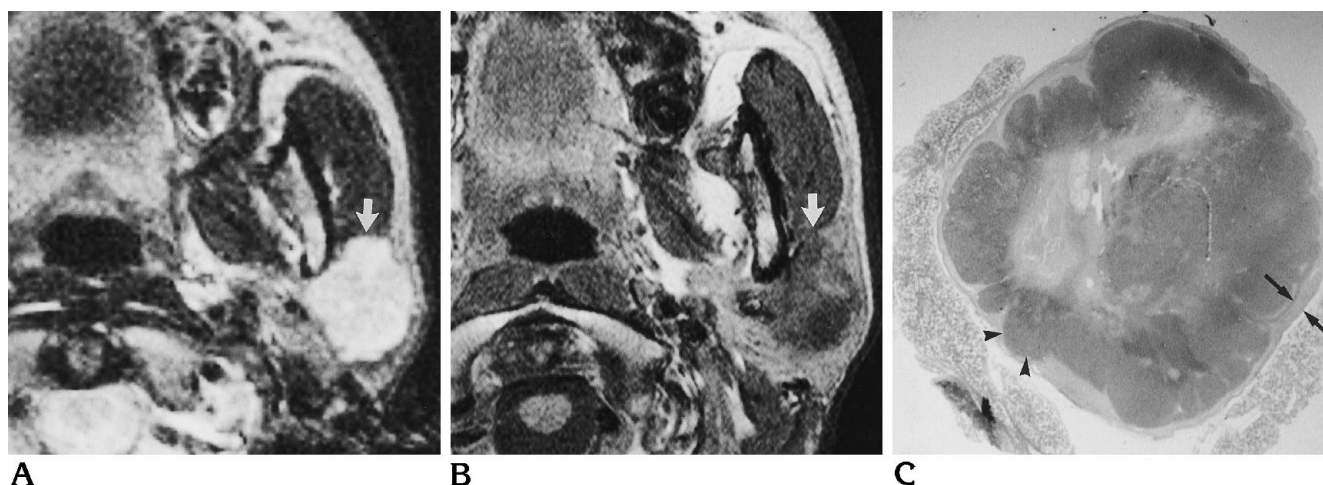


Fig 1. Pleomorphic adenoma in the superficial lobe of the left parotid gland.

A and B, Axial T2-weighted (2000/80) (A) and T1-weighted (500/15) (B) MR images show that the tumor has a thick capsule and well-defined margins with a lobulated contour on the T2-weighted image (*arrow*). The lobules are several millimeters in size.

C, Macroscopic examination shows the tumor surrounded by a thick, fibrous capsule (*arrows*) and polypoid protrusions (*arrowheads*). The margins between the tumor and the adjacent parotid tissues are clearly defined (hematoxylin-eosin stain).

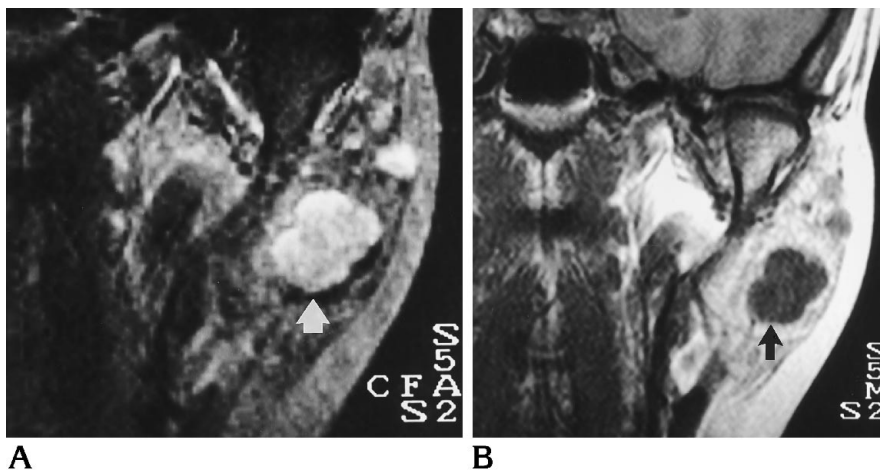


Fig 2. Pleomorphic adenoma in the superficial lobe of the left parotid gland. Coronal T2-weighted (2000/80) (A) and T1-weighted (500/20) (B) MR images show that the tumor has well-defined margins (arrows) and a lobulated contour. The lobules are about 1 cm in size.

benign pleomorphic adenoma was 82%. The predictive value of this sign of a benign tumor was 97%. When the sign was absent, the predictive value that the tumor was not a pleomorphic adenoma or not a benign tumor was 84% or 41%, respectively. The capsule was better defined on the enhanced than on the unenhanced T1-weighted images in 11 of 23 cases. In 10 of the 11 cases, the tumor was classified pathologically as a pleomorphic adenoma (5 cases) or as another type of benign tumor (5 cases).

Lobulation of the contour was seen in 20 of the 38 pleomorphic adenomas. The sensitivity of this sign for pleomorphic adenomas was 53%, its sensitivity for benign tumors of the parotid gland was 38%. Absence of lobulation was more common in malignant tumors and tumors of other nosologic categories than in pleomor-

phic adenomas. The specificity of the sign was 84% relative to nonpleomorphic adenoma tumors and 84% relative to malignant tumors, respectively. The predictive value of the presence of a lobulated contour for a pleomorphic adenoma or a benign parotid tumor was 74% or 89%, respectively. The predictive value of the absence of lobulation that the tumor was not pleomorphic adenoma or not benign was 67% or 29%, respectively.

The combination of a complete capsule and a lobulated contour was found only in pleomorphic adenomas. Other than pleomorphic adenomas, some benign (two lipomas, one hemangioma, and one lymphangioma) and some malignant tumors (three carcinoma ex pleomorphic adenomas) showed lobulation. Other benign tumors (three lymphoepithelial cysts

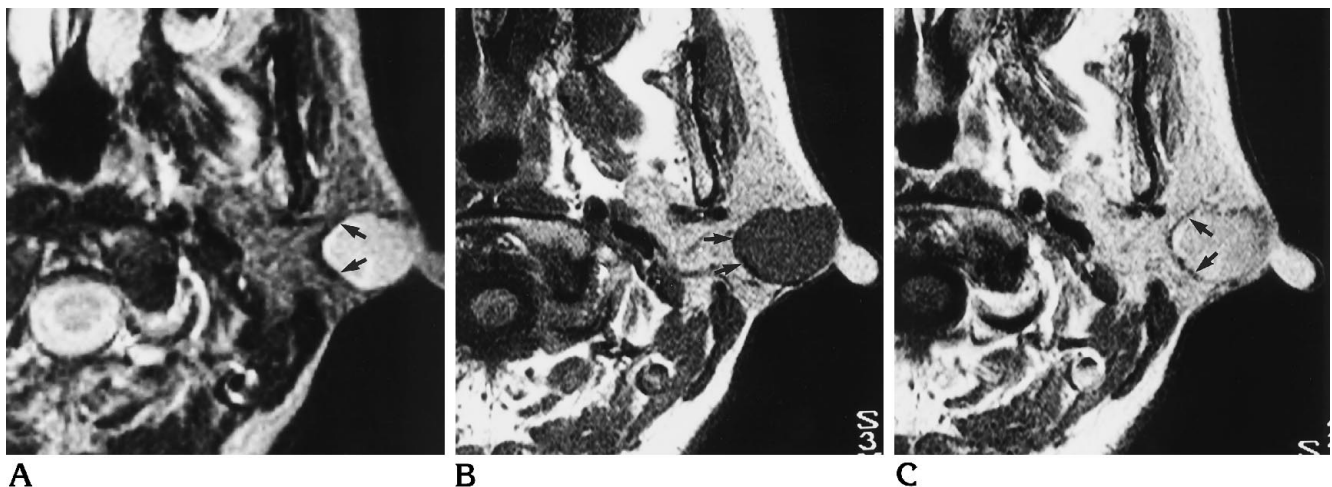


Fig 3. Pleomorphic adenoma in the superficial lobe of the left parotid gland. Axial T2-weighted (2000/80) (A), unenhanced T1-weighted (500/20) (B), and contrast-enhanced T1-weighted (500/20) (C) MR images show the tumor is surrounded by a capsule of low signal intensity (arrows) and has a lobulated contour on the T2-weighted image. The capsule is well seen on the contrast-enhanced image.

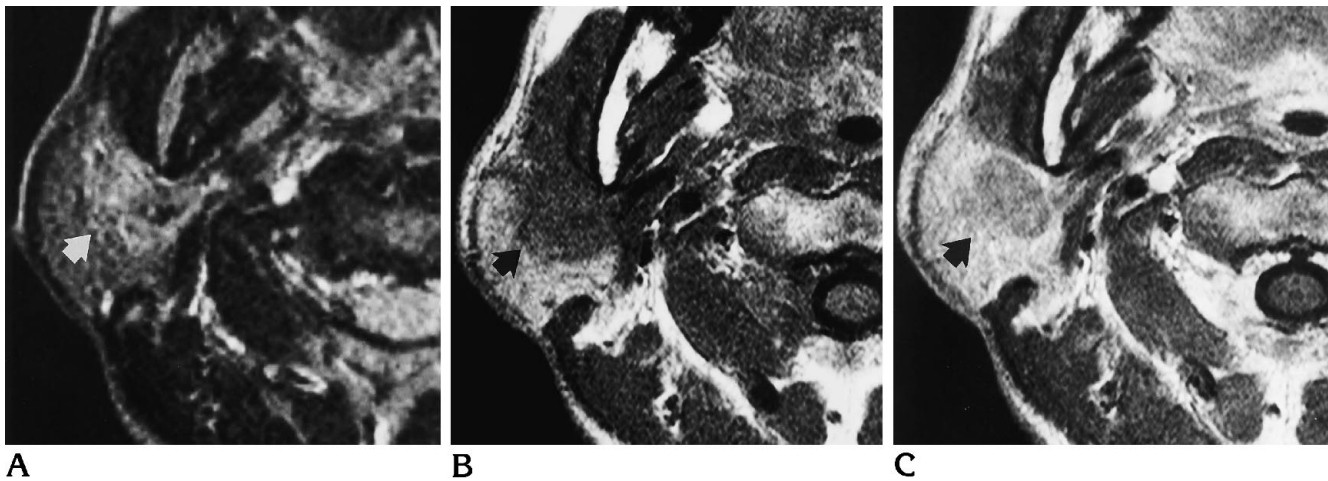


Fig 4. Adenocarcinoma in the deep lobe of the right parotid gland. Axial T2-weighted (2000/80) (A), unenhanced T1-weighted (500/20) (B), and contrast-enhanced T1-weighted (500/20) (C) MR images. The tumor has a poorly defined margin on the unenhanced T1-weighted image (arrow), and enhances less well than adjacent parotid tissue. The capsule is not seen on the contrast-enhanced image (arrow).

and three Warthin tumors) and one malignant tumor (one acinic cell tumor) had a complete capsule. The sensitivity of the combination of these signs for pleomorphic adenomas was 45%. The sign had high specificity in the differentiation of benign and malignant parotid tumors. It was also not very sensitive for benign parotid tumors. When the sign was present, it had a high predictive value (100%) for pleomorphic adenoma or benign tumors; when absent, it had a low predictive value.

Well-defined margins were present in most pleomorphic adenomas. The sensitivity of the sign for pleomorphic adenomas or benign tumors was 100%. The specificity, however, was low (18% for nonpleomorphic adenomas and

42% for malignant tumors). The predictive value that the tumor was malignant when the sign was lacking was 100%.

The sensitivity, specificity, positive predictive value, and negative predictive value for the homogeneity of the lesion, signal intensity on T2-weighted images, signal intensity on T1-weighted images, adenopathy, and irregularity of fat are given in Tables 2 and 3. All pleomorphic adenomas had a signal intensity equal to or higher than fatty tissue on T2-weighted images and most (95%) had a signal intensity equal to or lower than muscle on T1-weighted images. Pleomorphic adenomas were inhomogeneous in 31 of 38 cases. None of the pleomorphic adenomas had infiltration of the surrounding

TABLE 2: MR imaging signs in pleomorphic adenoma and other parotid tumors

	Sensitivity, %	Specificity, %	Positive Predictive Value, %	Negative Predictive Value, %
Complete capsule	82	85	82	84
Lobulated contour	53	84	74	67
Complete capsule and lobulated contour	45	100	100	68
Well-defined margins	100	18	51	100
Inhomogeneous	82	41	54	72
High signal, T2	100	66	72	100
Low signal, T1	95	20	51	82
No lymphadenopathy	100	16	51	100
No irregularity of fat	100	16	51	100

TABLE 3: MR imaging signs in benign and malignant parotid tumors

	Sensitivity, %	Specificity, %	Positive Predictive Value, %	Negative Predictive Value, %
Complete capsule	59	95	97	41
Lobulated contour	38	84	89	29
Complete capsule and lobulated contour	27	100	100	29
Well-defined margins	100	42	85	100
Inhomogeneous	67	21	74	16
High signal, T2	78	79	93	52
Low signal, T1	84	6	75	9
No lymphadenopathy	100	37	84	100
No irregularity of fat	100	37	84	100

subcutaneous tissue or evidence of lymphadenopathy on MR images. Lymphadenopathy and infiltration of fat were good predictors (100%) that a malignant tumor, not a benign tumor, was present. The lack of these signs had a poor predictive value.

Discussion

Pleomorphic adenomas account for approximately half the tumors found in the parotid gland. They are typically found in women ages 30 to 70 years (1–3). Typically, pleomorphic adenomas have high signal intensity on T2-weighted images, inhomogeneity, and sharp demarcation from the adjacent parotid gland (7–10). Other tumors of the parotid gland, such as Warthin tumor, lymphoepithelial cyst, and possibly other benign and malignant tumors, may show the same features (13–15). Parotid pleomorphic adenomas have also been reported to show lobulated contours caused by the differential growth rates of different cell types within the tumors (4, 16). This aspect of pleomorphic adenomas has not been emphasized.

Our study suggests that no one MR finding distinguished pleomorphic adenomas from other parotid gland tumors. None of the signs evaluated had perfect sensitivity and specificity. However, tumors that had a complete capsule, lobulation, and high signal on T2-weighted images were most likely pleomorphic adenomas. Only benign tumors had both lobulation of the contour and a complete capsule. Well-defined margins were also a good predictor of a benign tumor. Tumor margins and capsule are better defined on T2-weighted than T1-weighted images. Because contrast enhancement improves the demonstration of the capsule on T1-weighted images, intravenous contrast medium may be useful, especially in cases with clinical signs and symptoms of malignancy (pain or facial nerve paralysis).

This study was based on a select group of patients referred to a specialty hospital. A further statistical analysis was not attempted because of the size of the series. The conclusions probably do not apply to patients who have had surgery. Contrast enhancement was not administered in each case, but it appeared to improve the evaluation of the capsule in our study, as in other studies (17).

The study suggests that no one sign accurately differentiates pleomorphic adenoma from other parotid gland tumors. The combination of a complete capsule and lobulated contour has a high predictive value for a pleomorphic adenoma or benign tumor.

Acknowledgment

We thank Dr Victor M. Haughton for his advice during the preparation of this manuscript.

References

1. Batsakis JG. *Tumors of the head and neck: clinical and pathological considerations*. 2nd ed. Baltimore: Williams & Wilkins, 1979; 21–30
2. Skolnik EM, Friedman M, Becker S, Sisson GA, Keyes GR. Tumors of the major salivary glands. *Laryngoscope* 1977;87:843–861
3. Woods JE, Weiland LH, Chong GC, Irons GB. Pathology and surgery of primary tumors of the parotid. *Surg Clin N Am* 1977; 57:565–573
4. Murakami Y. Benign salivary gland tumors: recent clinical aspects of pleomorphic adenomas (in Japanese). *Johns* 1986;2: 391–401
5. Patey DH. Tumors and other diseases of the salivary glands in relation to general physiology and pathology. *J Laryngol Otol* 1968;82:853–866
6. Woods JE, Chong GC, Beahrs OH. Experience with 1360 primary parotid tumors. *Am J Surg* 1975;130:460–462
7. Som PM, Biller HF. High grade malignancies of parotid gland: identification with MR imaging. *Radiology* 1989;173:823–826
8. Swartz JD, Rothman MI, Marlowe FI, Berger AS. MR imaging of parotid mass lesions: attempts at histopathologic differentiation. *J Comput Assist Tomogr* 1989;13:789–796
9. Freling NJM, Molenaar WM, Vermey A, et al. Malignant parotid tumors: clinical use of MR imaging and histological correlation. *Radiology* 1992;185:691–696
10. Schalakman BN, Yousem DM. MR of intraparotid masses. *AJNR Am J Neuroradiol* 1993;14:1173–1180
11. Stevens MH, Harnsberger HR, Mancuso AA, Davis RK, Johnson LP, Parkin JL. Computed tomography of cervical lymph nodes: staging and management of head and neck cancer. *Arch Otolaryngol* 1985;111:735–739
12. Som PM. Lymph nodes of the neck. *Radiology* 1987;165:593–600
13. Minami M, Tanioka H, Oyama K, et al. Warthin tumor of the parotid gland: MR-pathologic correlation. *AJNR Am J Neuroradiol* 1993;14:209–214
14. Sigal R, Monnet O, de Baere T, et al. Adenoid cystic carcinoma of the head and neck: evaluation with MR imaging and clinical-pathologic correlation in 27 patients. *Radiology* 1992;184:95–101
15. Som PM, Shugar JMA, Sacher M, Stollman AL, Biller HF. Benign and malignant parotid pleomorphic adenomas: CT and MR studies. *J Comput Assist Tomogr* 1988;12:65–69
16. Wenig BM. Major and minor salivary glands. In: *Atlas of head and neck pathology*. Philadelphia: Saunders, 1993;269–337
17. Vogl TJ, Dresel SHJ, Späth M, et al. Parotid gland: plain and gadolinium-enhanced MR imaging. *Radiology* 1990;177:667–674