



Get Clarity On Generics

Cost-Effective CT & MRI Contrast Agents

**FRESENIUS
KABI**

[WATCH VIDEO](#)

AJNR

Three-dimensional CT angiography in the detection and characterization of intracranial berry aneurysms.

J K Hope, J L Wilson and F J Thomson

AJNR Am J Neuroradiol 1996, 17 (3) 439-445

<http://www.ajnr.org/content/17/3/439>

This information is current as
of August 15, 2025.

Three-dimensional CT Angiography in the Detection and Characterization of Intracranial Berry Aneurysms

J. K. A. Hope, J. L. Wilson, and F. J. Thomson

PURPOSE: To assess the accuracy of three-dimensional CT angiography (CTA) in the detection and characterization of intracranial aneurysms and to help determine its role as a screening test for aneurysms in the asymptomatic population and as an adjunct to angiography in subarachnoid hemorrhages and in the follow-up of untreated aneurysms. **METHODS:** In a blinded, prospective study, the 3-D CTA studies in 80 patients with symptomatic aneurysms were analyzed for the presence and morphology of aneurysms. Angiography or surgery acted as the control. **RESULTS:** Ninety-four aneurysms were found in 63 patients. Negative findings at angiography were noted in 17. Sensitivity and specificity of 3-D CTA for all aneurysms, all patients, and aneurysms 5 mm or smaller were 90.4% and 50%, 98.4% and 82.4%, and 78.8% and 51.9%, respectively. **CONCLUSION:** Three-dimensional CTA may have a role in noninvasive screening for asymptomatic aneurysms in the general population, but caution is advocated when data obtained from symptomatic patients are extrapolated to the asymptomatic population who harbor smaller aneurysms. Also, 3-D CTA may be useful as an adjunct to angiography in the characterization of berry aneurysms and in the follow-up of untreated aneurysms.

Index terms: Aneurysm, computed tomography; Aneurysm, intracranial; Computed tomography, three-dimensional

AJNR Am J Neuroradiol 17:439–445, March 1996

The high morbidity and mortality of subarachnoid hemorrhages (SAH) caused by rupture of berry aneurysms (1, 2) and the low surgical risk associated with elective clipping of these aneurysms (1, 3–5) make it desirable to have a screening test to identify berry aneurysms before they rupture in “at-risk” groups. At-risk groups include, among others, patients with adult polycystic kidney disease and family groups (6–8), as well as patients with a clinical suspicion for aneurysmal rupture but with negative computed tomography (CT) findings and negative results from cerebrospinal fluid sampling.

Catheter angiography is the most accurate means of identifying and excluding intracranial

berry aneurysms in these groups; however, it carries a small but defined morbidity that includes stroke (6, 9–11). This morbidity and the logistics associated with the performance of catheter angiography have led to the search for alternative techniques that include high-resolution CT with thin axial sections (12–14), magnetic resonance (MR) angiography (15), and three-dimensional CT angiography (CTA) (16).

The purpose of this study was to determine the accuracy of 3-D CTA as a screening method for the groups at risk. This accuracy was tested by using 3-D CTA studies performed as part of the routine workup of patients presenting to our institution with subarachnoid hemorrhages or other features suggesting a berry aneurysm. This is a valuable group to assess because the occurrence rate of aneurysms is high in this group and because all of these patients have undergone angiography or surgery, which can be used for correlation.

A second purpose of the study was to assess the role of 3-D CTA as an adjunct to angiogra-

Received April 28, 1995; accepted after revision September 21.

From the Department of Neuroradiology, Auckland (New Zealand) Hospital.

Address reprint requests to Dr J. K. A. Hope, Department of Neuroradiology, Auckland Hospital, Park Road, Auckland, New Zealand.

AJNR 17:439–445, Mar 1996 0195-6108/96/1703-0439

© American Society of Neuroradiology

phy in the investigation of berry aneurysms and to examine its role in the follow-up of incidental aneurysms.

Subjects and Methods

Image Generation

We used the Somatom DRH (Siemens AG, Erlangen) CT scanner and a fast-scan protocol (310 mAs, 125 kV, 7 section acquisitions per minute) to obtain sections of 25×2 mm with a 1-mm overlap beginning 40 seconds after the start of a continuous intravenous infusion of 120 mL of iohexol (1 mL/s). The scan plane was parallel to the roof of the sella turcica, with the lowest section 1 mm below the floor of the sella. Image reconstruction was delayed until acquisition was completed; then the first and last images were reconstructed and additional scans were obtained as necessary. The field of view was centered on the sella and was coned to exclude the skull vault and to include the circle of Willis and the principle branches out to the proximal A2, M2, and P2 segments. This imaging volume normally excludes the proximal vertebrobasilar arteries and the distal portions of the anterior and middle cerebral arteries. Reconstructed images were transferred via Ethernet to a workstation, where a trilinear interpolation algorithm produced an isotropic data set of 60 sections (voxel size, 0.4 mm linear). This procedure took 2.5 minutes.

By using this data set, we produced multiplanar reconstructions in the coronal, axial, and sagittal planes (30 seconds per plane). These reconstructions were viewed as a movie sequence (window, 200 Hounsfield units [HU]; center, 100 HU).

Three-dimensional CTA images were reconstructed at 6° increments by using the techniques of maximum-intensity projection (11 minutes) and surface-image reconstruction (8 minutes). The result was a movie sequence of 60 images per rotation about both horizontal and vertical axes. (A simple bone removal program was written to edit out unwanted bone detail from the CT image files before the reconstruction of the maximum-intensity projection images; this required another 4 minutes of reconstruction time.) The images obtained were then transferred to video tape and analyzed. The acronym 3-D CTA refers here to both maximum-intensity projection and surface-rendered 3-D reconstructions, as well as to the multiplanar reconstruction images.

Patient Selection

Subjects who came to our unit for investigation of a suspected berry aneurysm were eligible for inclusion in the study if they had undergone both catheter angiography and 3-D CTA during the same hospital stay and before surgery on any aneurysm that might have been discovered.

Catheter angiograms and 3-D CTA were obtained and interpreted prospectively and independently by two investigators; each investigator was blinded to the results of the

TABLE 1: Angiographic and surgical findings

Category	Number in study
Patients	80
Negative results on angiography	17
Patients with aneurysms	63
	41 with 1 aneurysm
	14 with 2 aneurysms
	7 with 3 aneurysms
	1 with 4 aneurysms
Total number of aneurysms	94

other arm of the study. Patients were excluded if blinding was compromised.

The following information was collected on each patient: age, sex, diagnosis, and time from presentation to 3-D CTA and catheter angiography. The 3-D CTA and catheter angiogram were examined separately in a blinded fashion for the presence and location of any aneurysm; if an aneurysm was found, its maximum lumen size, neck size, orientation, and vascular relationships were noted. Investigators also looked for mural calcification and intra-aneurysmal thrombus.

Results

From October 1992 through April 1994, 145 patients underwent catheter angiography as part of the investigation of a subarachnoid hemorrhage and/or a suspected intracranial berry aneurysm. Eighty-eight of these patients also underwent 3-D CTA (57 did not undergo this procedure because of restlessness or scheduling difficulties). Of the 88, 4 were subsequently excluded because of loss of blinding and another 4 were excluded because of movement degradation of the images. Thus, 80 patients were eligible for analysis (3-D CTA was performed within 48 hours of catheter angiography in 65 of the 80).

Of the 80 patients studied, 54 were women and 26 were men. Age was accurately documented in 74 of these 80 patients (mean age, 49.2 years; range, 23 to 75 years).

Ninety-four aneurysms were identified in 63 patients either at angiography or at surgery (Table 1). Of the 62 symptomatic aneurysms, 3-D CTA correctly identified 60 (96.8%). Of the 32 incidental aneurysms, 3-D CTA correctly identified 25 (78.1%). Three-dimensional CTA correctly predicted a negative result in 14 of the 17 patients with normal results on angiography. There were 9 false-negative 3-D CTA results and 14 false-positive 3-D CTA results (Table 2).

TABLE 2: Aneurysm location and detection by 3-D CTA

Site and type	No. of aneurysms	3-D CTA		
		T+	F-	F+
Carotid, cavernous	1	...	1	...
Carotid, ophthalmic	4	4	...	1
Carotid, PCo A/A Chor	25	22	3	4
Carotid, Bifurcation	6	6
A1	1	...	1	1
ACo complex	19	18	1	...
A2 and Distal	2	...	2	1
M1	2	2	...	3
M1/M2	28	28	...	4
Basilar tip	4	4
Basilar/superior cerebellar	1	1
Vertebral/PICA	1	...	1	...
Total	94	85	9	14

Note.—CTA indicates CT angiography; T+, true positive; F-, false negative; F+, false positive; PCo A/A Chor, posterior communicating or anterior choroidal artery; ACo complex, anterior communicating artery complex; and PICA, posterior inferior communicating artery.

TABLE 3: Value of 3-D CTA in identifying aneurysms and patients with aneurysms

	All aneurysms (%)	All patients (%)
Sensitivity	85/94 (90.4)	62/63 (98.4)
Specificity	14/28 (50)	14/17 (82.4)
Positive predictive value	85/99 (85.9)	62/65 (95.4)
Negative predictive value	14/23 (60.9)	14/15 (93.3)

Note.—CTA indicates CT angiography; sensitivity = number of true-positive results/(number of true-positive results + number of false-negative results); specificity = number of true-negative results/(number of true-negative results + number of false-positive results); positive predictive value = number of true-positive results/(number of true-positive results + number of false-positive results); and negative predictive value = number of true-negative results/(number of true-negative results + number of false-negative results).

Using catheter angiography (or surgical measurement in one patient) as the reference standard, 3-D CTA (a) correctly identified 16 (100%) of 16 aneurysms larger than 11 mm, 43 (95.6%) of 45 aneurysms measuring between 6 and 10 mm, 19 (86.4%) of 22 aneurysms measuring between 4 and 5 mm, and 7 (63.6%) of 11 aneurysms smaller than 3 mm; (b) correctly showed maximum aneurysm size to within 1 mm in 81% and to within 2 mm in 90.5% (information available in 71 patients); and (c) revealed aneurysm neck size to within 2 mm in 95% (information available in 42 patients).

Sensitivity, specificity, positive predictive value, and negative predictive value for all aneurysms are listed in Table 3. For 3-D CTA to be an effective screening test for aneurysms in the

general population, it must correctly give a negative result for people without aneurysms and correctly identify at least one aneurysm in those with solitary or multiple aneurysms. In our 80 patients, 3-D CTA had a sensitivity of 98.4% (62/63), a specificity of 82.4% (14/17), a positive predictive value of 95.4% (62/65), and a negative predictive value of 93.3% (14/15) (Table 3).

Discussion

Accuracy of 3-D CTA in Aneurysm Detection

The sensitivity of 3-D CTA for all aneurysms was 90.4% (85/94). This compares favorably with the 82% recorded for CT infusion scanning (14), but it appears no better than the 90.8% recorded when reformations are also performed (13). This suggests that 3-D CTA offers no additional advantage over the latter technique; certainly, for symptomatic aneurysms in these series, this is true (96.8% vs 98.5%). For incidental aneurysms, however, 3-D CTA is more accurate (78.1% vs 67%); despite the longer reconstruction time, this may justify its use when one is looking for smaller aneurysms.

Some limitations of 3-D CTA in the detection of aneurysms are disclosed by an analysis of the 14 false-positive results and 9 false-negative results (Table 2). These limitations include its susceptibility to motion artifacts (2 false-positive results) and the possibility of confusing high-attenuation blood clot with intravascular contrast material in an aneurysm (2 false-positive results), especially when surface rendered techniques are used.

In addition, its inherent low spatial resolution (caused in part by our decision to use a 2-mm section thickness, which gives improved low contrast resolution at the expense of reduced spatial resolution) makes it difficult to (a) differentiate tight vascular loops from small aneurysms (three false-positive results) (Fig 1) and (b) differentiate an infundibulum of the posterior communicating artery from an aneurysm (four false-positive results) (Fig 2). Similar difficulties have been recorded by others (12). The other three false-positive results occurred in the group for whom angiographic results were negative.

Thirteen of 14 false-positive findings measured 3 mm or less. The probability of rupture is low for aneurysms of this size (17–20), so this

Fig 1. A, Surface-rendered 3-D CTA of circle of Willis, viewed from above, shows false-positive aneurysms arising from the superior aspect of both internal carotid arteries (*arrows*). Note the irregular appearance of the left middle cerebral artery and branches, produced by sub-arachnoid blood clot misregistering as vessel lumen.

B, Lateral projection carotid angiogram shows distal origin of ophthalmic artery (*arrows*), which was responsible for a false-positive result on 3-D CTA.

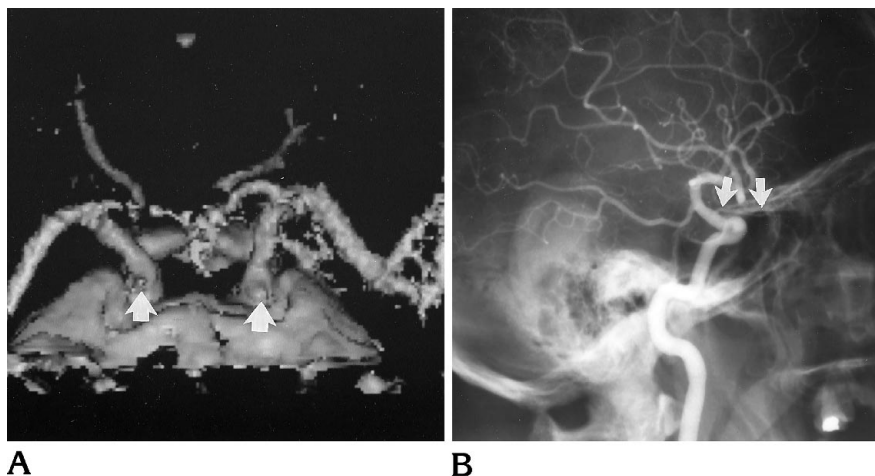
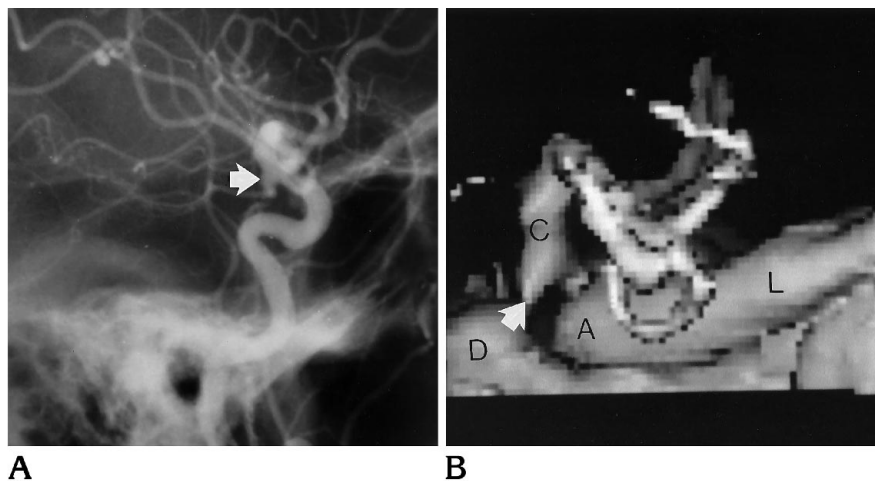


Fig 2. A, Lateral projection carotid angiogram shows infundibulum (*arrow*) at origin of posterior communicating artery.

B, Corresponding surface-rendered 3-D CTA that identified the infundibulum but misinterpreted it as an aneurysm (*arrow*). A indicates anterior clinoid process; C, distal internal carotid artery; D, dorsum sellae; and L, lesser wing of sphenoid.



result suggests that the index of suspicion used in analyzing the images may have been too high. However, use of a lower index of suspicion would have led to a higher false-negative rate for the 1 symptomatic and 10 asymptomatic aneurysms smaller than 3 mm.

In the false-negative group ($n = 9$), three aneurysms were missed because they were outside the imaging volume (one aneurysm of the posterior inferior communicating artery and two distal anterior cerebral aneurysms). At present, our technique includes more than 96% of aneurysm sites (21–23) but it should be possible with helical scanning to extend the imaging volume and thus reduce this source of error.

Four aneurysms were missed because they were close to the skull base and were difficult to identify against the bony background (Fig 3). The two remaining false-negative results included one aneurysm in the cavernous portion

of the internal carotid artery and a 2-mm aneurysm that projected from the inferior aspect of the A1 segment of the anterior cerebral artery.

Finally, size was an important determinant of the six false-negative results within the imaging volume. Four of these measured 4 mm or less.

The sensitivity of MR angiography for detection of aneurysms (85.7%) has been tested in a small series (15); that technique holds promise as a screening test for aneurysms. However, a larger number of patients must be studied before firm conclusions can be drawn.

Use of 3D-CTA for Noninvasive Screening of Groups at Risk

The role of 3-D CTA, when it is used as a screening test, is not to identify every aneurysm but to identify every patient with one or more aneurysms (since identification of at least one

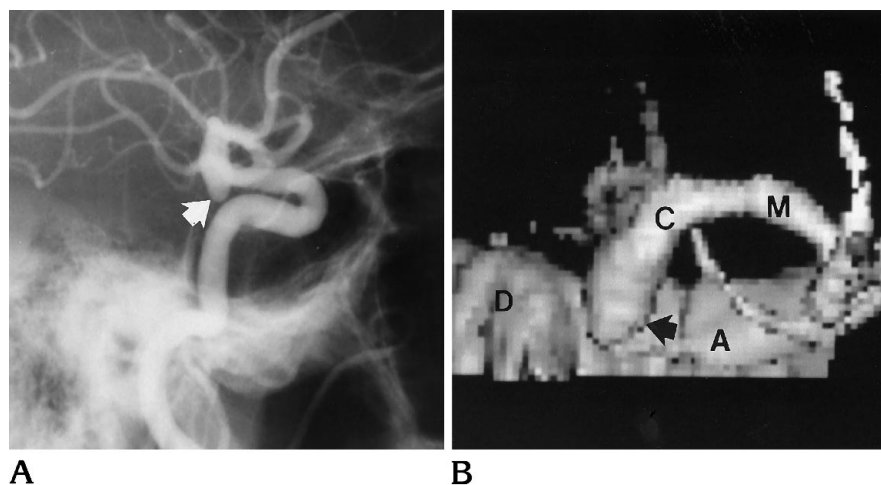


Fig 3. A, Lateral projection carotid angiogram shows a small posterior communicating artery aneurysm (arrow) directed inferiorly from the internal carotid artery.

B, Surface-rendered 3-D CTA (viewed from 20° posterior to true lateral) shows the same aneurysm (arrow) that was missed prospectively against the background bone of the skull base. A indicates anterior clinoid process; C, distal internal carotid artery; D, dorsum sella; and M, M1 segment.

indicates the need for four-vessel angiography in that patient). Three-dimensional CTA must also have a low false-positive rate in those who have no aneurysms. The sensitivity, specificity, positive predictive value, and negative predictive value of 3-D CTA are better when applied to all patients than when applied to all aneurysms (Table 3). These figures suggest that 3-D CTA has a role as a noninvasive screening test for asymptomatic aneurysms (6); however, there are limitations to extrapolating data derived from our symptomatic patients to patients in at-risk populations who have asymptomatic aneurysms, and these limitations need to be emphasized. For example, asymptomatic aneurysms are smaller than symptomatic aneurysms (17, 18, 24). Any proposed screening test for aneurysms must be able to identify these smaller aneurysms. In our series, 3-D CTA had a sensitivity of 78.8% and a specificity of 51.9% for aneurysms measuring 5 mm or less. These results would yield a net benefit of 1.5 years difference in survival if they were applied to a screened population of patients younger than 25 years, with an occurrence rate of aneurysms exceeding 30% and a surgical complication rate of 1% or less (6). This sensitivity and this specificity appear to be less satisfactory than those for MR angiography (15), but the mean size of aneurysms in that MR angiography study (15) was 11.6 mm, and only 6 of the 21 aneurysms studied were 5 mm or smaller.

Other limitations include the possibility of bias introduced by the localizing nature of subarachnoid hemorrhage on CT (25) and the potential bias introduced by the 57 patients who

did not undergo 3-D CTA. We analyzed both these issues and determined that they had no significant effect on our results.

A final potential limitation of this study is the small number of patients who had negative findings at angiography ($n = 17$). We have used positive predictive value and negative predictive value (two important indexes in evaluating screening tests) to describe the accuracy of 3-D CTA in predicting the presence and absence of an aneurysm. Although the number of patients is large enough to give confidence to the positive predictive values found, a larger number of true negatives ($n = 14$) would be required to increase confidence in the negative predictive values obtained.

3-D CTA as a Supplement to Angiography

Despite the sensitivity of 3-D CTA and CT infusion techniques in the detection of acutely ruptured aneurysms (13), these methods are unlikely at present to replace catheter angiography in the primary workup of subarachnoid hemorrhages, primarily because of their poor spatial resolution, which limits the definition of surgically important vessels such as the anterior choroidal artery. However, 3-D CTA may replace angiography in patients with intracerebral hematomas and rapidly declining neurologic function (14), and it may be able to screen for aneurysms in patients with oculomotor palsy (12).

An important role of 3-D CTA is as an adjunct to angiography, because it can provide surgically important information about the shape and direction of an aneurysm and its relation to

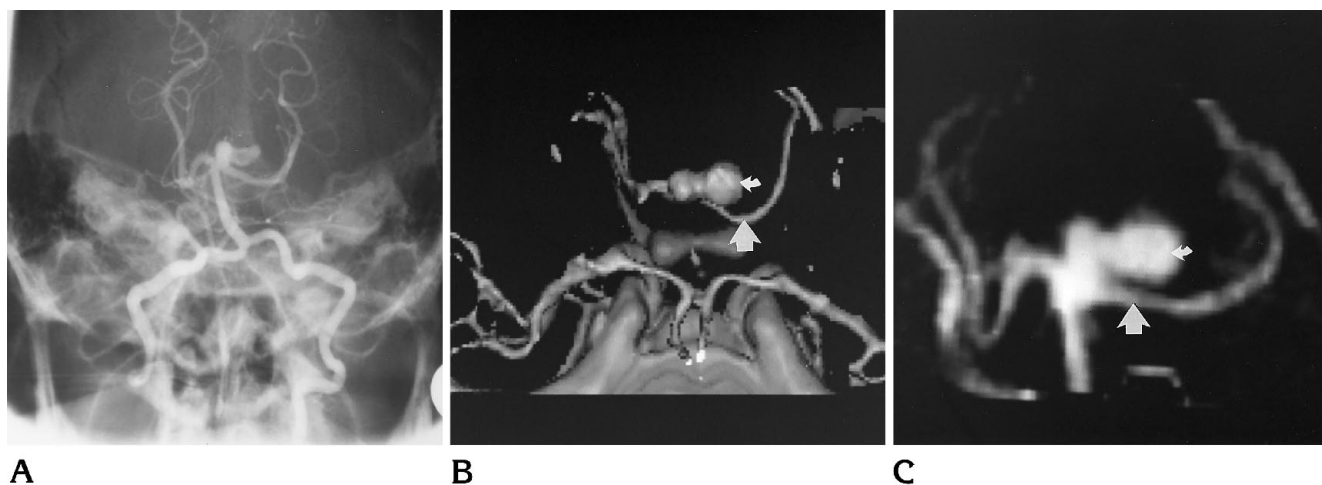


Fig 4. A, Steep Townes projection from vertebral angiogram shows basilar tip aneurysm with loculus directed to the left. B and C, Surface-rendered 3-D CTA viewed from directly above (B) and maximum-intensity projection 3-D CTA viewed from anteriorly (C) show the relationship of the loculus (small arrow) of the aneurysm to the left P1 segment (large arrow).

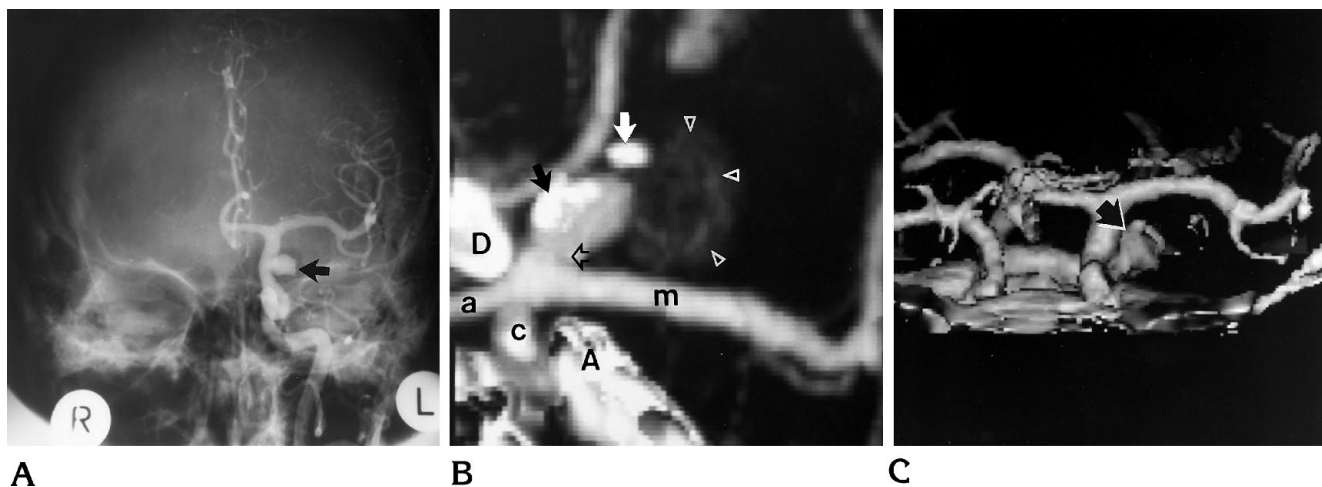


Fig 5. A, Anteroposterior projection, left carotid angiogram shows posterior communicating artery aneurysm (arrow) directed laterally from origin. Note absence of calcification.

B, Maximum-intensity projection 3-D CTA, coned to left side of circle of Willis and viewed from above, shows relationship of aneurysm lumen and calcification in aneurysm wall (black and white solid arrows) to neck of aneurysm (open arrow). The cap of thrombus within the partially thrombosed aneurysm is also visible (arrowheads). A indicates anterior clinoid process; c, internal carotid artery; D, left side of dorsum sella; m, middle cerebral artery; and a, anterior cerebral artery.

C, Surface-rendered 3-D CTA (shallow Townes projection) of the same aneurysm (arrow) shows the limitations imposed by the inability to differentiate calcification from opacified blood in aneurysm lumen. The thrombus in the aneurysm is not seen because its density falls below the prescribed threshold.

adjacent vessels (16) (Fig 4). In this setting, maximum-intensity projection is usually preferable because surface-rendered 3-D CTA uses a threshold of 70 to 100 HU that may not allow the differentiation of clotted blood from contrast-enhanced aneurysm lumen (two false-positive results in our study). Maximum-intensity projection images are not threshold-dependent, and this characteristic may be useful in larger aneurysms to display the relationship between intraluminal thrombus and the aneurysm

neck or lumen and to identify mural calcification and its relationship to the neck (Fig 5).

Follow-up of Incidental Aneurysms

Incidental aneurysms are now commonly found because of the widespread availability of CT and MR (8). In the absence of surgery, follow-up is desirable because such aneurysms tend to grow (26). This ordinarily requires angiography; however, the abilities of 3-D CTA to

portray aneurysm morphology accurately (16) and to display aneurysm size and neck size to within 2 mm (90.5% and 95%, respectively), coupled with a low risk of contrast-related complications (27–29), suggest it can replace arteriographic follow-up in these patients. It has one additional advantage over MR imaging: 3-D CTA allows follow-up of incidental aneurysms in patients who have previously undergone clipping of a symptomatic aneurysm.

References

1. Phillips LH II, Whishnani JP, O'Fallan WM, et al. The unchanging pattern of subarachnoid haemorrhage in a community. *Neurology* 1980;30:1034–1040
2. Drake CG. Management of cerebral aneurysm. *Stroke* 1981;12:273–283
3. Jain KK. Surgery of intact intracranial aneurysms. *J Neurosurg* 1974;40:494–498
4. Salazar JL. Surgical treatment of asymptomatic and incidental intracranial aneurysms. *J Neurosurg* 1980;53:20–21
5. Samson DS, Hodosh RM, Kemp Clark W. Surgical management of unruptured asymptomatic aneurysms. *J Neurosurg* 1977;46:731–734
6. Levey AS, Pauker SG, Kassirer JP. Occult intracranial aneurysms in polycystic kidney disease: when is cerebral arteriography indicated? *N Engl J Med* 1983;308:986–994
7. Chyatte D. The epidemiology, genetics and clinical behavior of intracranial aneurysms. In: Awad IA, ed. *Current Management of Cerebral Aneurysms*. New York, NY: McGraw Hill, 1993:1–20
8. Leblanc R. Unruptured aneurysms, multiple aneurysms, familial aneurysms, and aneurysms in pregnancy. In: Awad IA, ed. *Current Management of Cerebral Aneurysms*. New York, NY: McGraw Hill, 1993:277–295
9. Mani RL, Eisenberg RL, McDonald EJ Jr, et al. Complications of catheter cerebral angiography: analysis of 5000 procedures, parts I–III. *AJR Am J Roentgenol* 1978;131:861–874
10. Peret G, Nishioka H. Report on the Cooperative Study of Intracranial Aneurysms and Subarachnoid Haemorrhage, section IV: cerebral angiography and the analysis of the diagnostic value and complications of carotid and vertebral angiography in 5484 patients. *J Neurosurg* 1966;25:98–114
11. Grzyska U, Freitag J, Zeumer H. Selective cerebral intraarterial DSA: complication rate and control of risk factors. *Neuroradiology* 1990;32:296–299
12. Teasdale E, Statham P, Straiton J, et al. Non-invasive radiological investigation for oculomotor palsy. *J Neurol Neurosurg Psychiatry* 1990;53:549–553
13. Schmid UD, Steiger HJ, Huber P. Accuracy of high resolution computed tomography in direct diagnosis of cerebral aneurysms. *Neuroradiology* 1987;29:152–159
14. Newell DW, LeRoux PD, Dacey RG, et al. CT infusion scanning for the detection of cerebral aneurysms. *J Neurosurg* 1989;71:175–179
15. Ross JS, Masaryk TJ, Modic MT, et al. Intracranial aneurysms: evaluation by MR angiography. *AJNR Am J Neuroradiol* 1990;11:449–450
16. Aoki S, Sasaki Y, Machida T, et al. Cerebral aneurysms: detection and delineation using 3-D CT angiography. *AJNR Am J Neuroradiol* 1992;12:1115–1120
17. de la Monte SM, Moore GW, Monk MA, et al. Risk factors for the development and rupture of intracranial berry aneurysms. *Am J Med* 1985;78:957–964
18. McCormick WF, Acosta-Rua GJ. The size of intracranial saccular aneurysms: an autopsy study. *J Neurosurg* 1970;33:422–427
19. Crompton MR. Mechanism of growth and rupture in cerebral berry aneurysms. *Br Med J* 1966;1:1138–1142
20. Freytag E. Fatal rupture of intracranial aneurysms: survey of 250 medico legal cases. *Arch Pathol* 1966;81:418–424
21. Newton TH, Potts DG. *Radiology of the Skull and Brain*, vol 2, book 4: *Angiography: Specific Disease Processes*. St Louis, Mo: CV Mosby, 1974:2449
22. Yasargil MG. *Microneurosurgery*. New York, NY: Georg Thieme Verlag, 1984; 1:299
23. Marks PV, Hope JKA, Cluroe AD, et al. Racial differences between Maori and European New Zealanders in aneurysmal subarachnoid haemorrhage. *Br J Neurosurg* 1993;7:175–182
24. Chason JL, Hindman WM. Berry aneurysms of the circle of Willis: results of a planned autopsy study. *Neurology* 1958;9:41–44
25. Drake CG, Girin JP. The surgical treatment of subarachnoid hemorrhage with multiple aneurysms. In: Morlet TP, ed. *Current Controversies in Neurosurgery*. Philadelphia, Pa: WB Saunders, 1976:274–278
26. Allcock JM, Canham PB. Angiographic study of the growth of intracranial aneurysms. *J Neurosurg* 1976;45:617–621
27. Palmer FJ. The RACR Survey of Intravenous Contrast Media Reactions Final Report. *Australas Radiol* 1988;32:426–428
28. Katayama H, Yamaguchi K, Kozuka T, et al. Adverse reactions to ionic and nonionic contrast media: a report from the Japanese Committee on the Safety of Contrast Media. *Radiology* 1990;175:621–628
29. Schrott KM, Behrends B, Clauss W, et al. Cited by: McClennan BL. Low-osmolality contrast media: premises and promises. *Radiology* 1987;162:1–8