AJNR

The no-reflow phenomenon and dense fibrillary gliosis, cause of dark T2-weighted MR signal in stroke.

S B Halls

AJNR Am J Neuroradiol 1996, 17 (2) 394-395
http://www.ajnr.org/content/17/2/394.citation

This information is current as of July 19, 2025.

LETTERS

The No-Reflow Phenomenon and Dense Fibrillary Gliosis, Causes of Dark T2-Weighted MR Signal in Stroke

In the recent *AJNR* article by Ida et al (1), dark T2 signal is described in the subcortical white matter of stroke patients. The authors speculate that free-radical production and iron accumulation via axonal transport are the explanation for the dark areas on T2-weighted magnetic resonance (MR) images. Perhaps another possible explanation in the acute phase of infarction is the "no-reflow" phenomenon (2, 3). This refers to stasis and sludging of erythrocytes in an area undergoing infarction. Deeply desaturated deoxyhemoglobin within intact red blood cells (within intact blood vessels) could cause the MR findings described.

It is well known that there are many patterns of stroke, sometimes primarily affecting cortical gray matter (4), sometimes affecting white matter (5, 6), and sometimes affecting both to various degrees (7). Deeper layers of cortical gray matter are usually more susceptible to ischemia than superficial cortex (8). Similarly, the periventricular white matter (9, 10, 11) is usually more susceptible to ischemia than subcortical white matter (but not always [12]). Certain MR findings occur only under certain circumstances, and a hypothetical series of events causing the dark subcortical white matter might be as follows. During the development of an acute infarct, if cytotoxic cellular swelling in deep cortical gray matter and periventricular white matter were to occur simultaneously, it could obstruct venous outflow (13) from the subcortical white matter, trapping and sludging red blood cells and possibly giving the dark T2 signal. This is a temporary situation, because usually zonal differences in interstitial pressure will eventually equalize, and sludged red blood cells will be squeezed back into circulation.

Although Ida et al's findings suggest that the acute and chronic dark T2 signal are closely related, I wonder if the chronic-phase dark T2 signal can develop independently, or perhaps is indirectly stimulated by the particular physiology that occurred during the acute event. I would like to offer this additional possible explanation for the dark T2 signal seen in the chronic phase. The gradual accumulation of unusually "dense fibrillary gliosis" is occasionally noted in pathological descriptions (14, 15, 16, 17) of infarction. It can be a tight, dense intracellular mesh of fibrils laid down within the processes of fibrillary astrocytes. Although typical "moderate" gliosis is usually bright on T2-weighted images because of the presence of some intracellular water and residual extracellular edema, the chronic "dense" gliosis may have no residual extracellular edema and the denseness of the fibrillary mesh may exclude free intracellular water, and possibly appear darker on T2-weighted images (18). Also, remember that big molecules are dark on T2-weighted images (19). It has been noted that subcortical white matter has a larger population of fibrillary astrocytes (20, 21) and that extracellular edema can stimulate astrocytes (22) to produce glial fibrillary acidic protein fibrils.

Ida et al's presentation of the findings is excellent, and broad range of possible explanations were discussed. I know that many of my colleagues have wondered about this finding, and we all await studies with pathological correlation.

Steven B. Halls
Department of Oncologic Imaging
Cross Cancer Institute
Edmonton, Alberta
Canada

References

1. Ida M, Mizunuma K, Hata Y, Tada S. Subcortical low intensity in early cortical ischemia. *AJNR Am J Neuroradiol* 1994;15:1387–1393
2. Ames A III, Wright RL, Kowada M, Thurston JM, Majno G. Cerebral ischemia, II: the no-reflow phonemonenon. *Am J Pathol* 1968;52:437–453
3. White BC, Wiegenstein JG, Winegar CD. Brain ischemic anoxia: mechanisms of injury. *JAMA* 1984;251:1586–1590
4. Sawada H, Udaka F, Seriu N, Shindou K, Kameyama M, Tsujimura M. MRI demonstration of cortical laminar necrosis and delayed white matter injury in anoxic encephalopathy. *Neuroradiology* 1990;32:319–321
5. Burger PC, Vogel FS. Hemorrhagic white matter infarction in three critically ill patients. *Hum Pathol* 1977;8:121–132
6. Dambska M, Laure-Kamionowska M, Schmidt-Sidor B. Early and late neuropathological changes in perinatal white matter damage. *J Child Neurol* 1989;4:291–298
7. Romanul FCA. Selective infarction of grey or white matter caused by occlusion of large arteries. *Clin Dev Med* 1971;39/40:41–46
8. Malone M, Prior P, Scholtz CL. Brain damage after cardiopulmonary by-pass: correlations between neurophysiological and neuropathological findings. *J Neurol* 1981;44:924–931
9. Mayer PL, Kier EL. The controversy of the periventricular white matter circulation: a review of the anatomic literature. *AJNR Am J Neuroradiol* 1991;12:223–228
10. Young RSK, Hernandez MJ, Yagel SK. Selective reduction of blood flow to white matter during hypotension in newborn dogs: a possible mechanism of periventricular leukomalacia. *Ann Neurol* 1982;12:445–448
11. Chimowitz MI, Awad IA, Furlan AJ. Periventricular lesions on MRI: facts and theories. *Stroke* 1990;20:963–967
12. Houdou S, Takashima S, Takeshita K, Ohta S. Infantile subcortical leukohypodensity demonstrated by computed tomography. *Pediatr Neurol* 1988;4:165–167
13. Chiang J, Kowada M, Ames A III, Wright RL, Majno G. Cerebral ischemia, III: vascular changes. *Am J Pathol* 1968;52:455–476
14. Courville CB. Pathogenesis of nodular atrophy of the cerebral cortex. *Arch Pediatr* 1960;77:101–129

15. Gilles FH, Averill DR, Kerr C. Changes in neonatally induced cerebral lesions with advancing age. *J Neuropathol* 1977;36:666–679
16. Neumann M, Cohn R. Progressive subcortical gliosis, a rare form of presenile dementia. *Brain* 1967;90:405–418
17. Feigin I, Budzilovich GN. Laminar scars in cerebral white matter: a perinatal injury due to edema. *J Neuropathol* 1978;37:314–325
18. Barnes D, McDonald WI, Landon DN, Johnson G. The characterization of experimental gliosis by quantitative nuclear magnetic resonance imaging. *Brain* 1988;111 (Pt 1):83–94
19. Edelman RR, Kleefield J, Wentz KU, Atkinson DJ. Basic principles of magnetic resonance imaging. In: Edelman RR, Hesselink JR, eds. *Clinical Magnetic Resonance Imaging*. Philadelphia, Pa: Sauders; 1990:14–15
20. Takashima S, Becker LE, Nishimura M, Tanaka J. Developmental changes of glial fibrillary acidic protein and myelin basic protein in perinatal leukomalacia: relationship to a predisposing factor. *Brain Dev* 1984;6:444–450
21. Takashima S, Becker LE. Developmental changes of glial fibrillary acidic protein in cerebral white matter. *Arch Neurol* 1983;40:14–18
22. Weller RO, Williams BN. Cerebral biopsy and assessment of brain damage in hydrocephalus. *Arch Dis Child* 1975;50:763–767

Reply

We thank Dr Halls for his careful review of our paper and excellent suggestion. In our study, we used conventional spin-echo proton-density and T2-weighted sequences at 1.5 T. At present, we use fast spin-echo T2-weighted imaging with an echo train length of 15, a repetition time of 4000 to 5000 milliseconds, an echo time of 120 milliseconds, and a matrix of 192 × 512 at 1.5 T for brain imaging. Although fast spin-echo is less sensitive to magnetic susceptibility, we occasionally encountered subcortical low intensity not only in patients with early cortical infarction but also at the edges of large infarctions in areas fed by hemispheric branches and in patients with cerebral contusion. Because a proton density–weighted sequence is not carried out in all patients (we use a single-echo fast spin-echo sequence routinely), subcortical low intensity is valuable to diagnose cortical infarction. We have had no experience of pathological correlation to date.

The pathogeneses for subcortical low intensity that we discussed were speculative and based on the MR findings, course, and previous reports. There remains the question of whether free radicals or iron contribute to decreased signal on T2-weighted images, because free radicals are too unstable and short-lived and iron accumulation is probably subtle. It is certain that free radicals cannot be produced or exist until the chronic stage, nor can sufficient iron or degenerative debris accumulate in the acute stage. Therefore, we must discuss the pathogenesis of the acute phase and chronic phases separately. Dr Halls suggests that the no-reflow phenomenon and dense fibrillary gliosis are more likely to explain the subcortical low intensity. We agree that those may be of importance in the pathogenesis.

The no-reflow phenomenon is considered a cause of postischemic injury in the acute phase. Changes in vessels play a major role in the no-reflow phenomenon. The failure of active sodium transport causes cellular swelling (blebbing) of perivascular astrocytes and endothelial cells. Some of the swollen cells become detached and float away into the lumen. Swelling of astocytic feet and endothelial cells causes a reduction in caliber of arterioles, capillaries, and venules. Detached and floated cells act as embloli. The no-reflow phenomenon is a result of these vessel changes with a combination of hypotension and increased blood viscosity (Dr Halls's references 2 and 13). If cortical damage causes narrowing of the lumens of the venules draining the adjacent subcortical white matter or arterioles of the deep cortical layer, stagnation and stasis of erythrocytes could occur and deoxydation of oxyhemoglobin in the erythrocytes could lead to magnetic inhomogeneity and reduction of T2 signal. Those phenomena could occur in the early phase.

We consider the subcortical low intensity to be reversible in early cortical ischemia. In our case material, hypointensity remained until the chronic stage in two cases. We find similar changes at the periphery of chronic infarction. We think the low intensity identified in the chronic stage must be attributed to a different pathogenesis from that seen in the acute stage. We hypothesized that there was iron accumulation caused by failure of axonal transport and wallerian degeneration in the chronic stage. Dense fibrillary gliosis with less extracellular and intracellular free water, which Dr Halls suggests (his references 14 through 18), is an excellent explanation, based on pathological correlation, for the low intensity seen in the chronic stage.

We cannot explain the pathogenesis more definitively because we have no cases proved pathologically.

Masahiro Ida
Department of Radiology
Tokyo Metropolitan Ebara Hospital
Japan

Kimiyoshi Mizunuma
Yuichi Hata
Shimpei Tada
Department of Radiology
Jikei University School of Medicine
Japan

MR Pulse Sequences for Herniated Disks

MR imaging yields more diagnostic information than computed tomography (CT) in the evaluation of degenerative spinal disease. However, it must be optimized with regard to signal/noise, resolution, and contrast (1). Fast spin-echo and other techniques are currently being applied to spinal imaging. It is therefore imperative that published articles state *all* of the parameters used in pulse sequences so that others may duplicate the study or be able to compare fully with other techniques in use.

In a recent article in *AJNR* (2) the authors used fast spin-echo sequences with 3- or 4-mm section thickness, 0.1- to 1-mm gap, and 192 × 256 matrix. What were the

fields of view? By visual analysis, I would estimate a 24- to 28-cm field of view, but with spatial blurring from the fast spin-echo technique, the effective resolution would be diminished. What were the echo train lengths? Were there split echo trains, with 5 echoes to the proton-density images and 5 echoes to the heavily T2-weighted images?

The proton-density image yields the best overall contrast in assessing a herniated disk's margins. One would expect the authors' results to have been significantly improved by a higher resolution matrix (eg, 385 × 512) and a shorter echo train with shorter echo time.

All radiology journals including *AJNR* should develop a standardized format for reporting methods of MR pulse sequences. It is even more critical now that a whole new generation of pulse sequences (turbograse, echo planar, etc) will soon be tested in clinical imaging.

Jonathan Wiener
Director, MRI
Boca Raton (Fla) Community Hospital and
MRI of Jupiter

References

1. Ross JS, Tkach J, VanDyke C, Modic MT. Clinical MR imaging of degenerative spinal diseases: pulse sequences, gradiant echo techniques and contrast agents. *J Magn Reson Imag* 1991;1:29–37
2. Silverman CS, Lenchik L, Shimkin PM, Lipow KL. The value of MR in differentiating subligamentous from supraligamentous lumbar disk herniations. *AJNR Am J Neuroradiol* 1995;16:571–579

Reply

We thank Dr Wiener for his comments regarding certain imaging parameters that were not stated in our article and take this opportunity to furnish that information. The field of view was 24 cm. The echo train length for the fast spin-echo sequences was 8, split into dual echoes with effective echo times of 16 and 96. Although our article includes the usual information regarding imaging parameters, we nonetheless agree that a standardized method of including all parameters would enable better duplication and comparison.

With regard to the comment on a higher resolution matrix, the parameters used in our study certainly were not substandard. The changes in imaging matrix and echo train length proposed by Dr Wiener would have a profound impact on imaging time and the signal-to-noise ratio of the images. Increasing the imaging matrix from 256 × 192 to 512 × 384 would double imaging time by requiring twice as many phase-encoding steps. Because the voxel volume would be fourfold smaller, and the data sampling by the increased phase-encoding steps would be doubled, the impact on the signal-to-noise ratio would be $\sqrt{2}/4$, yielding almost a threefold reduction in the signal-to-noise ratio. If we shortened our echo train length from 8 to 4, as Dr Wiener suggests, our imaging time would double again. Concerns of patient motion during longer imaging times might outweigh the benefits of improved resolution. The effects that the proposed changes in imaging matrix and echo train length would have on resolution, signal-to-noise ratio, and imaging time are illustrated in Figure 1.

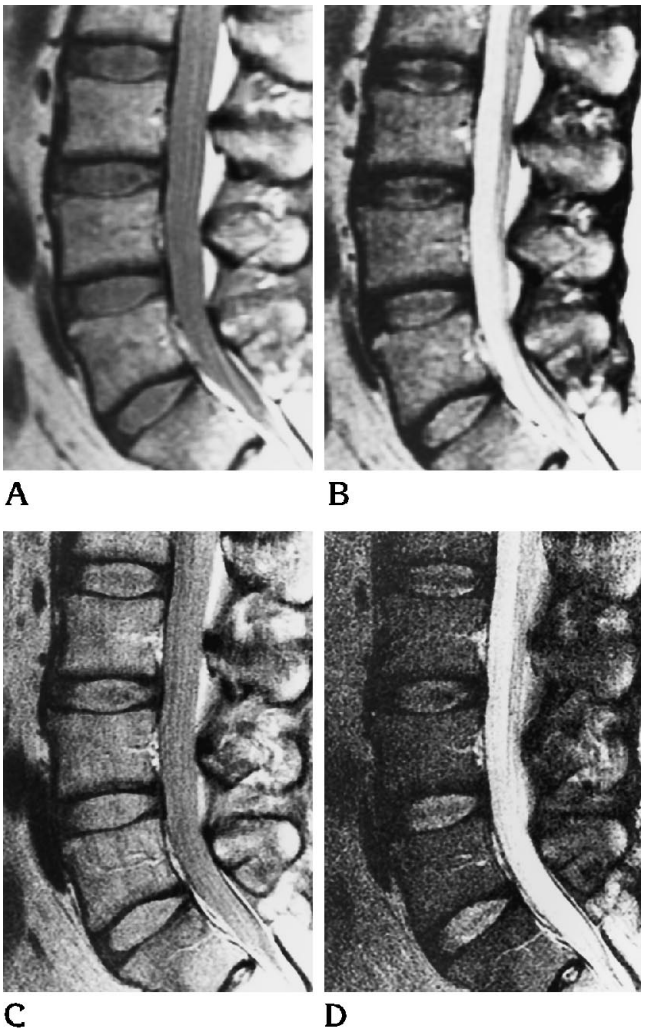

Fig 1. Effects on resolution, signal-to-noise ratio, and imaging time with the proposed changes in imaging matrix and echo train length.

A and B, Images obtained with the imaging matrix and echo train length used in our study. Sagittal proton-density (*A*) and T2-weighted (*B*) dual-echo fast spin-echo sequences (2100/16/2, 2100/96/2 [repetition time/echo time/excitations], 256 × 192 image matrix, echo train length 8, 3-mm section thickness, 1-mm gap, imaging time of 3 minutes 26 seconds).

C and D, Images obtained with the proposed higher-resolution imaging matrix and shorter echo train length. Sagittal proton-density (*C*) and T2-weighted (*D*) dual-echo fast spin-echo sequences (2100/26/2, 2100/104/2, 512 × 384 image matrix, echo train length 4, 3-mm section thickness, 1-mm gap, imaging time of 13 minutes 31 seconds).

The decrease in the signal-to-noise ratio with the proposed changes in imaging matrix and echo train length is profound. Because the effect on the signal-to-noise ratio is not as apparent on the proton-density sequence as on the T2-weighted sequence, a supplementary proton-density

sequence with the higher resolution imaging matrix and shorter echo train length might have a role for determining the integrity of the posterior longitudinal ligament. Alternatively, a compromise in the imaging matrix to a value between Dr Wiener's recommendation and our current technique, such as 384 × 256, might yield improved resolution with both an acceptable signal-to-noise ratio and tolerable imaging times. However, we cannot speculate whether these changes would improve the ability to differentiate subligamentous from supraligamentous lumbar disk herniations.

As improvements in pulse sequences, surface coils, and MR systems progress, much higher resolution should become possible with acceptable signal-to-noise ratio and reasonable imaging time. We anticipate that the value of MR in differentiating subligamentous from supraligamentous lumbar disk herniation will be reassessed with these developing technologies, we hope with results better than ours.

Craig S. Silverman
Ruben Kier
Department of Radiology
Bridgeport (Conn) Hospital

Comment

Dr Wiener brings up a difficult problem that has plagued editors, authors, and researchers for several years. When publishing an MR study, how does one best report the *pertinent* MR study parameters? I wish to emphasize the adjective *pertinent*, because that criterion must ultimately guide whatever reporting scheme is chosen. By last count, the MR protocol book used by our technologists, residents, and fellows listed approximately 25 technical parameters that must be specified for complete description of a pulse sequence. In addition to the parameters cited by Dr Wiener, one must also specify such factors as the readout bandwidth that affects signal-to-noise ratio, the direction of the phase- and frequency-encoding gradients that determine artifact and chemical shift orientation, whether flow compensation gradients are used and for which direction(s), whether a fat saturation technique is used, and so on. Although editors can require all of this information from authors, it would be overwhelming to many readers and the additional journal space required would further increase publication costs and, ultimately, subscription prices.

Obviously, what is needed is a rational approach, one that ensures that *pertinent* technical data are included in the methods description of each paper. This requires some exercise of judgment on the part of reviewers and editors. For example, a technical description of a new pulse sequence or an MR angiographic study requires more-inclusive parameter descriptions than a clinical description of MR findings in early stroke. Although exercise of such judgment might occasionally result in fewer technical parameter listings than might be desired by an individual investigator, I believe that this is infrequent and, in those cases, the authors can be contacted directly. These few omissions must be balanced against limited journal space and potentially poorer readability of an article caused by cumbersome inclusion of myriad technical information.

I should also point out that even very detailed listing of MR technical parameters will not provide the answers to all questions raised by an interested researcher. Pulse sequence parameters are not always directly transferable to a machine from a different manufacturer and it may not be possible to compare expected results from different MR protocols merely on the basis of the technical factors. For example, should one expect the clinical results to appear better for a classic spin-echo T2-weighted sequence of 2500/100/1 with a 256 × 192 matrix and a bandwidth of 8 kHz, or for a fast spin-echo T2-weighted sequence of 3500/102/1, echo train length of 16, 256 × 256 matrix, and bandwidth of 32 kHz if other parameters are held constant? When confronted with such a dilemma, one must resort to the images to answer this question. As clinical radiologists, we ultimately decide what techniques are best for a specific patient problem based on a number of factors, but our final least common denominator is whether the image quality is good enough to make the diagnosis. If one desires to duplicate or improve on a reported clinical technique, then one needs not only a *pertinent* description of the basic imaging technique but also a good reproduction of representative images. Ultimately the technique may be modified by additional insight and the resulting new technique may be improved. That is how new advances are made—incrementally. I do not feel that the field would be advanced significantly by inclusion of a cumbersome standardized list of pulse sequence parameters or that the cost in terms of additional journal pages would be justified.

Kenneth R. Maravilla
Deputy Editor, AJNR
Department of Radiology
University of Washington Medical Center
Seattle

MR Appearance of the Retroisthmic Cleft

Retroisthmic clefts are less common neural arch clefts than spina bifida occulta and spondylolysis. The CT (1, 2) and radiographic (3, 4) appearance of retroisthmic cleft has been described. Retroisthmic clefts might be misinterpreted or missed by readers unfamiliar with their MR appearance.

In a 61-year-old white man with low back pain and a history of hypertension and renal calculi, MR showed a linear area of decreased signal in the right lamina at L-5 on both T1- and T2-weighted images (Fig 2 A and B). The well-defined sharp borders were more suggestive of a retroisthmic cleft than of a fracture. CT of the pelvis for urologic problems postprocessed to provide magnification and bone windows demonstrated a well-defined linear defect in the lamina with mildly sclerotic borders consistent with a retroisthmic cleft (Fig 2C).

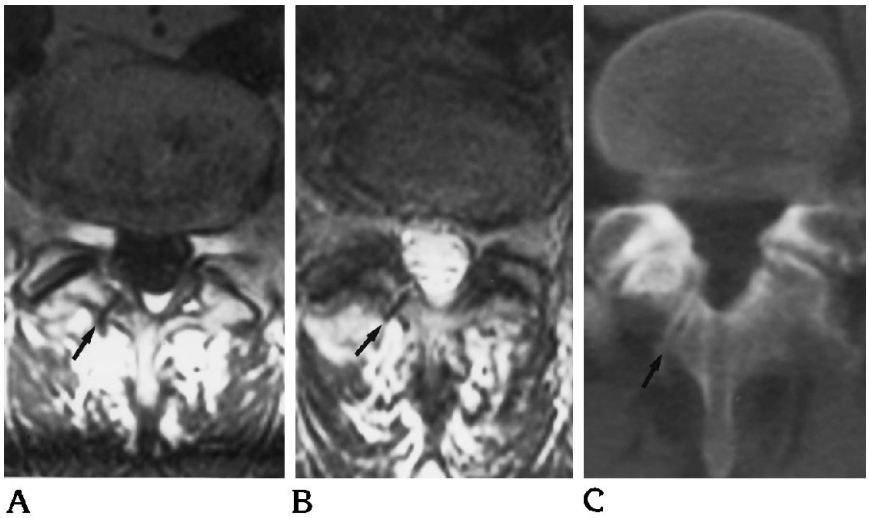

Fig 2. Axial T1-weighted (750/20/2) (*A*) and T2-weighted (5000/93 effective/1) (*B*) MR images through L-5 show a linear area of decreased signal in the right lamina. Magnified axial image from the CT of the pelvis (*C*) shows a well-defined linear defect in the right lamina with sclerotic borders consistent with retroisthmic cleft.

The radiographic appearance of retroisthmic clefts was described by Brocher (5). The retroisthmic cleft is distinguished from a pars intraarticularis defect by its location posterior to the inferior facet joint. It is usually unilateral (3, 4) and an incidental finding in patients with back pain.

Charles W. Horner
Victor M. Haughton
Department of Radiology
Medical College of Wisconsin
Milwaukee

References

1. Johansen JG, Haughton VM, Hemminghytt S. The CT appearance of retroisthmic clefts. *AJNR Am J Neuroradiol* 1984;5:835–836
2. Johansen JG, McCarthy DJ, Haughton VM. Retrosomatic clefts: computed tomographic appearance. *Radiology* 1983;148: 447–448
3. Dürrigl P. Ein Fall von angeborener retroisthmischer Wirbelbogenspalte. *Z Orthop* 1935;100:374–376
4. Seegelken K, Keller H. Retroisthmische Spalte der Lendenwirbelsaule: Fortschritte auf dem Gebiete der Rontgenstrahlen und der neuen bildgebenden. *Verfahren* 1974;121:659–660
5. Brocher JEW. Konstitutionell bedingte Veränderungen des Wirbelbogens: Fortschritte auf dem Gebiete der Rontgenstrahlen und der neuen bildgebenden. *Verfahren* 1960;92:363–380

Reports of Acute Encephalopathy with Bilateral Thalamotegmental Involvement

At first glance, I was excited with the title "Acute Encephalopathy with Bilateral Thalamotegmental Involvement in Infants and Children: Imaging and Pathology Findings" (1). I read the pathology findings first. Although no conclusion as to the neuropathogenesis was reached, infection, infectious demyelination, arterial occlusion, and Reye syndrome are unlikely.

I and my teacher previously reported 3 infants with acute encephalopathy with a striking ultrasonographic finding ("bright thalamus") suggesting panthalamic infarction (2). Afterwards, 5 more children with similar problems were treated. I have reported their clinical and neuroimaging manifestations at the 7th Congress of the International Child Neurology Association at San Francisco, Calif, in 1994 (H. S. Wang, S. C. Huang, P. C. Hung, "Acute Encephalopathy with Panthalamic Plus Lesions: A Major Occurrence in Oriental Children?" *Pediatr Neurol* 1994;11: 135–136 [abstract]). In the same report, 17 children, 14 of whom were Japanese, were reviewed from the English literature. The remaining 3 cases were reported from outside of Japan: 1 from the United States (3) and 2 from the United Kingdom (4). This particular encephalopathy does not occur exclusively in Japanese or Taiwanese children. Yagishita et al have not included the above two reports in their review.

Yagishita et al reviewed many Japanese articles, some of which were not included in my review. One study from Japan not reviewed by Yagishita et al was reported by Nagai et al, who found 9 cells in the cerebrospinal fluid of 2 children, 11 and 27 months of age, respectively, in their 4 cases of influenza A infection with symmetrical thalamic lesions (5). In my own series, 2 children had mild pleocytosis, too.

In my personal opinion, acute encephalopathy with bilateral thalamic and other lesions is a special disease entity in young children. The underlying etiology has not been determined. According to past reports, the dominant occurrence in Asian children, not just in Japanese, suggests that this disease is significantly related to race.

Huei-Shyong Wang
Department of Pediatrics
Chang Gung Medical College and
Chang Gung Memorial Hospital
Taipei, Taiwan
Republic of China

References

1. Yagishita A, Nakano I, Ushioda T, Otsuki N, Hasegawa A. Acute encephalopathy with bilateral thalamotegmental involvement in infants and children: imaging and pathology findings. *AJNR Am J Neuroradiol* 1995;16:439–447
2. Wang HS, Huang SC. Infantile panthalamic infarct with a striking sonographic findings: the "bright thalamus". *Neuroradiology* 1993; 35:92–96
3. Charney EB, Orecchio EJ, Zimmerman RA, Berman PH. Computerized tomography in infantile encephalitis. *Am J Dis Child* 1979; 133:803–805
4. Protheroe SM, Mellor DH. Imaging in influenza A encephalitis. *Arch Dis Child* 1991;66:702–705
5. Nagai T, Yagishida A, Tsuchiya Y, et al. Symmetric thalamic lesions on CT in influenza A virus infection presenting with or without Reye syndrome. *Brain Dev* 1993;15:67–74

Reply

We appreciate Dr Wang's interest in our report. In the report, we referred to the study of Wang and Huang in *Neuroradiology*, and we thought that their three patients had acute encephalopathy, but not thalamic infarction. We could not refer to the other study by Dr Wang, presented at the International Child Neurology Association, because it was published after the submission of our manuscript. They described eight Chinese children with acute encephalopathy and a panthalamic-plus lesion. Their CT features resembled the acute encephalopathy that we had described. However, the report was an abstract of a congress, thus the detail was unknown. We failed to uncover studies from the United States and from the United Kingdom with Medline (Wang's references 3 and 4). The CT image of the patient in the United States (from the study by Charney et al) showed lesions in the thalami that were similar to those of our patients. Although MR imaging was not performed, we would agree with the suggestion that the encephalopathy is predominantly, but not entirely, limited to Asian children. However, images of the two patients from the United Kingdom (the Protheroe and Mellor study) showed abnormalities in the basis pontis as well as in the pontine tegmentum and thalami. None of our patients had abnormalities in the pontine base. Therefore, we thought that the illness of these two patients was different from the encephalopathy that we reported.

None of our 26 patients with acute encephalopathy had pleocytosis. However, mild pleocytosis such as 9 cells might be expected, because acute encephalopathy has associated cerebral necrosis and it has been reported that cerebral infarction may have mild pleocytosis (1). Therefore, mild pleocytosis does not necessarily imply that acute encephalopathy is an encephalitis.

Akira Yagishita
Department of Neuroradiology
Tokyo Metropolitan Neurological Hospital

Imaharu Nakano
Department of Neuropathology
Tokyo Metropolitan Institute for Neuroscience

Takakazu Ushioda
Department of Radiology
Ashikaga Red Cross Hospital
Tochigi

Noriyuki Ohtsuki
Department of Pediatrics
Yokohama City University School of Medicine

Akio Hasegawa
Department of Pathology and Laboratory Medicine
Odawara Municipal Hospital
Kanagawa

Japan

Reference

1. Fishman RA. *Cerebrospinal Fluid in Diseases of the Nervous System*. Philadelphia, Pa: WB Saunders; 1980:300–301

Gloves and Memos

I enjoyed the historical contribution on the Stockholm School of neuroradiology (1) that our Editor, very appropriately, asked Lindgren and Greitz to prepare. A sure sign that a discipline has reached maturity is interest in its historical background.

As an ex-alumnus of the Stockholm School, the article brought back fond memories of the glorious time I spent at the Serafimer Hospital. I write this letter to comment on a "procedural custom" illustrated in Figures 3 and 4 in that article. Some of the readers may have noted that Dr Wickbom and Dr Sjögren, who are injecting air by lumbar puncture (in the Figure 3, from 1950), and Dr Greitz and the visiting American Dr Lasser, who are introducing a needle in the carotid artery (Figure 4, from 1955), wear no gloves. The reaction of the American readers has probably varied from indifference to puzzlement, surprise, and shock. I have been informed by Dr Greitz that for decades gloves have since been used in Sweden.

When I first arrived at the National Institutes of Health (in January 1958) as chief of the newly established Section of Neuroradiology, G. M. Shy, the distinguished NIH neurologist who had recruited and chosen me because of my Stockholm training (1949–1953), and M. Baldwin, the chief of neurosurgery, agreed without much discussion that I was to carry out all of the invasive neuroradiologic procedures (pneumoencephalography, carotid and vertebral arteriography, myelography). This was quite a contrast to my reception 5 years before in Boston, Mass (1953), where as a radiology resident I was not allowed even to touch a needle! The neurosurgeons simply ignored the radiologists, hence the neuroradiologic standards were pathetically low.

Getting back to my Bethesda beginnings, 1 or 2 weeks passed during which I carried out all the special neuroradiologic procedures "ad modum Sueciae," and in the process gained the confidence of the clinical associates. Then

one morning, I found in my mail a memorandum from Dr Baldwin, in which he tersely instructed me that during invasive procedures I was supposed to wear gloves. I remember that I accepted the "recommendation" with equanimity: after all, it made theoretical sense (although I have never seen a complication, such as local infection, meningitis, or sepsis, from the nonuse of gloves in invasive neuroradiologic procedures). I was, however, annoyed by the form of communication. Why a memo? Dr Baldwin's office was next to mine! I stormed into his office and asked for an explanation. Very calmly, he described the advantages of the "memo policy."

Since then, I have learned quite a lot about the memo. In fact, analogies could be drawn between gloves and memos. Both are intended to establish a protective barrier—against noxious microorganisms with the glove and against personal frictions with the memo. Human contacts have to be avoided. The impersonal, aseptic character of the memo may well be chosen as a squalid symbol of the times.

Using gloves, I found that carrying out vertebral angiograms (direct anterior cervical puncture) was somewhat more difficult.

Giovanni Di Chiro
Neuroimaging Branch
National Institutes of Health
Bethesda, Md

Reference

1. Lindgren G, Greitz T. The Stockholm school of neuroradiology. *AJNR Am J Neuroradiol* 1995;16:351–360