



Providing Choice & Value

Generic CT and MRI Contrast Agents



**FRESENIUS
KABI**

CONTACT REP

AJNR

Intracranial abnormalities in infants treated with extracorporeal membrane oxygenation: update on sonographic and CT findings.

D I Bulas, G A Taylor, R M O'Donnell, B L Short, C R Fitz and G Vezina

This information is current as of July 23, 2025.

AJNR Am J Neuroradiol 1996, 17 (2) 287-294
<http://www.ajnr.org/content/17/2/287>

Intracranial Abnormalities in Infants Treated with Extracorporeal Membrane Oxygenation: Update on Sonographic and CT Findings

Dorothy I. Bulas, George A. Taylor, Regina M. O'Donnell, Billie Lou Short, Charles R. Fitz, and Gilbert Vezina

PURPOSE: To determine the frequency of intracranial lesions in infants treated with extracorporeal membrane oxygenation (ECMO), to evaluate trends in frequency during an 8-year period, and to determine which infants are at highest risk for intracranial injury. **METHODS:** Daily sonograms were obtained in 386 infants during treatment with ECMO. Cranial CT scans were acquired after decannulation in 286 of 322 survivors. Abnormalities were classified as major or minor and hemorrhagic or nonhemorrhagic. Results were correlated with infant demographic data. **RESULTS:** Intracranial abnormalities were detected in 203 (52%) of the 386 infants; 73 (19%) hemorrhagic, 86 (22%) nonhemorrhagic, and 44 (11%) combined lesions. Eighty-two lesions (21%) were classified as major. Forty-six (94%) of 49 major hemorrhages were identified at sonography. CT contributed additional information in 73% of neonates with intracranial abnormalities, of which 17 were major lesions not identified at sonography. The frequency of intracranial hemorrhage was increased in infants who were septic or premature or weighed less than 2.5 kg. An increase in time spent on ECMO bypass increased the risk for nonhemorrhagic injury. During an 8-year period, the frequency of hemorrhagic and major nonhemorrhagic lesions remained constant, whereas minor nonhemorrhagic abnormalities increased significantly. **CONCLUSION:** Infants treated with ECMO continue to be at high risk for cerebrovascular injury. Although daily sonograms are useful in identifying major hemorrhages, follow-up CT scans are crucial for accurate evaluation of intracranial abnormalities.

Index terms: Brain, injuries; Infants, newborn; Iatrogenic disease or disorder

AJNR Am J Neuroradiol 17:287-294, February 1996

Extracorporeal membrane oxygenation (ECMO) is a commonly used therapy for full- or near-term neonates in respiratory failure who are unresponsive to conventional medical management. Typically these infants are hypoxic, acidotic, and hypotensive before ECMO therapy and thus are at risk for cerebrovascular injury (1-4). Ligation of the common carotid artery and jugular vein when ECMO catheters are placed results in significant alteration in cere-

bral blood flow, which increases the risk for intracranial infarction (5-7). The use of systemic heparin for the prevention of clot formation within the circuit places the infants at higher risk for intracranial hemorrhage as well.

In the early days of ECMO therapy it became apparent that premature infants were at highest risk for intracranial hemorrhage (1, 8, 9). Most centers currently limit ECMO therapy to infants older than 33 weeks' gestational age who weigh more than 2 kg. Despite these restrictions, the reported frequency of cerebrovascular injury has ranged from 10% to 52% (1, 10-15). Cranial sonography is performed before the initiation of ECMO and then daily in the hopes of identifying hemorrhages early (9, 12, 16). Computed tomography (CT) has been found to be more sensitive than sonography in the identification of small or nonhemorrhagic abnormalities and is often performed in infants after decannulation (14, 15, 17). As centers become

Received May 15, 1995; accepted after revision August 8.

From the Department of Diagnostic Imaging and Radiology (D.I.B., G.A.T., C.R.F., G.V.), the Children's Research Institute (R.M.O.), and the Department of Neonatology (B.L.S.), Children's National Medical Center, Washington, DC, and the George Washington School of Medicine and Health Sciences, Washington, DC (D.I.B., G.A.T., B.L.S., C.R.F., G.V.).

Address reprint requests to Dorothy I. Bulas, MD, Department of Diagnostic Imaging and Radiology, Children's National Medical Center, 111 Michigan Ave NW, Washington, DC 20010.

AJNR 17:287-294, Feb 1996 0195-6108/96/1702-0287

© American Society of Neuroradiology

more experienced in the use of ECMO and use it to treat sicker infants, the number of intracranial abnormalities that occur may change. Alterations in therapy, including decreasing the amount of heparin used, may reduce the risk of hemorrhage. We reviewed our experience with a large population of ECMO patients to determine whether the frequency of associated lesions has changed over an 8-year period. In addition, we attempted to identify which infants are at highest risk for intracranial injury.

Materials and Methods

During an 8-year period, 388 infants were treated with venoarterial ECMO for severe cardiorespiratory failure unresponsive to maximum conventional therapy. Two infants died before sonograms could be obtained and were excluded from this series. All infants met entry criteria for ECMO: birth weight greater than 2 kg, gestational age greater than 33 weeks, reversible form of cardiopulmonary failure, absence of significant intracranial hemorrhage, and absence of irreparable life-limiting congenital malformations (18). All infants underwent venoarterial bypass via the common carotid artery and jugular vein, which were permanently ligated during the cannulation procedure.

Demographic data including birth weight, sex, gestational age, Apgar scores, hours on ECMO, diagnosis, clotting studies (prothrombin time/partial thromboplastin time), and electroencephalography results were documented. Table 1 lists the perinatal data for these infants.

Cranial sonograms were obtained in 386 infants immediately before cannulation and then daily during extracorporeal therapy. Standard coronal and sagittal images were obtained via the anterior fontanelle using a 5-MHz sector and/or 7.5-MHz linear transducer (Acuson 128, Mountain View, Calif). In all cases, sonography was performed by experienced pediatric sonographers and reviewed by a pediatric radiologist.

Two hundred eighty-six (89%) of the 322 survivors had noncontrast cranial CT scans within 3 weeks of discontinuation of ECMO. CT scans were obtained on a GE 9800 scanner (General Electric, Milwaukee, Wis) at 5-mm intervals with 5-mm-thick sections. All CT scans were reviewed

by a pediatric radiologist and a pediatric neuroradiologist. Of 66 neonates who died while undergoing ECMO, neuropathology was available in 28 (42%). Of the 286 infants in whom both CT and sonographic studies were performed, results of the two techniques were compared with regard to number and type of abnormalities identified.

Neuroimaging findings were classified as hemorrhagic or nonhemorrhagic abnormalities by a method described previously by Taylor et al (14). Minor hemorrhagic abnormalities included small extraaxial hemorrhage, small parenchymal hemorrhage (≤ 1 cm) (Fig 1), and grade 1 or 2 intraventricular hemorrhage. All other hemorrhages were categorized as major (Figs 2 and 3). Minor nonhemorrhagic abnormalities included widened interhemispheric fissure, prominent subarachnoid space, mild ventriculomegaly, focal area of low attenuation, and focal atrophy. All other nonhemorrhagic abnormalities—including diffuse periventricular hypodensity, generalized atrophy, and large infarcts—were categorized as major (Fig 4). If a patient had both hemorrhagic and nonhemorrhagic abnormalities, these were categorized as combined abnormalities and graded minor only if both lesions were minor. Location of lesions, pattern of distribution, and combined hemorrhagic/nonhemorrhagic lesions were noted. All CT and sonographic studies were reviewed and discrepancies between the two techniques noted. Interobserver variability was evaluated in a previous report by this group, in which a good measure of agreement was found among raters (19).

Statistical Analysis

Patients were grouped into the following categories for evaluation: primary pulmonary diagnosis, severity and type of intracranial abnormality, birth weight (<2500 g versus ≥ 2500 g), and survival. Continuous dependent variables were assessed by analysis of variance for pulmonary diagnosis and intracranial abnormality. Specific pairwise differences of intracranial lesions versus gestational age and diagnosis versus hours on ECMO were determined by using the Newman-Keuls multiple-range test. Student's *t* test was used to evaluate differences caused by birth-weight grouping or survival. The frequency distribution of categorical variables was compared between groups using Pearson χ^2 analysis.

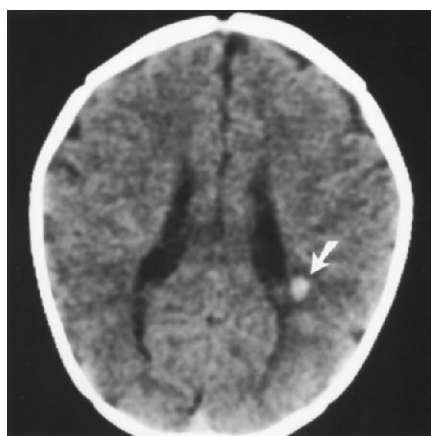
Because there was some variation in patient population and ECMO therapy over the last 8 years (including a more conservative use of heparin currently), a linear trend of χ^2 analysis was performed on consecutive groups of 50 infants. Diagnosis, birth weight, Apgar scores, length of time on ECMO, and intracranial abnormalities were compared between the groups. Statistical significance for each test was considered only for probability levels less than .05.

Results

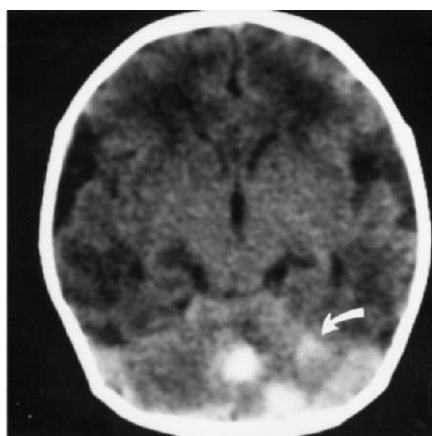
Intracranial abnormalities were detected in 203 (52%) of 386 neonates studied with sonog-

TABLE 1: Perinatal data for 388 infants treated with ECMO

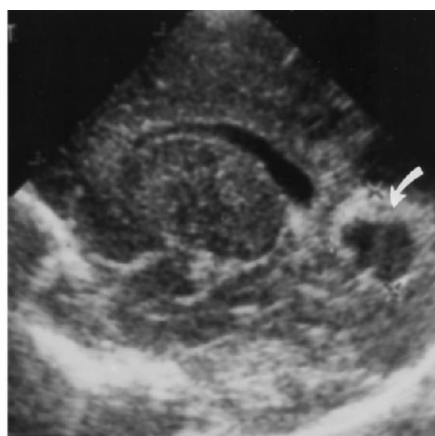
Primary diagnosis	No. of subjects (%)
Meconium aspiration syndrome	166 (43)
Congenital diaphragmatic hernia	57 (15)
Sepsis	52 (13)
Persistent pulmonary hypertension	53 (14)
Respiratory distress syndrome	42 (11)
Other	18 (4)
Mean gestational age	39 wk (range, 33–44 wk)
Mean birth weight	3.2 kg (range, 2–6.2 kg)
Mean duration of ECMO therapy	147 h (range, 0.5–608 h)



1



2



3

Fig 1. Infant placed on ECMO for congenital diaphragmatic hernia. Findings on cranial sonograms (*not shown*), obtained while the patient was on ECMO, were interpreted as normal. This follow-up CT scan shows a small left-sided periventricular hemorrhage (*arrow*).

Fig 2. Eleven-day-old infant treated with ECMO for sepsis. Findings on sonograms (*not shown*), obtained while the patient was on ECMO, were interpreted as normal. This CT scan shows left-sided cerebellar hemorrhages (*arrow*).

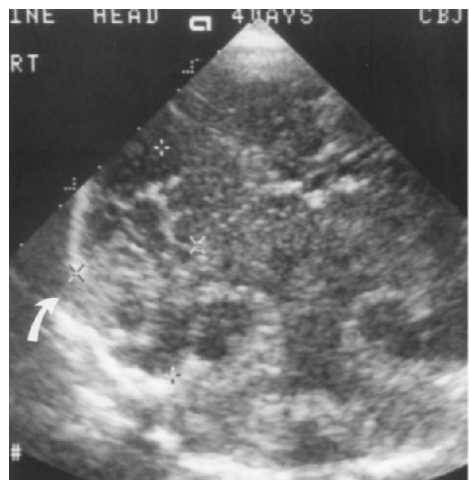Fig 3. Infant placed on ECMO for a congenital diaphragmatic hernia. Sonogram obtained at 10 days of age shows a 2-cm hypoechoic lesion in the right occipital lobe with surrounding hyperechoic margins consistent with a hemorrhage (*arrow*). The infant died of progressive hypoxemia and autopsy confirmed the presence of a right-sided occipital hemorrhage.

raphy and/or CT. Table 2 provides a breakdown of hemorrhagic and nonhemorrhagic abnormalities.

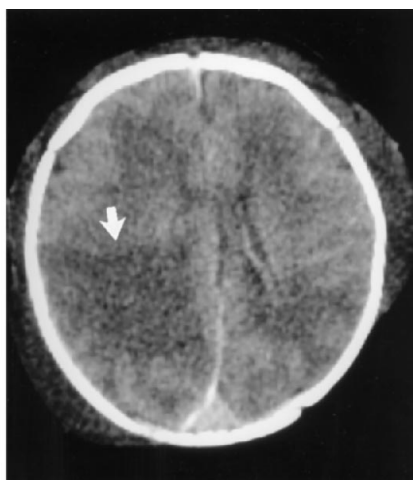
A total of 117 patients (30%) had sonographic and/or CT evidence of intracranial hemorrhage; 49 major, 68 minor. Seventy-five (64%) of the 117 hemorrhages were located in the parenchyma and 32 (27%) originated within the germinal matrix or ventricles (Table 3). The most common site of parenchymal hemorrhages was the cerebellum, with 14 (27%) (Fig 2). Extraaxial hemorrhages were rare (8.5%)

and typically small, with only one subdural hemorrhage resulting in significant mass effect.

One hundred thirty infants (34%) had nonhemorrhagic abnormalities; 50 major, 80 minor. Major nonhemorrhagic abnormalities included periventricular leukomalacia or hypodensity ($n = 27$), infarction ($n = 17$), and atrophy ($n = 6$). Only one patient had a markedly enlarged subarachnoid space (Fig 5). Although 37 infants had evidence of mild to moderate ventricular dilatation, only three required long-term ventriculoperitoneal shunts. The



A



B

Fig 4. Infant placed on ECMO for sepsis.

A, Coronal sonogram at 2 days of age shows a heterogeneous echogenic region in the right temporooccipital lobe (*arrow*).

B, CT scan at 4 days of age confirms the presence of a right-sided occipital infarct (*arrow*) with compression and shift of the right lateral ventricle.

TABLE 2: Major versus minor intracranial abnormalities in 386 infants treated with ECMO

	Hemorrhagic, n (%)	Nonhemorrhagic, n (%)	Combined, n (%)	Total, n (%)
Major	29 (8)	22 (6)	31 (8)	82 (21)
Minor	44 (11)	64 (16)	13 (3)	121 (31)
Total	73 (19)	86 (22)	44 (11)	203 (52)

most common mild nonhemorrhagic finding was focal widening of the interhemispheric fissure (11%).

No right- or left-sided lateralization was noted with respect to hemorrhagic or nonhemorrhagic lesions. Of 86 isolated nonhemorrhagic lesions, eight were right-sided, nine were left-sided, and 69 were bilateral. Of 73 isolated hemorrhagic lesions, 22 were on the right side, 18 were on the left side, and 33 were bilateral. No right- or left-sided predilection was noted in infants who had combined hemorrhagic and nonhemorrhagic lesions.

Risk Factors

Infants with low birth weight had a statistically significant higher frequency of hemorrhagic or

combined hemorrhagic/nonhemorrhagic abnormalities ($P = .006$). Infants weighing less than 2500 g had a 42% risk of an intracranial hemorrhage developing whereas infants weighing 2500 g or greater had a 30% risk. Of 49 infants with major intracranial hemorrhage, 69% weighed less than 3 kg. Conversely, 70% of infants in whom a major nonhemorrhagic lesion developed weighed more than 3 kg.

Infants in whom intracranial hemorrhage developed were significantly younger in gestational age (38.2 ± 2.5 weeks) than infants who had nonhemorrhagic abnormalities (39.4 ± 1.9 weeks) or infants whose neuroradiographic findings were normal (39.2 ± 2.34) ($P = .006$).

Infants with sepsis were at highest risk for intracranial hemorrhages as compared with infants who had other abnormalities (33% versus 17%; $P < .05$).

The average time on ECMO for all infants was 147 hours, with those treated for congenital diaphragmatic hernia having the longest ECMO runs with a mean circuit time of 217 hours ($P = .0001$). Infants with major hemorrhagic lesions were on ECMO bypass the shortest time (mean, 114 hours; $P = .05$), most likely owing to the attempts to remove these infants from ECMO as quickly as possible once the hemorrhage was identified. Infants with major nonhemorrhagic lesions were on ECMO bypass the longest, with a mean circuit run of 186 hours. The risk of a nonhemorrhagic injury developing was significantly increased the longer an infant was on ECMO ($P < .05$). Infants with diaphragmatic hernia were typically on ECMO the longest and had a 25% risk of developing a nonhemorrhagic injury.

A χ^2 analysis of consecutive groups of 50 infants treated with ECMO in our institution over the last 8 years demonstrated a statistically significant linear trend in the number of infants with congenital diaphragmatic hernia. Initially, congenital diaphragmatic hernias accounted for 7% of the ECMO population but increased to 20% by 1992. There was a significant increase in the number of minor nonhemorrhagic abnormali-

TABLE 3: Intracranial abnormalities in 386 infants treated with ECMO

Type of Lesion	n
Hemorrhages	
Large parenchymal (>10 mm)	34
Small parenchymal (2–10 mm)	18
Petechial (<2 mm)	23
Subependymal	23
Intraventricular	9
Subarachnoid	4
Subdural	6
Total	117*
Nonhemorrhagic abnormalities	
Hypodensity/periventricular leucomalacia	
Focal	16
Patchy	10
Diffuse	10
Atrophy	
Mild	17
Moderate	6
Infarct	17
Wide interhemispheric fissure	42**
Prominent subarachnoid space	12
Ventriculomegaly	37**
Sagittal sinus thrombosis	1
Dermoid	1
Total	130*

* 44 infants with combined hemorrhagic and nonhemorrhagic lesions.

** Infants with more than one nonhemorrhagic abnormality.

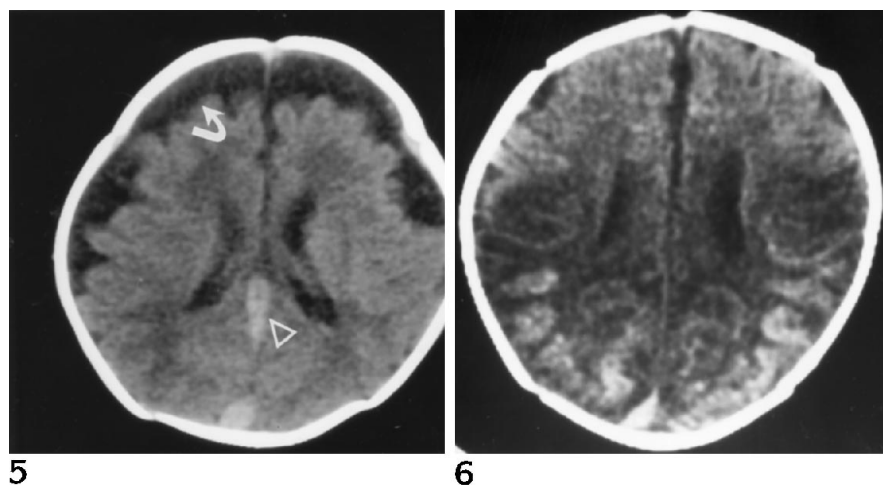


Fig 5. Infant with a congenital diaphragmatic hernia in whom superior vena cava thrombosis developed during ECMO treatment. CT scan at 6 weeks of age shows large bilateral extraaxial fluid collections (arrow). The straight sinus (arrowhead) is dilated, suggestive of venous hypertension.

Fig 6. Ten-day-old infant treated with ECMO for meconium aspiration. CT scan shows bilateral occipitoparietal hemorrhagic infarcts. Findings on cranial sonograms (not shown), obtained while the patient was on ECMO, were interpreted as normal.

ties identified radiographically over the same time period ($P < .0001$). The frequency of widened interhemispheric fissures increased from 11% to 24% over the last 3 years. The rate of hemorrhagic and major nonhemorrhagic lesions, however, remained constant. Over the same period, the amount of heparin used in the bypass circuit has decreased in our institution.

There was no statistically significant difference in number or type of intracranial abnormality as related to sex, Apgar scores, and initial levels of prothrombin time/partial thromboplastin time.

Intracranial Injury versus Survival

Sixty-six infants who were placed on ECMO died (17%). Of 82 infants with major intracranial abnormalities, 35 (43%) died. Infants with major hemorrhages had the highest mortality rate with 29 (59%) of 49 dying (Table 4).

Sonography versus CT

Two hundred eighty-six infants had CT scans within 3 weeks of the last cranial sonogram. Sonograms obtained before discontinuation of ECMO showed abnormal findings in 62 of these infants, whereas CT scans obtained after decannulation showed abnormal findings in 145 of these infants. Nine intracranial abnormalities noted on sonograms were not documented on follow-up CT scans, including four subependymal hemorrhages, three widened interhemispheric fissures, and two focal periventricular hyperechogenic regions. Of 145 infants with abnormal findings on CT scans, 53 (36%) were

noted to have abnormal sonographic findings before decannulation. Follow-up CT scans provided additional information in 106 (73%) of the neonates with intracranial abnormalities (Table 5). Although the majority of abnormalities missed by sonography were classified as minor, 17 infants had major abnormalities detected only by CT, including large parenchymal hemorrhages (three), infarcts (six) (Fig 6), diffuse periventricular hypodensities (three), and moderate atrophy (five).

In 100 infants, only cranial sonograms were obtained. Of these, 53 were classified as having normal findings. Of the 47 abnormal sonographic findings, 38 were counted as having hemorrhagic abnormalities and 9 as nonhemorrhagic abnormalities. Thirty-two of the 47 infants with abnormal findings died; 13 of these had autopsies. In all 13, major hemorrhages were diagnosed at sonography and were confirmed at autopsy.

Discussion

ECMO has been shown to reduce mortality in selected neonatal respiratory diseases (18).

TABLE 4: Frequency of intracranial abnormalities in survivors versus nonsurvivors

	322 Survivors, n (%)	66 Nonsurvivors, n (%)
All hemorrhagic	81 (25)	36 (55)
Major	20 (6)	29 (44)
Minor	61 (19)	7 (11)
All nonhemorrhagic	110 (34)	20 (30)
Major	36 (11)	14 (21)
Minor	74 (23)	6 (9)

TABLE 5: Distribution of abnormalities detected only on follow-up CT scans in 106 infants

Hemorrhages	
Petechial (<2 mm)	17
Small parenchymal (2–10 mm)	7
Large parenchymal (>10 mm)	3
Subarachnoid hemorrhage	4
Subdural hemorrhage	3
Intraventricular hemorrhage	2
Total	36
Nonhemorrhagic abnormalities	
Atrophy	
Moderate	5
Mild	10
Hypodensity/periventricular leucomalacia	
Patchy	13
Diffuse	3
Infarct	6
Wide interhemispheric fissure	25
Extraaxial fluid	6
Sagittal sinus thrombosis	1
Ventriculomegaly	1
Total	70

However, the morbidity of this therapy, specifically intracranial injury, continues to be of concern. The reported frequency of intracranial injury has ranged from 10% to 52% (10–15). The wide variation in frequency among centers is in part the result of differences in patient population and ECMO technique. In addition, neuroimaging techniques and methods of classifying abnormalities have been variable, with several papers reporting only sonographic findings or only major intracranial abnormalities (1, 10, 12, 16). Thus, while our reported 52% frequency of intracranial lesions falls into the high end of the spectrum, only 21% of lesions were classified as major, which falls into the middle range of other series.

Several factors appear to increase the risk of intracranial injury in infants undergoing ECMO. All candidates for ECMO have suffered from hypoxemia and acidosis, many with evidence of vasomotor shock. Hypercarbia, volume expansion, pneumothoraces, and blood pressure fluctuations all alter cerebral blood flow (1, 2). Arterioles that are already maximally dilated may, in the presence of impaired autoregulation, rupture because of increased blood flow pressure (5, 6). After unilateral carotid ligation, infants on ventilatory support have been noted to have decreased cerebral blood flow (5). While several small series have reported an increased rate of infarcts on the same side of carotid ligation

and hemorrhages on the side opposite the carotid ligation, this was not noted in our series (11, 20, 21). Abnormal venous drainage resulting from jugular vein ligation has also been implicated as a cause of cerebrovascular injury subsequent to stasis within periventricular medullary veins (7).

Previous investigators who have noted a high risk of intracranial hemorrhage among premature infants on ECMO have believed this risk to be due to the existing friable germinal matrix (1, 10). Despite the exclusion of small premature infants in our series, the frequency of intracranial hemorrhage remained high. Younger infants continued to have a statistically significant increased risk of hemorrhage despite the fact that the mean age of these infants was 38 weeks and that only 27% of the hemorrhages originated in the germinal matrix. Infants at highest risk for intracranial hemorrhage were those treated for sepsis, most likely because of additional problems with coagulopathy (22).

Although regions of ischemia are at risk for hemorrhage, particularly when heparin is being used, infarcts in term infants weighing over 3 kg typically did not progress to hemorrhages. Infants with long circuit runs, particularly those with congenital diaphragmatic hernia, had the highest rate of major nonhemorrhagic lesions, yet the frequency of intracranial hemorrhage in this group of infants has not increased.

The frequency of widened interhemispheric fissures increased from 11% to 24% over the last 3 years. Other authors have commented on this particular finding in infants on ECMO, with rates of occurrence ranging from 5% to 59% (16, 17, 23). Rubin et al (23) believed this dilatation was an intracranial manifestation of generalized edema. Other authors (7, 24) have suggested that increased sagittal sinus pressure associated with internal jugular vein ligation and cannulation of the superior vena cava decreases cerebrospinal fluid resorption of the arachnoid villi. Subarachnoid space enlargement has been striking in infants on venovenous ECMO in whom a double lumen tube is placed into the right internal jugular vein and superior vena cava (25). In our series, a markedly widened extraaxial space developed in an infant with superior vena cava thrombosis, suggesting that venous hypertension plays a role in the development of this abnormality (Fig 3).

The number of infants with interhemispheric fissure dilatation as well as other minor non-

hemorrhagic abnormalities has increased over the past 3 years. This may in part be the result of a more conservative use of heparin, which increases the risk of partial venous occlusion and microemboli (26). The larger number of infants with congenital diaphragmatic hernia currently being treated in our institution may also be causing an increase in minor nonhemorrhagic abnormalities, as their longer mean circuit runs increase the potential for partial venous occlusion.

Although sonography remains a cornerstone in the intracranial screening of ECMO patients, follow-up CT scans provided additional information in 73% of neonates documented to have an abnormality by means of CT study. Generalized edema, infarcts, small parenchyma, and extraaxial hemorrhages were either not present when sonography was performed or not visible sonographically. In addition, sonographic distinction between hemorrhagic and ischemic lesions was at times difficult, as both can be echogenic. The percentage of lesions missed may in fact be higher, as 53 infants with reportedly normal sonographic findings did not have follow-up CT. With cranial CT usually performed several days after the last sonogram, it is possible that some lesions were not present when the sonograms were obtained. Previous studies that correlated sonographic with CT and neuropathologic findings, however, have also documented abnormalities missed by sonography in 53% to 93% of patients (24, 27, 28). CT was most useful in identifying infarcts, diffuse edema, and atrophy in infants with normal-appearing sonograms. Sonography, however, successfully identified 46 (94%) of 49 major intracranial hemorrhages, lesions that most affect the way the infant is managed acutely. Early screening with sonography may also be useful in identifying infants with severe edema. Von Allmen et al (29) noted that infants with evidence of severe edema on pre-ECMO sonograms had a 63% rate of occurrence of subsequent major intracranial complications. Thus, although sonography may miss many lesions, it remains a useful screening examination for infants who are on ECMO. CT or magnetic resonance imaging, however, should be performed once the infant is stable for more accurate evaluation of nonhemorrhagic and minor hemorrhagic lesions (13).

Despite alterations in ECMO therapy, intracranial injuries remain a serious problem in ne-

onates treated with this method. Patients with low birth weight, prematurity, and sepsis are at highest risk for intracranial hemorrhage, whereas infants on bypass for prolonged periods are at highest risk for nonhemorrhagic injury. Serial sonograms should be obtained while the patient is on ECMO to determine whether a major intracranial hemorrhage has developed. However, follow-up CT scans are important for accurate evaluation of intracranial abnormalities, particularly nonhemorrhagic lesions.

References

1. Cilley RE, Zwischenberger JB, Andrews AF, Bowerman RA, Roloff DW, Bartlett RH. Intracranial hemorrhage during extracorporeal membrane oxygenation in neonates. *Pediatrics* 1986;78:699-704
2. Volpe JJ. Neonatal intraventricular hemorrhage. *N Engl J Med* 1981;304:886-891
3. Lou HC, Skow H, Pedersen H. Low cerebral blood flow: a risk factor in the neonate. *J Pediatr* 1979;95:606-609
4. McPhee AF, Kotagal UR, Kleinman LI. Cerebrovascular dynamics during and after recovery from acute asphyxia in the newborn dog. *Pediatr Res* 1985;19:645-650
5. Short BL, Walker LK, Gleason CA, Jones MD, Traystman RJ. Effects of extracorporeal membrane oxygenation on cerebral blood flow and oxygenation consumption in the newborn. *Pediatr Res* 1988;21:425
6. Short BL, Walker LK, Bender KS, Traystman RJ. Impairment of cerebral autoregulation during extracorporeal membrane oxygenation in newborn lambs. *Pediatr Res* 1993;33:289-294
7. Taylor GA, Walker LK. Intracranial venous system in newborns treated with extracorporeal membrane oxygenation: Doppler US evaluation after ligation of the right jugular vein. *Radiology* 1992;183:453-456
8. Bartlett RH, Andrews AF, Toomasian JM, Haiduc NJ, Gazzaniga AB. Extracorporeal membrane oxygenation for newborn respiratory failure: forty-five cases. *Surgery* 1982;92:425-433
9. Bowerman RA, Zwischenberger JB, Andrews AF, Bartlett RH. Cranial sonography of the infant treated with ECMO. *AJR Am J Roentgenol* 1985;145:161-166
10. Sell LL, Cullen ML, Whittlesey, et al. Hemorrhagic complications during extracorporeal membrane oxygenation: prevention and treatment. *J Pediatr Surg* 1986;21:1087-1091
11. Schumacher RE, Barks JDE, Johnston MV, et al. Right sided lesions in infants following extracorporeal membrane oxygenation. *Pediatrics* 1988;82:155-161
12. Luisiri A, Gravis ER, Weber T, et al. Neurosonographic changes in newborns treated with extracorporeal membrane oxygenation. *J Ultrasound Med* 1988;7:429-438
13. Wiznitzer M, Masaryk TJ, Lewin J, Walsh M, Stork IK. Vascular magnetic resonance imaging of the brain in infants on extracorporeal membrane oxygenation. *Am J Dis Child* 1990;144:1323-1326
14. Taylor GA, Fitz CR, Miller MK, Garin DB, Catena LM, Short BL. Intracranial abnormalities in infants treated with extracorporeal membrane oxygenation: imaging with US and CT. *Radiology* 1987;165:675-678
15. Taylor GA, Short BL, Fitz CR. Imaging of cerebrovascular injury in infants treated with extracorporeal membrane oxygenation. *J Pediatr* 1989;114:635-639

16. Canady AI, Fessler RD, Klein MD. Ultrasound abnormalities in term infants on extracorporeal membrane oxygenation. *Pediatr Neurosurg* 1993;19:202-205
17. Babcock DS, Han BK, Wiess RG, Ryckman FC. Brain abnormalities in infants on extracorporeal membrane oxygenation: sonographic and CT findings. *AJR Am J Roentgenol* 1989;153:571-576
18. Beck R, Anderson KD, Pearson GD, Garin J, Miller MK, Short BL. Criteria for extracorporeal membrane oxygenation in population of infants with PPHN. *J Pediatr Surg* 1986;21:297-302
19. Bulas D, Glass P, O'Donnell RM, Taylor GA, Short BL, Vezina GL. Neonates treated with ECMO: predictive value of early CT and US neuroimaging findings on short-term neurodevelopmental outcome. *Radiology* 1995;195:407-412
20. Mendoza JC, Shearer LS, Cood LN. Lateralization of brain lesions following extracorporeal membrane oxygenation. *Pediatrics* 1991;88:1004-1009
21. Hahn JS, Vaucher Y, Bejar R, Coen RW. Electroencephalographic and neuroimaging findings in neonates undergoing extracorporeal membrane oxygenation. *Neuropediatrics* 1992;24:19-24
22. Zimmerman JJ, Deitrich KA. Current perspectives on septic shock. *Pediatr Clin North Am* 1987;43:131-138
23. Rubin DA, Gross GW, Ehrlich SM, Alexander AA. Interhemispheric fissure width in neonates on extracorporeal membrane oxygenation. *Pediatr Radiol* 1990;21:12-15
24. Matamoros A, Anderson JC, McConnell J, Bolam DL. Neurosonographic findings in infants treated by extracorporeal membrane oxygenation. *J Child Neurol* 1989;4:S52-S61
25. Brunberg JA, Kewitz G, Schumacher RE. Venovenous ECMO: early CT alterations following use in management of severe respiratory failure in neonates. *AJNR Am J Neuroradiol* 1993;14:595-603
26. Fink SM, Bockman DE, Howell CG, Falls DG, Kanto W. Bypass circuits as the source of thromboemboli during extracorporeal membrane oxygenation. *J Pediatr* 1989;115:621-624
27. Silverboard G, Horder MH, Ahmen PA, Lazzara A, Scheartz JF. Reliability of ultrasound in diagnosis of intracerebral hemorrhage and posthemorrhagic hydrocephalus: comparison with CT. *Pediatrics* 1980;66:507-514
28. Armstrong DL, Sauls CD, Goddard-Finegold J. Neuropathologic findings in short term survivors of intraventricular hemorrhage. *Am J Dis Child* 1987;141:617-621
29. von Allmen D, Babcock D, Matsumoto J, et al. The predictive value of head ultrasound in the extracorporeal membrane oxygenation candidate. *J Pediatr Surg* 1992;27:36-40