



## Get Clarity On Generics

Cost-Effective CT & MRI Contrast Agents



FRESENIUS  
KABI

WATCH VIDEO

# AJNR

## Coexistence of schizencephaly and intracranial arteriovenous malformation in an infant.

P C Hung, H S Wang, Y S Yeh, T N Lui and S T Lee

*AJNR Am J Neuroradiol* 1996, 17 (10) 1921-1922

<http://www.ajnr.org/content/17/10/1921>

This information is current as  
of August 29, 2025.

---

# Coexistence of Schizencephaly and Intracranial Arteriovenous Malformation in an Infant

Po-Cheng Hung, Huei-Shyong Wang, Yi-Shian Yeh, Tai-Ngar Lui, and Shih-Tseng Lee

**Summary:** A 9-month-old infant had unilateral closed-lip schizencephaly in the right parietal lobe, which coexisted with an arteriovenous malformation in the nearby temporal area. Cranial MR showed a right parietal cleft lined with gray matter between the right lateral ventricle and the subarachnoid space, and cluster hypointensities throughout the right temporal lobe. Cerebral angiography revealed a right temporal arteriovenous malformation with feeding arteries arising from the right middle and posterior cerebral arteries and draining into the right sigmoid sinus via the engorged vein of Labbé.

**Index terms:** Migration anomalies; Arteriovenous malformations, intracranial

We describe a patient with definite schizencephaly and symptomatic intracranial arteriovenous malformation (AVM) disclosed by clinical and neuroimaging studies.

## Case Report

A 9-month-old right-handed boy was referred to our hospital because of progressive weakness of the left limbs for a period of 2 to 3 months. The prenatal and perinatal courses were uneventful; developmental milestones were mildly delayed. On examination, the head circumference was 44.2 cm (30th percentile), height was 70 cm (30th percentile), and weight was 8.6 kg (25th percentile). The anterior fontanel was flat; the face had no dysmorphic features; the pupils reacted to light equally; and the optic fundi showed no abnormality. The patient was noted to have wasting of the right side of the face and left arm and leg, associated with a spastic left hemiparesis. Tendon jerk on the left side was hyperactive, and a left-sided toe sign was noted. The general physical examination was otherwise unremarkable.

Analysis of urine and serum amino acids was unremarkable. The chromosome study was 46,XY. Cranial magnetic resonance (MR) findings showed a right parietal cleft lined with gray matter (Fig 1A) communicating between the right lateral ventricle and the subarachnoid

space, and cluster hypointensities throughout the right temporal area (Fig 1B). Cerebral angiography revealed a right temporal AVM with feeding arteries arising from the right middle and posterior cerebral arteries and draining into the right sigmoid sinus via the engorged vein of Labbé (Fig 1C).

The AVM was excised 3 days later through a right temporal craniotomy. When the dura was opened, the brain was found to be quite swollen, and the AVM was seen to occupy the right temporal area. Multiple small feeders from the middle and posterior cerebral arteries met in the posteroinferior margin of the AVM. All the feeders were ligated. Histologic examination revealed numerous arteries and veins of various sizes. The patient's left-sided hemiparesis improved after postoperative rehabilitation.

## Discussion

Schizencephaly is a rare congenital brain malformation. Yakovlev and Wadsworth (1, 2) described this disorder as hemispheric clefts in the region of the primary fissures, infolding of gray matter along the clefts, and associated cerebral malformations, including ventriculomegaly, polymicrogyria, heterotopias, agenesis of the corpus callosum, and absence of the septum pellucidum.

The pathogenesis of schizencephaly is still unknown. One hypothesis is based on vascular compromise during early neuroembryogenesis (3). Normally, the migration of neuroblasts from the germinal matrix outward to the cerebral cortex occurs during the 4th to 16th weeks of gestation. A smaller wave of migration continues until the 25th gestational week. If an ischemic event were to occur in the watershed zone, including the germinal matrix, neuroblast migration might not take place. As a result of such damage, neural tissue may be absent in various

---

Received September 28, 1995; accepted after revision January 25, 1996.

From the Departments of Pediatrics (P-C.H., H-S.W.) and Neurosurgery (Y-S.Y., T-N.L., S-T.L.), Chang Gung Medical College and Chang Gung Children's Hospital at Linkou, Taiwan.

Address reprint requests to Po-Cheng Hung, MD, Department of Pediatrics, Chang Gung Memorial Hospital, 199, Tung-Hwa North Road, Taipei, 105 Taiwan, Republic of China.

AJNR 17:1921-1922, Nov 1996 0195-6108/96/1710-1921 © American Society of Neuroradiology

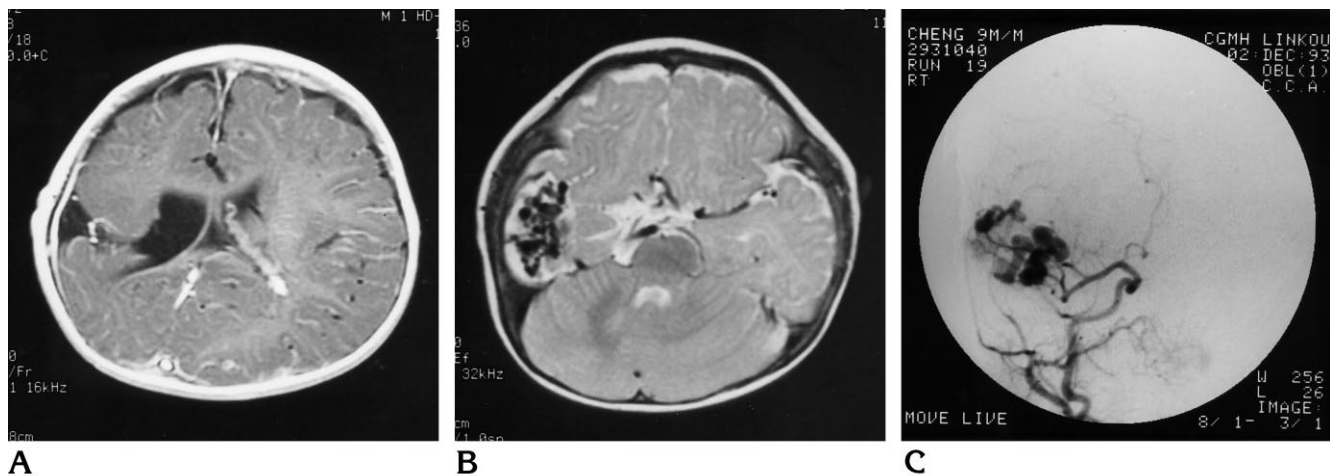


Fig 1. Nine-month-old boy with coexisting schizencephaly and intracranial AVM.

A, Schizencephaly. Axial contrast-enhanced T1-weighted MR image shows a right parietal cleft with communication between the right lateral ventricle and the subarachnoid space.

B, AVM. Axial T2-weighted MR image shows cluster hypointensities throughout the right temporal area.

C, Right carotid cerebral angiogram, oblique view, shows abnormal vasculature in the temporal region. The AVM was supplied by the anterior and posterior branches of the right middle and posterior cerebral arteries.

degrees. Thus, the severity of ischemia determines the size of the clefts. This theory supports the facts that all cases of schizencephaly are not alike and that the clefts are all lined with gray matter. The other considered hypothesis is based on a primary dysgenesis of the embryonic pyramidal tracts (4).

Matson (5) declared that AVMs are the "most frequent abnormality of the intracranial circulation in childhood." They are usually congenital lesions that arise from abnormal development of the arteriolar-capillary network, which exists between the arterial and venous circulations within the organ. The stimulus, timing, and early architectural deficiencies in the AVM are not clear. It is believed that the malformations occur before the embryo is 44 mm in length, at about the eighth to ninth week of gestation (6). Van der Knaap and Valk (7) also suggested that AVMs arise at a specific stage of embryogenesis, and they related this stage to the development of schizencephaly.

Since schizencephaly and AVMs are both rare in infants, their coexistence in a single patient may suggest a relationship between the two lesions. We speculate that the potential for vascular compromise due to AVMs during early

neuroembryogenesis could result in schizencephaly.

### Acknowledgment

We are grateful for the assistance of Su-Ching Wu, who prepared our manuscript cautiously and patiently.

### References

1. Yakovlev PI, Wadsworth RC. Schizencephalies: a study of the congenital clefts in the cerebral mantle, I: clefts with fused lips. *J Neuropathol Exp Neurol* 1946;5:116-130
2. Yakovlev PI, Wadsworth RC. Schizencephalies: a study of the congenital clefts in the cerebral mantle, II: clefts with hydrocephalus and lips separated. *J Neuropathol Exp Neurol* 1946;5:169-206
3. Komarniski CA, Cyr DR, Mack LA, Weinberger E. Prenatal diagnosis of schizencephaly. *J Ultrasound Med* 1990;9:304-307
4. Bubis JJ, Landau WM. Agenesis of pyramidal tracts associated with schizencephalic clefts in rolandic cortex. *Neurology* 1964;14:821-824
5. Matson DD. Arteriovenous malformation. In: *Neurosurgery of Infancy and Childhood*. 2nd ed. Springfield, Ill: Charles C Thomas; 1969:749-766
6. Padget DH. The cranial venous system in man in reference to development, adult configuration and relation to the arteries. *Am J Anat* 1956;98:307-340
7. Van der Knaap MS, Valk J. Classification of congenital abnormalities of the CNS. *AJNR Am J Neuroradiol* 1988;9:315-326