



## Discover Generics

Cost-Effective CT & MRI Contrast Agents



FRESENIUS  
KABI

[VIEW CATALOG](#)

# AJNR

### **Low-grade adenocarcinoma of probable endolymphatic sac origin: CT and MR appearance.**

V T Ho, V M Rao, H T Doan and D O Mikaelian

*AJNR Am J Neuroradiol* 1996, 17 (1) 168-170

<http://www.ajnr.org/content/17/1/168>

This information is current as  
of September 2, 2025.

---

# Low-Grade Adenocarcinoma of Probable Endolymphatic Sac Origin: CT and MR Appearance

Van Thong Ho, Vijay M. Rao, Huynh T. Doan, and Diran O. Mikaelian

**Summary:** The CT and MR appearance of a case of low-grade adenocarcinoma of probable endolymphatic sac origin is presented. The tumor destroyed a large part of the posterior temporal bone and showed prominent extension into the posterior cranial fossa.

**Index terms:** Carcinoma; Temporal bone, neoplasms

Primary adenocarcinomas of the temporal bone are rare. In this study, we describe a case of low-grade adenocarcinoma probably arising from the endolymphatic sac.

## Case Report

A 22-year-old black woman with slight mental retardation presented with new onset of generalized seizure disorder. General physical findings were normal except for impaired hearing on the left side. The patient reported having decreased hearing in her left ear for approximately 1 year, but denied vertigo, tinnitus, otalgia, and otorrhea. Further examination of her left ear revealed a reddish mass in the mesotympanum, bulging the intact tympanic membrane outward. Audiometric evaluation showed a mild to moderate conductive hearing loss with a type B (flat) tympanogram and absent stapedial reflexes in the left ear.

Computed tomography (CT) (Figs 1A and B) demonstrated a large, hypodense, irregularly enhancing destructive lesion centered in the area of the vestibular aqueduct and endolymphatic sac of the left temporal bone. It also involved the left medial mastoid and middle ear. The mass extended inferiorly to the left jugular fossa and posteriorly into the posterior cranial fossa with slight impression on the anterior aspect of the left cerebellar hemisphere. A linear spiculated density within the lesion was thought to represent intratumoral calcification or residual bone after destructive invasion. The ossicles were embedded in the mass but not destroyed. Slight bulging of the tympanic membrane was noted. Magnetic resonance (MR) (Figs 1C through E) with Fonar 0.3-T resistive magnet showed the

mass to be slightly lobulated and predominantly isointense relative to brain on both the T1-weighted (700/30/3 [repetition time/echo time/excitations]) and T2-weighted (2000/60/1) images. The periphery of the lesion appeared markedly hyperintense on both the T1- and T2-weighted images. This might represent hemorrhage (extracellular methemoglobin) or cystic areas with high protein within the lesion. The mass contained irregular markedly hypointense areas centrally on both the T1- and T2-weighted images corresponding to the areas of calcification or residual bone seen on CT. The lesion showed slight enhancement after the intravenous administration of gadolinium. Clear extension of the mass into the posterior fossa with slight indentation on the anterior aspect of the left cerebellar hemisphere was seen.

A tympanotomy was performed for biopsy of the portion of the lesion within the hypotympanum of the middle ear. At histopathology, the lesion had a papillary pattern, lined by cells with uniform nuclei. No mitosis was found. Immunoperoxidase stains for thyroglobulin, factor VIII, and chromogranin were negative, but keratin was strongly positive. In conjunction with the radiologic findings, the lesion was considered to be a low-grade papillary adenocarcinoma of probable endolymphatic sac origin.

## Discussion

Review of the literature shows controversy regarding the origin of these papillary tumors that destroy a large portion of the posterior temporal bone and have prominent extension into the posterior cranial fossa. Several reports (1–3) mentioned the mastoid or middle ear epithelium as origin of these tumors. However, Heffner (4), in a study of 20 cases, proposed the term *low-grade adenocarcinoma of endolymphatic sac origin* for these lesions. He found the epicenters of the tumors in his cases and in other reports to have the same anatomic loca-

---

Received April 13, 1993; accepted after revision March 14, 1995.

From the Department of Diagnostic Imaging, Temple University Hospital, Philadelphia, Pa (V.T.H., H.T.D.), and the Departments of Radiology (V.M.R.) and Otolaryngology (D.O.M.), Thomas Jefferson University Hospital and Jefferson Medical College, Philadelphia, Pa.

Address reprint requests to V. T. Ho, MD, Department of Radiology (114), McGuire Veterans Affairs Medical Center, 1201 Broad Rock Blvd, Richmond, VA 23249.

AJNR 17:168–170, Jan 1996 0195-6108/96/1701-0168 © American Society of Neuroradiology

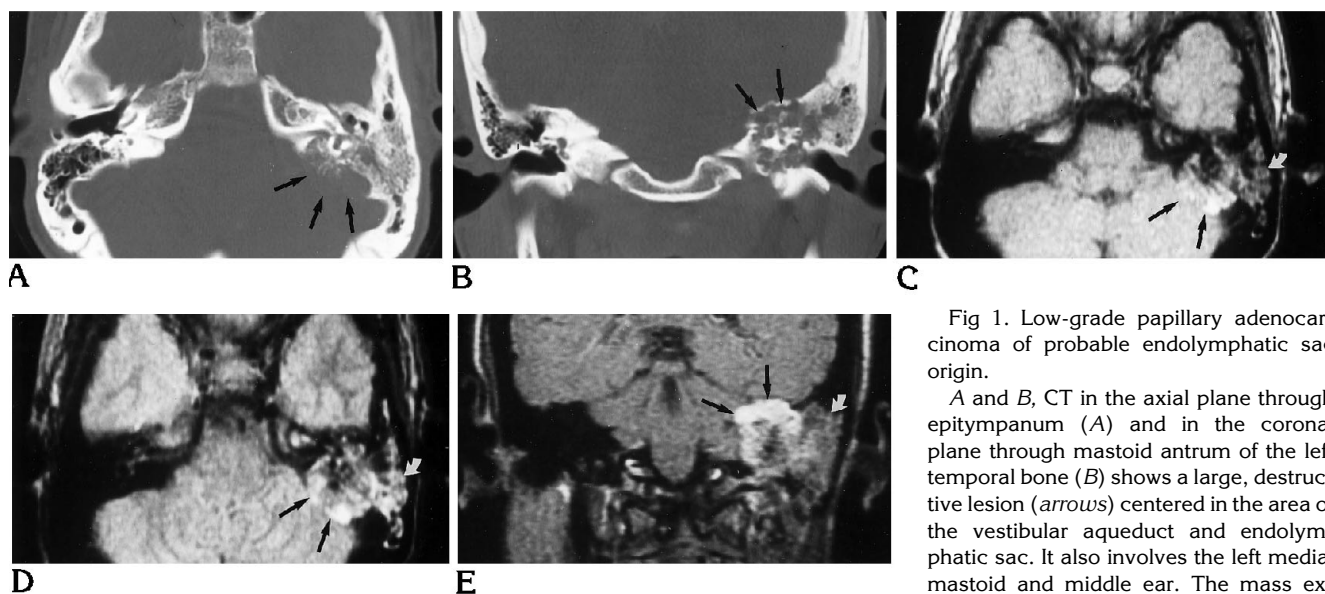


Fig 1. Low-grade papillary adenocarcinoma of probable endolymphatic sac origin.

A and B, CT in the axial plane through epitympanum (A) and in the coronal plane through mastoid antrum of the left temporal bone (B) shows a large, destructive lesion (arrows) centered in the area of the vestibular aqueduct and endolymphatic sac. It also involves the left medial mastoid and middle ear. The mass extends inferiorly to the left jugular fossa

and posteriorly into the posterior cranial fossa. Linear spiculated density within the lesion represents calcification, residual bone after destructive invasion, or dense stroma. The ossicles are embedded in the lesion but not destroyed.

C and D, MR in the axial plane shows the lesion (straight arrows) to be predominantly isointense relative to brain on both the T1-weighted (700/30/3) (C) and T2-weighted (2000/60/1) (D) images. Hyperintensity in the periphery of the mass on both the T1- and T2-weighted images probably represents hemorrhage (extracellular methemoglobin) or cystic areas with high protein content. Irregular markedly hypointense areas on both the T1- and T2-weighted images within the center of the lesion represent calcification, residual bone after destructive invasion, or dense stroma. Hypointensity on the T1-weighted image (C) within the mastoid cells (curved arrow) appearing hyperintense on the T2-weighted image (D) represents obstructive secretions or inflammation.

E, Coronal T1-weighted image (600/30/3) shows slight enhancement of the lesion (straight arrows) after the administration of intravenous gadolinium. Note again obstructive secretions or inflammation within the mastoid air cells (curved arrow).

tion, in the area of the vestibular aqueduct and endolymphatic sac of the posterior petrous bone. In addition, there are some common histologic features between these tumors and the normal endolymphatic sac. The lesions should be distinguished from the widely accepted adenomas of the middle ear and mastoid, which are nonpapillary, are confined to the middle ear and mastoid, and rarely show bone destruction (5-7). A typical case of adenoma of the middle ear and mastoid is shown in Fig 2.

Low-grade adenocarcinomas of endolymphatic sac origin are locally aggressive tumors that usually grow slowly and show no documented metastasis (4). They affect patients within a wide age range (15 to 75 years). The most frequent presenting symptom is hearing loss. Other prominent symptoms include tinnitus, vertigo, ataxia, and facial nerve paresis. Meniere syndrome is uncommon. This could be explained by the slow destruction of the endolymphatic system, allowing compensatory mechanisms to develop.

Histologically, these tumors are composed of papillary and cystic proliferations lined by a single layer of cuboidal epithelial cells that often become more flattened. Sometimes, they become taller and appear low columnar. The nuclei of the epithelial layer show slight variability in size and shape. Mitotic activity is not a feature. The stroma is vascular and moderately cellular. Large areas of hypocellular fibrosis, hemorrhage, cholesterol clefts, and associated reactive changes frequently are found. Some glandular lumina and cysts within the tumor contain proteinaceous materials. There are some histologic similarities between the tumors and normal endolymphatic sac such as papillary architecture, subepithelial vascularity, variable epithelial cells height, and proteinaceous material in the rugose lumen of the sac and in some portions the tumors.

On CT, this tumor appears as a destructive mass having its epicenter in the area of the vestibular aqueduct and endolymphatic sac. A large portion of the lesion extends into the pos-

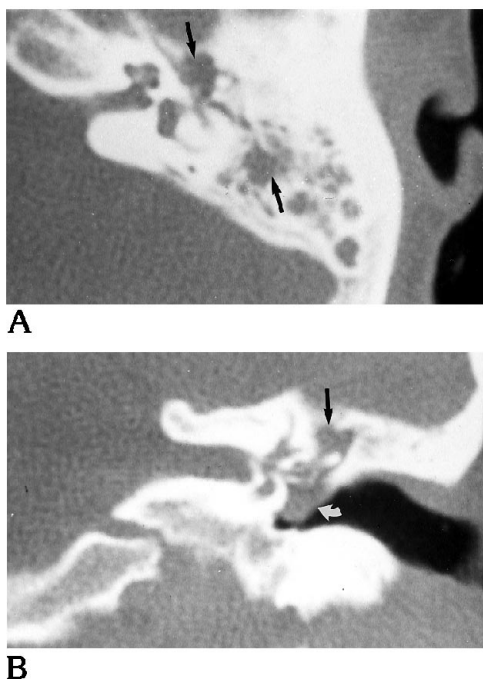


Fig 2. Mixed-type adenoma of the middle ear and mastoid cavity.

A, Unenhanced CT in the axial plane through epitympanum and B, in the coronal plane through vestibule shows complete opacification of the left middle ear and mastoid air cells (straight arrow) with bulging of the tympanic membrane (curved arrow). The ossicles are embedded in the mass but remain intact. No bone destruction is seen.

terior cranial fossa. Our case showed the typical appearance of this tumor. Additionally, the core of the tumor appeared isointense with brain on both the T1- and T2-weighted images with slight enhancement after intravenous gadolinium. The periphery of the lesion was markedly hyperintense relative to brain on both the T1- and T2-weighted images; this may represent hemorrhage (extracellular methemoglobin) or cystic areas with high protein content. The irregular markedly hypointense foci on both the T1- and T2-weighted images within the center of the mass probably represent calcification, residual bone after destructive invasion, or even perhaps dense stroma.

Differential diagnosis includes paraganglioma, meningioma, squamous cell carcinoma, and primary and secondary bone lesions. "Salt-and-pepper" appearance on both T1- and T2-weighted images is characteristic for paragangliomas larger than 2 cm in maximum dimension. This pattern consists of serpiginous foci of signal void, representing high vascular

flow, interspersed among areas of relatively high signal intensity caused by slowly flowing blood and tumor cells (8). Meningiomas arising from the entrance or within a neural foramen may appear intrinsic to the skull base. These tumors show marked enhancement after intravenous gadolinium on MR. Squamous cell carcinomas have a classic presentation of otalgia and persistent ear drainage (often bloody) in the setting of long chronic ear infection (9). Primary and secondary bone lesions may be indistinguishable radiographically from low-grade adenocarcinomas of endolymphatic sac origin. Metastatic lesions from papillary thyroid carcinoma represent a significant problem because their histology resembles that of the low-grade papillary adenocarcinoma. Both contain cysts and areas with crowded glandular structures that look alike. However, papillary thyroid carcinomas stain positive for thyroglobulin, whereas low-grade adenocarcinomas of endolymphatic sac origin are negative (4).

A destructive lesion of the petrous pyramid centered in the area of the vestibular aqueduct and endolymphatic sac and with prominent extension into the posterior cranial fossa should suggest the diagnosis of low-grade adenocarcinoma of endolymphatic sac origin.

## References

- Schuller DE, Conley JJ, Goodman JH, Clausen KP, Miller WJ. Primary adenocarcinoma of the middle ear. *Otolaryngol Head Neck Surg* 1983;91:280-283
- Pallanch JF, McDonald TJ, Weiland LH, Facer GW, Harner SG. Adenocarcinoma and adenoma of the middle ear. *Laryngoscope* 1982;92:47-53
- Gaffey MJ, Mills SE, Fechner RE, Intemann SR, Wick MR. Aggressive papillary middle-ear tumor: a clinicopathologic entity distinct from middle-ear adenoma. *Am J Surg Pathol* 1988;12:790-797
- Heffner DK. Low-grade adenocarcinoma of probable endolymphatic sac origin: a clinicopathologic study of 20 cases. *Cancer* 1989;64:2292-2302
- Hyams VJ, Michaels L. Benign adenomatous neoplasm (adenoma) of the middle ear. *Clin Otolaryngol* 1976;1:17-26
- Benecke JE Jr, Noel FL, Carberry JN, House JW, Patterson M. Adenomatous tumors of the middle ear and mastoid. *Am J Otolaryngol* 1990;11:20-26
- Mills SE, Fechner RE. Middle ear adenoma: A cytologically uniform neoplasm displaying a variety of architectural patterns. *Am J Surg Pathol* 1984;8:677-685
- Olsen WL, Dillon WP, Kelly WM, Normal D, Brant-Zawadzki M, Newton TH. MR imaging of paragangliomas. *AJNR Am J Neuroradiol* 1986;7:1039-1042
- Lo WWM. Tumors of the temporal bone and the cerebellopontine angle. In: Som PM, Bergeron RT, eds. *Head and Neck Imaging*. St Louis: Mosby Year Book, 1991:1046-1108