



Get Clarity On Generics

Cost-Effective CT & MRI Contrast Agents



FRESENIUS
KABI

WATCH VIDEO

AJNR

High-resolution CT findings in the development of the sphenoccipital synchondrosis.

K Okamoto, J Ito, S Tokiguchi and T Furusawa

AJNR Am J Neuroradiol 1996, 17 (1) 117-120

<http://www.ajnr.org/content/17/1/117>

This information is current as
of August 25, 2025.

High-Resolution CT Findings in the Development of the Sphenooccipital Synchondrosis

Kouichirou Okamoto, Jusuke Ito, Susumu Tokiguchi, and Tetsuya Furusawa

PURPOSE: To evaluate the development of the sphenooccipital synchondrosis as seen on high-resolution thin-section CT scans. **METHODS:** We retrospectively reviewed the records of 253 patients, ages 1 to 77 years old, who had had thin-section CT examination of the skull base. **RESULTS:** An ossification center appeared midline in the patients who were 8 to 13 years old. Six of 12 girls showed additional symmetric ossification centers on either side of the midline; however, this pattern was not seen in boys. No sphenooccipital synchondrosis persisted in any patient past the age of 13 years. **CONCLUSION:** High-resolution CT scans of the skull base can show a pattern of progressive ossification of the sphenooccipital synchondrosis, which can be readily recognized and predicted.

Index terms: Skull, anatomy; Skull, computed tomography; Skull, growth and development

AJNR Am J Neuroradiol 17:117-120, January 1996

Growth of the cranial base after birth continues, especially at the sphenooccipital synchondrosis, until adolescence (1). The sphenooccipital synchondrosis is one of cartilaginous joints (1, 2), and it may be visible on lateral radiographs of the skull base through the period of adolescence (3). The synchondrosis ossifies and closes about 1 to 2 years earlier in girls (4-6). Some authors have described the histologic and radiographic appearance of the sphenooccipital synchondrosis (4-8). To evaluate the development of the sphenooccipital synchondrosis, we analyzed high-resolution thin-section CT scans of this structure in 253 patients.

Materials and Methods

The sphenooccipital synchondrosis was studied retrospectively in 253 patients, ages 1 to 77 years old, who had had thin-section CT examination for a variety of otologic

disorders but who did not have systemic chondroosseous disease. CT was performed with 1.5- to 2.5-mm section thickness and the same section intervals parallel to the orbitomeatal line. CT scans with identical window width (4000 Hounsfield units [HU]) and window level (1200 HU) were obtained for optimal evaluation of bony structures.

Three points were assessed on CT scans: (a) persistence of the synchondrosis, (b) the location and time of appearance of the ossification center in the synchondrosis, and (c) the vestige of the synchondrosis after fusion of the sphenoid and occipital bones.

Results

A midline ossification center within the sphenooccipital synchondrosis was observed in 22 of 40 patients who were 8 to 13 years old. This ossification center was in the upper half of the synchondrosis in 10 patients, in the middle portion of the synchondrosis in 7 patients, and covered almost the entire length of the synchondrosis in 4 patients. In the one remaining patient, the upper half of the synchondrosis was closed, and an ossification center was seen in the patent lower half of the synchondrosis. This was the only patient in whom partial closure of the synchondrosis was seen. This particular ossification center was always located in the midline, and was as dense as cortical bone in 20 (91%) of the 22 cases (Fig 1). Additional symmetric ossification centers were observed on either

Received March 7, 1995; accepted after revision July 11.

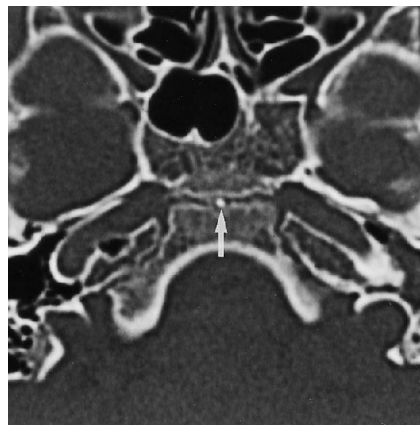
From the Department of Radiology, School of Dentistry (K.O., J.I., S.T.), and the Department of Radiology, School of Medicine (T.F.), Niigata University, Japan.

Address reprint requests to Kouichirou Okamoto, MD, Department of Radiology, School of Dentistry, Niigata University, 2-5274 Gakkocho-dori, Niigata City 951, Japan.

AJNR 17:117-120, Jan 1996 0195-6108/96/1701-0117

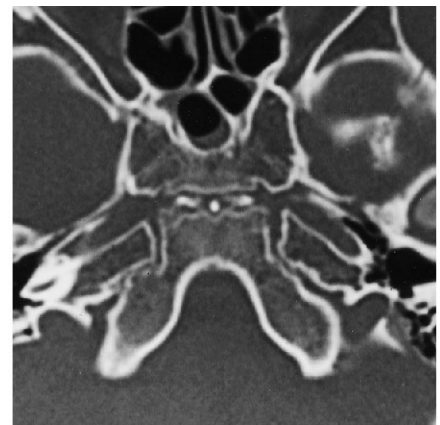© American Society of Neuroradiology

Fig 1. CT scan in a 9-year-old girl shows the sphenoccipital synchondrosis with an ossification center that is as dense as the cortical bone and located on the midline (arrow).



1

Fig 2. CT scan in another 9-year-old girl shows the sphenoccipital synchondrosis with additional symmetric ossification centers on either side of the midline.



2

side of the midline center in 6 of 12 girls but were not found in any of the boys (Fig 2). In patients with an observed midline ossification center, the hyaline cartilage of the synchondrosis was preserved as a hypodense zone around the ossification center.

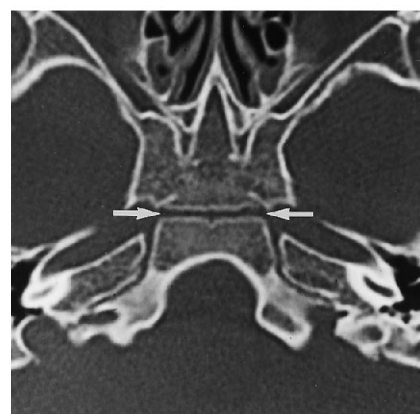All 20 patients younger than 8 years old showed a hypodense synchondrosis between the sphenoid and occipital bones without the presence of an ossification center (Fig 3). The earliest complete closure of the synchondrosis occurred in boys at the age of 13 and in girls at the age of 12. The sphenoccipital synchondrosis was closed in all patients older than age 13. In one girl, the sphenoccipital synchondrosis had been observed as a hypodense zone without an ossification center at the age of 12, and a follow-up CT scan at the age of 14 showed only a vestige of the synchondrosis as a white line.

After fusion of the sphenoid and occipital bones, the sphenoid sinus was limited within the

sphenoid bone in 51 patients and extended into the basilar part of the occipital bone in the remaining 144 patients. A vestige of the sphenoccipital synchondrosis was observed as a white line in 48 of 51 patients who had a limited sphenoid sinus (Fig 4) and in 3 patients (women ages 21, 23, and 62 years old) in whom only a small part of the sphenoid sinus extended into the occipital bone partially beyond the vestige. In these patients, the white line was not as dense as in the cortical bone.

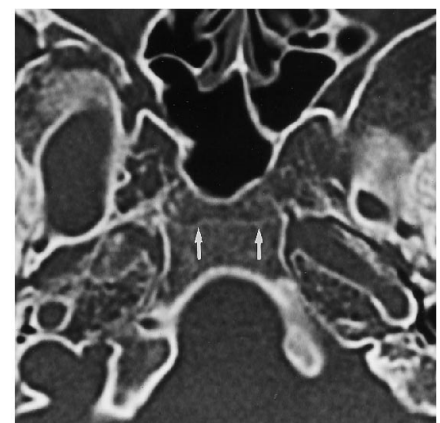
The vestige was not identified in three patients with a limited sphenoid sinus (a 55-year-old man and two women ages 35 and 69 years old, respectively) and in 141 patients with well-developed sphenoid sinuses extending into the occipital bone. The sphenoccipital synchondrosis or the boundary between the sphenoid and occipital bones was no longer identifiable in these patients. Markedly developed sphenoid sinuses reaching to the clivus were seen in 47%

Fig 3. CT scan in a 7-year-old girl shows the sphenoccipital synchondrosis without an ossification center. The synchondrosis is seen as a hypodense zone between the sphenoid and occipital bones (arrows).



3

Fig 4. CT scan in a 19-year-old man shows that the sphenoccipital synchondrosis has closed completely and its vestige appears as a white line (arrows).



4

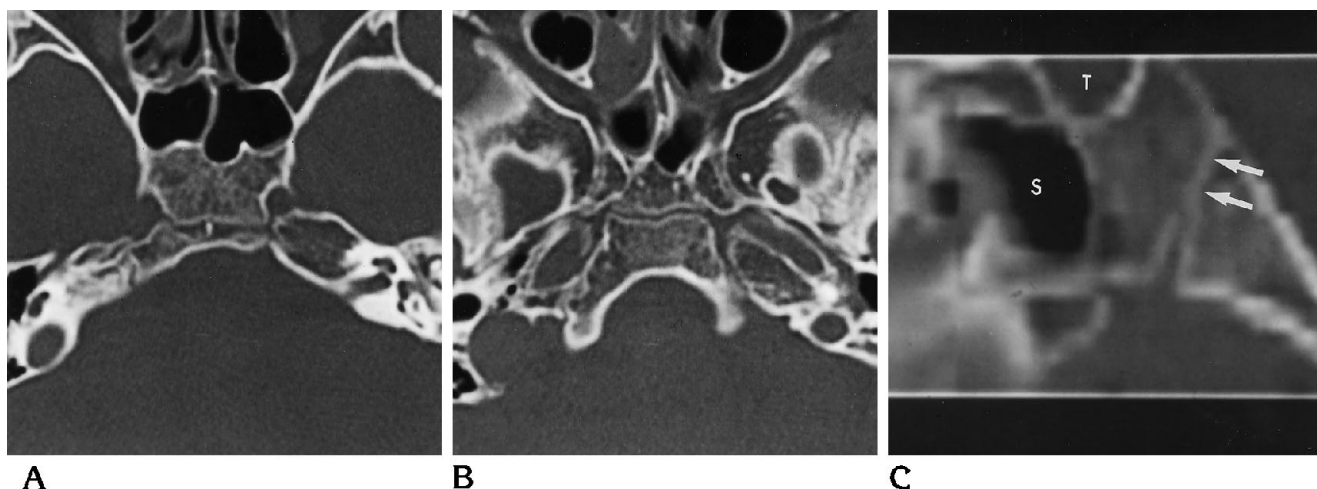


Fig 5. CT scans of the sphenooccipital synchondrosis in a 10-year-old girl.

A, The ossification center appears midline in the upper portion of the synchondrosis.

B, On CT section 6 mm lower, there is no ossification center.

C, The ossification center, which is clearly seen on axial images, may be misinterpreted as superior closure (arrows) on this reformatted midsagittal image. S indicates sphenoid sinus; T, sella turcica.

of the patients in whom the sphenoid sinus extended into the occipital bone.

Discussion

The base of the infant skull contains many synchondroses that are obliterated by maturation (3). Growth of the skull base is responsible for much of the cranial lengthening, mostly at synchondroses between the sphenoid and occipital bones (1). Three prominent vertical clefts cross the skull base in the sphenoid region: the frontosphenoid, the intersphenoid, and the sphenooccipital synchondroses. The first two usually close by age 2, but the sphenooccipital synchondrosis may be visible on lateral radiographs of the skull base through the period of adolescence (3). On craniograms in infants, the sphenooccipital synchondrosis should not be mistaken for the other synchondroses or for a persistent craniopharyngeal canal (9).

The sphenooccipital synchondrosis has been studied histologically and radiographically (4–8). In one anatomic study (5), closure of the synchondrosis was noted to start at the internal surface of the cranial base and was closed completely between the ages of 12 and 17 years. However, superior closure of the synchondrosis is commonly observed radiographically in patients 9 to 18 years old (4, 7).

In our high-resolution CT study, an ossification center was seen to develop initially within

the synchondrosis, and the ossification was completed between the ages of 8 and 13 years old. The time of closure observed in our study is compatible with that described in a review by Hoyte (6).

The ossification center has been described histologically (5). A tiny ossification center cannot be seen on a radiograph of the skull base. On the other hand, a larger ossification center within the synchondrosis may be mistaken for a partially (usually superiorly) or totally closed synchondrosis (Fig 5).

After fusion of the sphenoid and occipital bones is complete, the sphenoid sinuses may extend into the basilar part of the occipital bone in many patients. It is known that the primary development of the sphenoid sinuses takes place after puberty and that they may extend into the basilar part of the occipital bone almost as far as the foramen magnum (10, 11). In these cases, the sphenooccipital synchondrosis is no longer identifiable, even on CT scans. Although a persistent sphenooccipital synchondrosis up to 20 years of age has been reported, it was not seen in our study and is thought to be rare (12). Therefore, if a transversely oriented hypodense zone across the clivus is seen on CT scans in patients with head trauma who are 13 years of age or older, it is more likely to represent a skull base fracture than persistent synchondrosis.

References

1. Williams PL, Warwick R, Dyson M, Bannister LH. *Gray's Anatomy*, 37th ed. Edinburgh: Churchill Livingstone, 1989;393
2. Clemente CD. *Gray's Anatomy*, 30th American ed. Philadelphia: Lea & Febiger, 1985;333
3. Rosenberg RN, ed. *The Clinical Neurosciences: Neuroradiology*. New York: Churchill Livingstone, 1984;IV:46
4. Powell TV, Brodie AG. Closure of the spheno-occipital synchondrosis. *Anat Rec* 1963;147:15–23
5. Melsen B. Time and mode of closure of the spheno-occipital synchondrosis determined on human autopsy material. *Acta Anat* 1972;83:112–118
6. Hoyte DAN. A critical analysis of the growth in length of the cranial base. *Birth Defects* 1975;11:255–282
7. Orion GL. Roentgen determination of the time of closure of the spheno-occipital synchondrosis. *Radiology* 1960;75:450–453
8. Latham RA. Observations on the growth of the cranial base in the human skull. *J Anat* 1966;100:435
9. Shopfner CE, Wolfe TW, O'Kell RT. The intersphenoid synchondrosis. *AJR Am J Roentgenol* 1968;104:184–193
10. Clemente CD. *Gray's Anatomy*, 30th American ed. Philadelphia: Lea & Febiger, 1985;205, 1364
11. Williams PL, Warwick R, Dyson M, Bannister LH. *Gray's Anatomy*, 37th ed. Edinburgh: Churchill Livingstone, 1989;374, 1179
12. Wackenheim A. Hypoplasia of the basi-occipital bone and persistence of the spheno-occipital synchondrosis in a patient with transitory supplementary fissure of the basi-occipital. *Neuroradiology* 1985;27:226–231