



Providing Choice & Value

Generic CT and MRI Contrast Agents



**FRESENIUS
KABI**

CONTACT REP

AJNR

Spontaneous disappearance of a spinal dural arteriovenous fistula.

J F Meder, B Devaux, J J Merland and D Frödy

AJNR Am J Neuroradiol 1995, 16 (10) 2058-2062

<http://www.ajnr.org/content/16/10/2058>

This information is current as
of July 31, 2025.

Spontaneous Disappearance of a Spinal Dural Arteriovenous Fistula

Jean François Meder, Bertrand Devaux, Jean Jacques Merland, and Daniel Frédy

Summary: A case of proved regression of an asymptomatic dural arteriovenous fistula is reported. At the time of diagnosis, myelography showed dilated perimedullary veins. Angiography demonstrated a radicular outflow from these veins to the epidural plexus. A follow-up angiogram 5 years later was normal.

Index terms: Fistula, spinal dural; Spinal angiography

The spontaneous disappearance of a non-traumatic dural arteriovenous fistula (AVF) is a rare occurrence. Eleven cases have been documented in the literature (1–10), of which one was spinal. We report a case of the spontaneous disappearance of a spinal dural AVF with perimedullary venous drainage verified by angiography. This fistula caused neither clinical nor radiologic medullary symptoms.

Case Report

A 56-year-old man presented in 1984 with an episode of left lumbocruralgia after a lifting effort. Clinical examination showed left crural hypoesthesia and a diminished left patellar reflex. The plain x-ray work-up showed no significant abnormalities. Treatment, including antiinflammatory drugs and rest, was instituted and resulted in incomplete resolution of the symptoms. In October 1986, the patient was hospitalized in the neurosurgical department of the Centre Hospitalier Sainte-Anne, Paris, France. Clinical examination revealed amyotrophy of the left quadriceps with no loss of muscular force, abolition of the left patellar reflex, and reduction of the left achilles reflex. Non-insulin-dependent diabetes was discovered, and glizazide treatment was started. X-ray computed tomography revealed an osteophyte of the inferior surface of L-3 with no accompanying spinal root compression. Examination by MR (General Electric 0.5-T unit), which included T1- and T2-weighted sequences centered on the lumbar and lower dorsal regions, was normal, and showed, in particular, no hyperintensity of the conus medullaris. With dorsolumbar myelography, no sign of spinal root com-

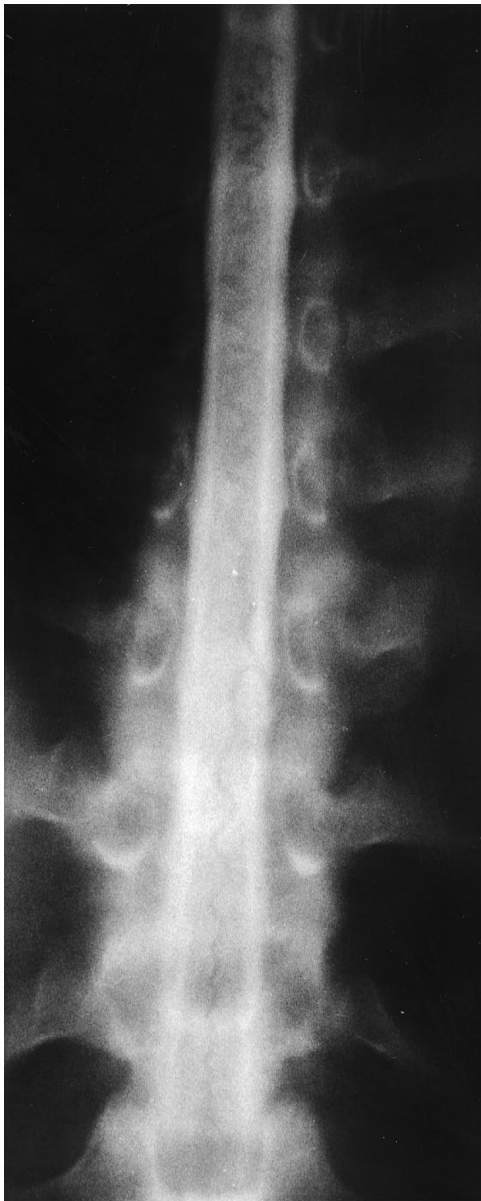pression was found in the lumbar region. However, there was dilation of the retromedullary venous network, typical of a dural AVF with perimedullary venous drainage (Fig 1A). Angiography was therefore performed. The first right lumbar artery supplied the artery of Adamkiewicz, for which the venous drainage appeared within normal time limits (Fig 1B, C). A slow-flowing dural AVF was found on injection of the sixth left intercostal artery. The dilated and tortuous draining vein was descending exclusively. It ran into a radiculospinal vein, which reached the venous plexus of the intervertebral foramen at T10–11 in less than 13 seconds. The retromedullary venous draining network of the dural AVF also opacified the upper portion of a descending spinal vein (Fig 1D, E). Lumbar phlebography was performed to search for lateral compression of the third left lumbar spinal root by opacification of the left ascending lumbar vein and the right lateral sacral vein. A lumbar spinal vein, which was opacified in an ascending manner from the L5–S1 level, reached the left radiculospinal vein at T-10, draining the previously described fistula (Fig 1F, G). Because of the lack of any clinical link between the dural AVF and clinical symptoms, embolization of the lesion was not performed.

The patient returned home and reported a moderate reduction of pain after a few weeks. In January 1991, the patient was hospitalized for follow-up examination. His pain symptoms had not changed. In addition, the patient reported an erection disorder, and clinical examination found that the left patellar and achilles reflexes were absent. Thoracolumbar MR, including T1-weighted sagittal sections before and after gadolinium injection and T2-weighted sections, was normal. Spinal angiography included injection of the first right lumbar artery and the fifth, sixth, and seventh left intercostal arteries. It showed the disappearance of the dural AVF (Fig 1H) and a normal anterior spinal artery with its normal venous drainage. The patient left the hospital with no modification to his treatment. MR findings performed in July 1993 were normal. The clinical status of the patient, who is regularly followed, has remained unchanged as of the date of submission of this report.

Received April 4, 1995; accepted after revision July 27.

From the Departments of Neuroradiology (J.F.M., D.F.), and Neurosurgery (B.D.), Centre Hospitalier Sainte-Anne, Paris, France; and the Department of Neuroradiology, (J.J.M.), Hôpital Lariboisière, Paris, France.

Address reprint requests to Jean François Meder, Service de Neuroradiologie, Centre Hospitalier Sainte-Anne, 1 rue Cabanis, 75674 Paris Cedex, France.



A

Fig 1. A, Thoracic myelogram shows serpiginous filling defects corresponding to dilated retromedullary veins. *Figure continues.*

Discussion

Dural AVFs account for 70% to 80% of the spinal arteriovenous lesions in adults (11). Dural AVFs involve transdural shunts, fed by dural branches of a radicular artery and drained by a single vein that joins the dilated perimedullary venous network, without any drainage into the epidural space (12). The conflict between the venous drainage of the fistula and that of the spinal cord seems to be responsible for myelopathy, which usually develops with such disor-

ders (11, 13). The first symptom of this disease usually is weakness in the lower limbs or either superficial or deep impairment of sensation (11, 14). Spinal root pain is rarely the inaugural symptom, involving 5% to 15% of the cases, according to published series (11, 14). Usually, the disease progresses quickly, and in 66% of the cases, the clinical syndrome is complete within 3 years of the first symptom (15). Some exceptional reports describe longer periods of evolution, such as 8 years (11) or even longer than 10 years (15). The patient's syndrome we report could be consistent with that of a dural AVF, but it is difficult to attribute the lumbocurralgia to the fistula. Indeed, pain persisted with no major change throughout the 10 years of patient follow-up and showed no sign of medullary involvement. It is more likely that the radiculalgia and the erection disorder presented by our patient are attributable to the diabetic neuropathy.

Spontaneous disappearance of a dural AVF has previously been documented at the spinal level by Renowden and Molyneux (9). However, there was no angiographic proof that a dural AVF was responsible for the clinical symptoms. Furthermore, premedullary vessels were observed on the gadolinium-enhanced sagittal T1-weighted, inconsistent with thrombosis of the proposed dural AVF. In our case, it is difficult to determine the date at which the dural AVF disappeared or to link its disappearance to any intervening clinical event. The literature provides little explanation for the disappearance of a dural AVF. At the cranial level, even when a cause has been suspected, no formal proof is available linking the cause to the effect. Occlusion of a dural AVF may be observed after thrombosis of an adjacent sinus (1, 7, 10), after angiography (8, 16), or after treatment with contraceptive hormones (4). Disappearance after hemorrhage, which has been described for arteriovenous malformations, does not seem to be the case for dural AVF. Olutola et al reported a case of a dural AVF, associated with an intracranial hematoma, which had later disappeared, documented by angiographic follow-up 4 months later (17). This case most certainly corresponds to a traumatic form of dural AVF for which disappearance seems to be more common than in nontraumatic forms. In our patient, none of the causes described above or hemocoagulation disorders were found. Only

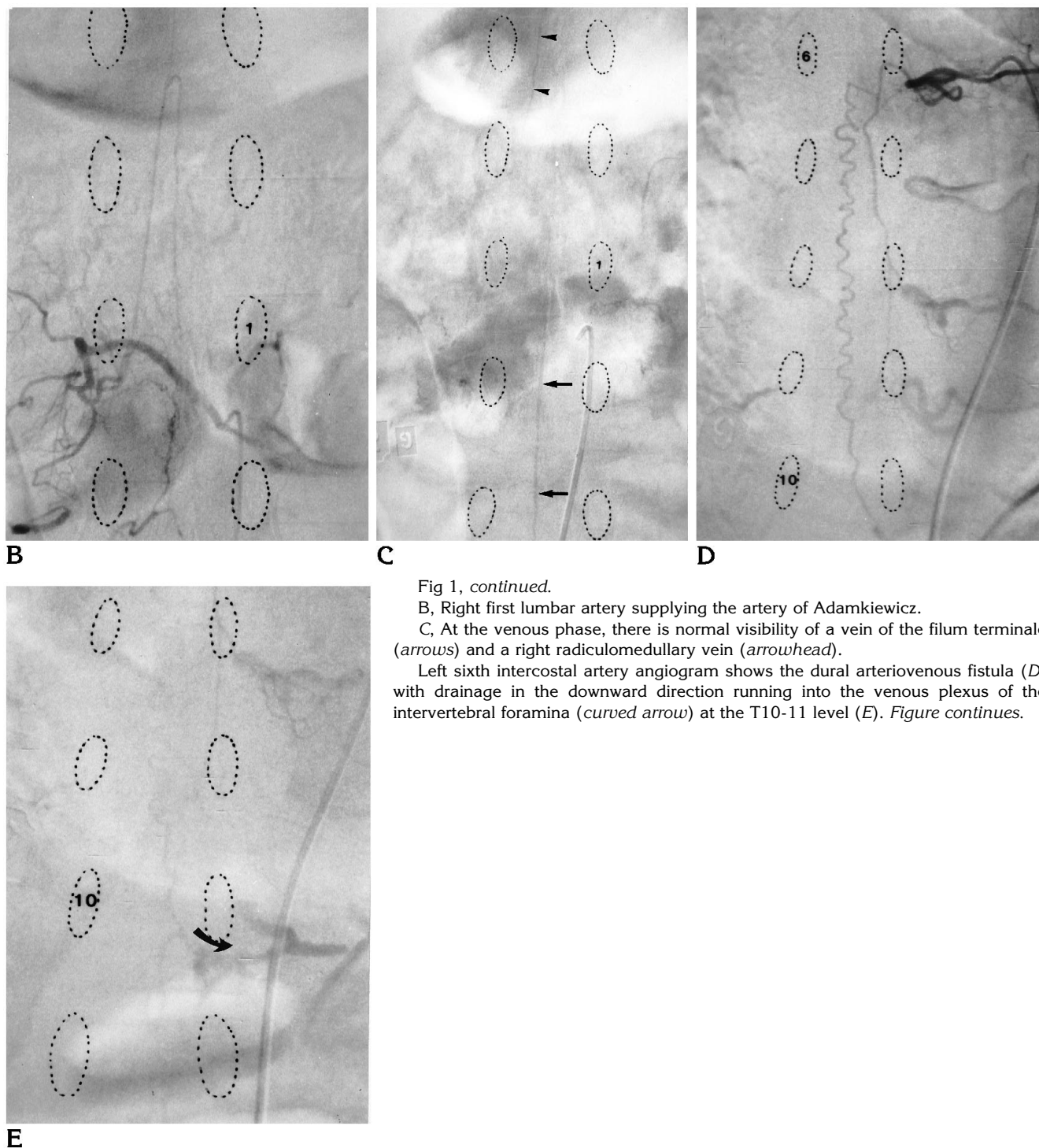


Fig 1, continued.

B, Right first lumbar artery supplying the artery of Adamkiewicz.

C, At the venous phase, there is normal visibility of a vein of the filum terminale (arrows) and a right radiculomedullary vein (arrowhead).

Left sixth intercostal artery angiogram shows the dural arteriovenous fistula (D) with drainage in the downward direction running into the venous plexus of the intervertebral foramina (curved arrow) at the T10-11 level (E). *Figure continues.*

diabetes might possibly be incriminated as a factor promoting thrombosis of the dural AVF.

The reasons for the development of a dural AVF with perimedullary venous drainage remain unclear. Spontaneous evolution toward myelopathy, which is usually observed in cases

of dural AVFs, did not occur in our patient. The presence of the fistula followed by its disappearance raises the possibility of its playing a physiologic role. Anatomic studies have shown the existence of normal dural arteriovenous shunts (18, 19), but their cause and physiology are

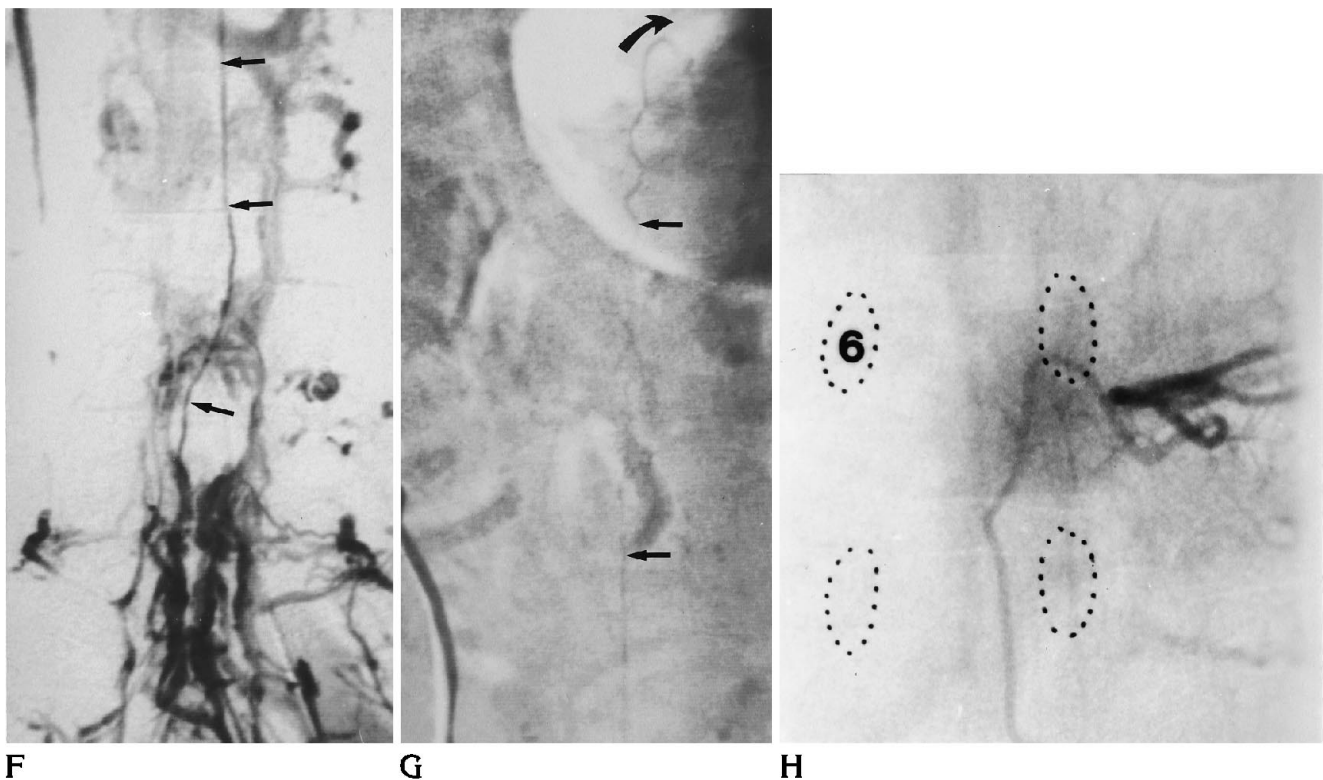


Fig 1, continued.

Lumbar phlebography shows opacification of the lumbar spinal vein (arrows), from the L5-S1 level (F) to the radiculomedullary vein (curved arrow) draining the fistula (G).

H, Follow-up left sixth intercostal artery angiogram demonstrates the disappearance of the fistula. *Figure continues.*

unknown. In our case, lumbar phlebography shows opacification of a lumbar spinal vein, which joined the radiculospinal vein, draining the dural AVF (Fig 1I). Visibility of subarachnoid venous structures during lumbar phlebography is rare but has been noted previously (20, 21). Such reflux may represent failure of the antireflux system related to the dural passage of radiculospinal veins (21). The failure of this system could lead to a risk of myelopathy through venous hypertension. A link between the dural AVF and the failure of the antireflux protective system is thus a possibility. However, this hypothesis seems improbable considering the very dilated and tortuous pathologic appearance of the perimedullary draining veins of the dural AVF.

A more likely hypothesis is of a dural AVF discovered before the onset of signs of medullary involvement. The study of the venous drainage of the anterior spinal artery of the lumbar enlargement is an essential part of the angiographic work-up of a dural AVF with per-

imedullary spinal drainage being responsible for myelopathy. Willinsky et al (22) believe that the search for a dural AVF is not necessary if the venous drainage of the anterior spinal artery is visualized within the normal time limits and, corresponds to myelographic venous filling defects. Normal circulation of the Adamkiewicz complex during the arterial and venous phases indicates the absence of constraint imposed by a dural AVF on medullary circulation. Even though dural AVFs drain into the epidural plexus, such drainage cannot be observed in most cases of medullary or cauda equina syndrome. Therefore, an imbalance between incoming blood from the dural AVF and an obstruction to its extradural venous drainage seems to be present in the development of myelopathy. The onset of myelopathy, the analysis of which would have provided a better understanding of the natural course of dural AVFs, was not observed in our patient. These findings call into question the necessity of treatment of such dural AVFs.

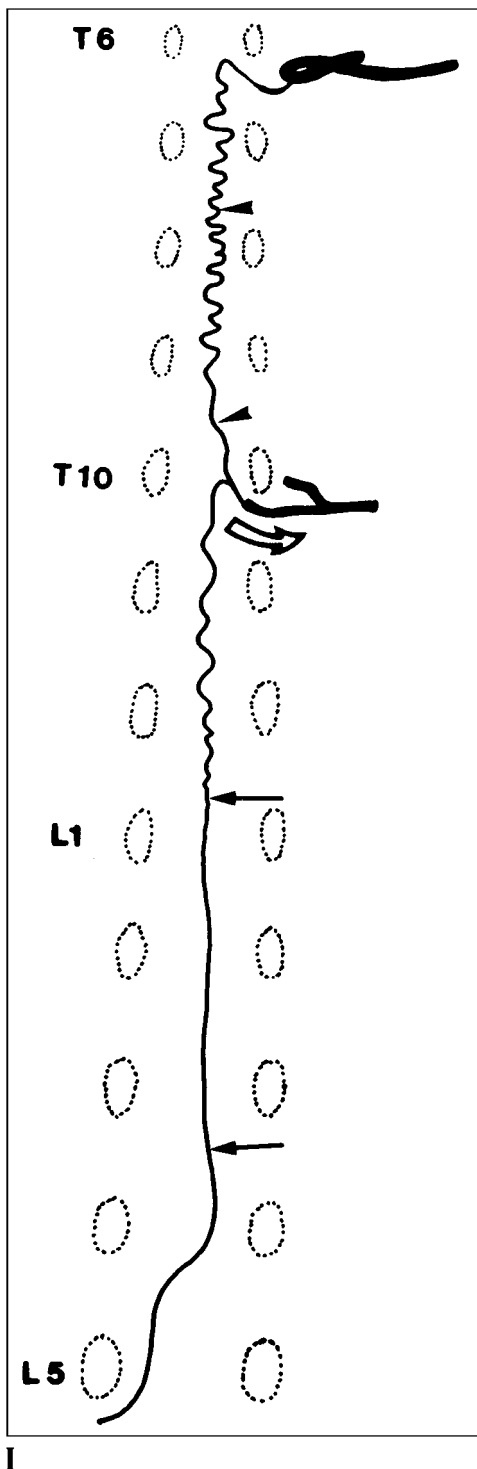


Fig 1, continued.

I, Schematic representation of opacified subarachnoid veins shows convergence on the left T-10 radiculomedullary vein of the fistula draining vein (arrowhead) and the lumbar spinal vein (arrows) seen on lumbar phlebography.

References

1. Bitoh S, Sakaki S. Spontaneous cure of dural arteriovenous malformation in the posterior fossa. *Surg Neurol* 1979;12:111-114
2. Chaudhary MY, Sachdev VP, Cho SH, Weitzner I, Puljic S, Huang YP. Dural arteriovenous malformation of the major sinuses: an acquired lesion. *AJNR Am J Neuroradiol* 1982;3:13-19
3. Endo S, Kosu K, Suzuki J. Spontaneous regression of posterior fossa dural arteriovenous malformation. *J Neurosurg* 1979;51:715-717
4. Hansen JH, Sogaard I. Spontaneous regression of an extra- and intracranial arteriovenous malformation: case report. *J Neurosurg* 1976;45:338-341
5. Kataoka K, Taneda M. Angiographic disappearance of multiple dural arteriovenous malformations: case report. *J Neurosurg* 1984;60:1275-1278
6. Kutluk K, Schumacher M, Mironov A. The role of sinus thrombosis in occipital dural arteriovenous malformations: development and spontaneous closure. *Neurochirurgia (Stuttg)* 1991;34:144-147
7. Magidson MA, Weinberg PE. Spontaneous closure of a dural AVM. *Surg Neurol* 1976;6:107-110
8. Reul J, Thron A, Laborde G, Brückmann H. Dural arteriovenous malformations at the base of the anterior cranial fossa: report of nine cases. *Neuroradiology* 1993;15:388-393
9. Renowden SA, Molyneux AJ. Case report: spontaneous thrombosis of a spinal dural AVM (Foix-Alajouanine syndrome)-magnetic resonance appearance. *Clin Radiol* 1993;47:134-136
10. Rorh J, Gauthier G. Regression spontanée d'une fistule artérioveneuse. *Rev Neurol* 1985;141:240-244
11. Benhaïem N, Poirier J, Hurth M. Arteriovenous fistulae of the meninges draining into the spinal veins. *Acta Neuropathol (Berl)* 1983;62:103-111
12. Koenig E, Thron A, Schrader V, Dichgans J. Spinal arteriovenous malformations and fistulae: clinical, neuroradiological and neurophysiological findings. *J Neurol* 1989;236:260-266
13. Merland JJ, Riche MC, Chiras J. Intraspinal extramedullary AVF draining into the medullary veins. *J Neuroradiol* 1980;7:271-320
14. Roseblum B, Oldfield EH, Doppman JL, Di Chiro G. Spinal arteriovenous malformations: a comparison of dural AVFs and intradural AVM's in 81 patients. *J Neurosurg* 1987;67:795-802
15. Symon L, Kuyama H, Kendall B. Dural arteriovenous malformations of the spine: clinical features and surgical results in 55 cases. *J Neurosurg* 1984;60:238-247
16. Newton TH, Hoyt WF. Dural arteriovenous shunts in the region of the cavernous sinus. *Neuroradiology* 1970;1:71-81
17. Olutola PS, Eliam M, Molot M, Talalla A. Spontaneous regression of a dural arteriovenous malformation. *Neurosurgery* 1983;12:687-690
18. Manelfe C, Lazorthes G, Roulleau J. Artères de la dure-mère rachidienne chez l'homme. *Acta Radiol* 1972;13:829-841
19. Kerber CW, Newton TH. The macro and microvasculature of the dura mater. *Neuroradiology* 1973;6:175-179
20. Théron J, Moret J. *Spinal Phlebography: Lumbar and Cervical Techniques*. New York, NY: Springer Verlag 1978
21. Tadié M, Hemet J, Freger P, Clavier E, Creissard P. Morphological and functional anatomy of spinal cords veins. *J Neuroradiol* 1985;12:3-20
22. Willinsky R, Lasjaunias P, Terbrugge K, Hurth M. Angiography in the investigation of spinal dural AVF: a protocol with application of the venous phase. *Neuroradiology* 1990;32:114-116