



Get Clarity On Generics

Cost-Effective CT & MRI Contrast Agents

**FRESENIUS
KABI**

WATCH VIDEO

AJNR

Sonographic lenticulostriate vasculopathy in infants: some associations and a hypothesis.

H S Wang, M F Kuo and T C Chang

AJNR Am J Neuroradiol 1995, 16 (1) 97-102

<http://www.ajnr.org/content/16/1/97>

This information is current as
of August 6, 2025.

Sonographic Lenticulostriate Vasculopathy in Infants: Some Associations and a Hypothesis

Huei-Shyong Wang, Meng-Fai Kuo, and Ting-Chang Chang

PURPOSE: To describe the causes of infantile lenticulostriate vasculopathy (LSV) as demonstrated by sonography and propose the pathogenesis of these findings. **METHODS:** Five hundred eighty-six infants were examined via echoencephalography because of seizures, psychomotor retardation, dysmorphism, congenital malformation, microcephaly, macrocephaly, bulging of anterior fontanel, consciousness disturbance, or prematurity. We directed our attention on the sonographic study to the basal ganglionic and thalamic areas. Twenty-eight of the 586 patients underwent color Doppler studies. **RESULTS:** In 34 infants with gray-scale neurosonographic findings of LSV, 16 were associated with various causes that have been reported before. In 8 patients entities not previously associated with LSV were found: neonatal lupus, neonatal hypoglycemia, uncomplicated prematurity, encephalitis, and head injury. In the remaining 10 cases, a specific cause could not be found. The LSV was found in 16 (40%), 5 (14%), and 13 (3%) patients with perinatal, acquired, and nonspecific causes, respectively. Generally, this is an uncommon finding because it was observed in only 34 (5.8%) of the study infants; 24 of these 34 had a documented cause of the vasculopathy. With LSV associated with perinatal causes there was a greater chance of sonographic LSV's developing than with that of acquired causes. **CONCLUSIONS:** We suggest that sonographic LSV is a nonspecific marker of a previous insult to the developing brain, and the special hemodynamics of the fetal brain plays an important role in its pathogenesis.

Index terms: Lentiform nucleus; Brain, ultrasound; Infants

AJNR Am J Neuroradiol 16:97-102, January 1995

On gray-scale ultrasound, the vessels supplying the basal ganglia are indistinct from the brain parenchyma in healthy infants (1, 2). We found bright linear "branched candlestick" stripes in these regions, suggesting lenticulostriate vasculopathy (LSV), reported in 96 infants in the English literature (3-15). The known associated causes of these cases include congenital infections, chromosome disorders, maternal drug use, neonatal asphyxia, hydrops

fetalis, diabetic fetopathy, sialidosis, respiratory distress syndrome, apnea, bacterial meningitis, and *Klebsiella pneumoniae*. We reviewed the sonograms and clinical histories of 34 patients with LSV and hypothesize a pathogenesis to evaluate the clinical significance of this sonographic finding and to suggest a cause for its occurrence.

Subjects and Methods

In a retrospective study from January 1991 to June 1992, 586 infants had cranial sonographic examinations for different indications, including seizure, psychomotor retardation, dysmorphism, congenital malformation, microcephaly, macrocephaly, bulging of anterior fontanel, consciousness disturbance, and prematurity. The cranial sonography was performed through the anterior fontanel in all patients with 5-MHz or 7.5-MHz real-time sector transducers. Coronal scans from frontal to occipital poles and sagittal scans from right to left convexities were accomplished in every case. The basal ganglionic and thalamic areas were scanned for branching linear echogenicities. Patients with nonlinear or punctate echogenicity in the

Received March 19, 1993; accepted after revision May 20, 1994.

From the Department of Pediatrics, Chang Gung Medical College, and Department of Neurology, Chang Gung Children's Hospital, (H-S.W.); the Division of Neurosurgery, Department of Surgery, National Taiwan University Hospital, Taipei (M-F.K.); and the Biostatistics Consulting Unit and Department of Obstetrics and Gynecology, Chang Gung Medical Center at Taipei (T-C.C.), Taiwan.

Address reprint requests to Huei-Shyong Wang, MD, Department of Pediatrics, Chang Gung Memorial Hospital, 199, Tung-Hwa North Rd, Taipei, 10591 Taiwan.

AJNR 16:97-102, Jan 1995 0195-6108/95/1601-0097


© American Society of Neuroradiology

Fig 1. The typical sonographic pattern of LSV in a 7-month-old girl with seizures.

A, Coronal view, gray scale. There is bright linear echogenicity (>, <) lateral to the thalami, bilaterally.

B, Parasagittal view, gray scale. Bright linear echogenicity (>, <) with ramifications radiating in basal ganglia simulating a branched candlestick.

C, Parasagittal view, color duplex, on the same plane as B. There is no color signal over the echogenic stripes except a faint signal (*asterisk*) over a frontal lenticulostriate branch.



basal ganglia were excluded from our study. Sequential follow-up of cranial ultrasound was performed every 1 to 8 weeks until anterior fontanel closure occurred in all cases.

Additional study with two-dimensional, range-gated, pulsed color Doppler ultrasound was done in 13 patients with sonographic LSV and was done in 15 patients without LSV. An Acuson 128 color Doppler scanner (Acuson, Mountainview, Calif) was used for all 28 cases. The color Doppler signal was detected and analyzed in real time for changes in echo amplitude, frequency, and phase shifts. Imaging parameters were set to maximize the dynamic range of the image. Frame averaging was set at a persistence setting of 4, a moderate edge-enhancing function was selected (preprocessing setting 1), and the log compression was set at 50 dB. Color persistence was at the maximal setting, the band pass filter was at the minimal setting (100 Hz), and the color scale was at the minimal setting (3 cm/s). Color gain was set individually to maximize vascular signal and minimize spurious tissue-motion artifacts. All these ultrasound studies were performed, interpreted, and followed by a single experienced neurosonographer.

A computed tomography or magnetic resonance study of the brain was performed in two cases with prolonged consciousness disturbance and in four cases with significant progression of echogenic stripes. Cerebral angiography was not performed.

Statistical Analysis

A χ^2 test with Yate's correction was used to compare the frequency of LSV found in patients with different associated causes. A two-tailed *P* value below .05 was considered statistically significant.

Results

Thirty-four cases had typical findings of bright linear echogenicity with two to four branches of ramification located in the basal ganglia (Fig 1A and B). In 11 of these 34 cases the first cranial sonograms were done within 1 week after the patients were delivered at our

hospital. The remaining 23 patients, who were referred to our hospital at 3 to 11 months of age, had the characteristic sonographic findings described above when they arrived. Thirty-one of the 34 patients who presented with seizures, psychomotor retardation, dysmorphism, or consciousness disturbance were not born prematurely. The remaining 3 patients were of 30 to 34 weeks gestational age. Two of the 3 were a pair of identical twins. In 11 cases examined in the neonatal period, the typical neurosonographic findings were at the mean age of 5.5 weeks and the median age of 4 weeks. The sonographic vasculopathy was first detected in 2 of the 11 neonates in the first week of life, 2 in the second week, 4 in the fourth week, 2 in the sixth week, and 1 in the seventh month. The other 23 patients, 3 to 11 months old, were referred from other hospitals and had abnormal findings in their first sonographic study at our hospital.

The vasculopathic findings on cranial ultrasound were nonprogressive in 5 cases (15%) and progressive in the remaining 29 cases (85%). In the latter, the echogenic stripes gradually increased in the numbers of branches, their diameters, length, and brightness (Fig 2). No patient showed a decrease in sonographic vasculopathy.

Table 1 shows all the associated causes of LSV in the literature and in our study. No specific underlying metabolic disorders were found in the 2 patients with metabolic acidosis. There were 2 patients with head injury: 1 had subdural hematoma at the age of 6 months, and the other had brain contusion at 10 months of age. No conclusive cause could be found in the remaining 10 patients, 6 of whom had seizures and 4 of whom had psychomotor retardation.

The associated causes in our series were divided into three groups: the perinatal causes (group I) included 16 patients with intrauterine infection, chromosome disorder, maternal drug use, neonatal lupus erythematosus, neonatal asphyxia, neonatal hypoglycemia, diabetic fetopathy, inborn error of metabolism, or hydrops fetalis; the acquired causes (group II) included 5 patients with neonatal bacterial meningitis, encephalitis, or head injury; group III included 13 patients with nonspecific or uncertain causes.

Twenty-eight of the 34 patients had bilateral sonographic changes. The six patients with unilateral sonographic vasculopathy belonged to




Fig 2. The vasculopathic findings on cranial ultrasound were progressive in this case of hypoglycemia in the neonatal period. The echogenic stripes, gradually increasing in the number of branches and their diameter, length, and brightness, were demonstrated in the serial parasagittal sonograms studied at the age of 4 days (A), 3 months (B), and 6 months (C).

group III. No focal neurologic deficits were present in these cases.

In addition to LSV, other neurosonographic abnormalities were found in four patients: holoprosencephaly was found in one case with trisomy 13, symmetric dilatation of lateral ventricles was found in a case of congenital cytomegaloviral infection, a case of idiopathic psychomotor retardation was found, and a subdural collection was found in a patient with head injury.

With color Doppler, arterial pulse signals in the basal ganglia were easily detected in all 15 cases without sonographic LSV (Fig 3). Their distribution and ramification were similar to the gray-scale echogenic stripes of the patients with LSV. Thirteen patients with vasculopathy underwent color Doppler studies. Only 3 of them

TABLE 1: Various associations with sonographic lenticulostriate vasculopathy

	Cases in References 3-15	Our Cases	All Cases Combined
Group I: Perinatal causes	69 (72%)	16 (47%)	85 (65%)
Intrauterine infection	36	6	42 (32.3%)
Cytomegalovirus	23	3	26
Rubella	7	1	8
Syphilis	3	2	5
Maternal varicella (possible)	1	...	1
Trisomy 13	2	...	2
Trisomy 21	5	3	8 (6.2%)
Maternal drug use	2	...	2
Cocaine	14	2	16 (12.3%)
Methamphetamine	6	...	6
Opiate derivative	4	2	6
Phenobarbital	2	...	2
Alcohol	1	...	1
Neonatal asphyxia	1	...	1
Neonatal lupus erythematosus	9	...	9
Neonatal hypoglycemia	...	1	1
Diabetic fetopathy	...	1	1
Inborn metabolic disorder	1	0	1
Sialidosis	1	2	3
Metabolic acidosis	1	...	1
Hydrops fetalis	2	2	2
Group II: Acquired causes	2	1	3
Bacterial meningitis	4 (4%)	5 (15%)	9 (7%)
Encephalitis	3	2	5 (3.8%)
Head injury	...	1	1
<i>Klebsiella pneumoniae</i>	...	2	2
Group III: Nonspecific causes	1	0	1
Respiratory distress syndrome	23 (24%)	13 (38%)	36 (28%)
Uncomplicated prematurity	1	0	1
Apnea	...	3	3
Unknown	1	0	1
Total	21	10	31

demonstrated arterial color signals over the echogenic stripes; 1 of the 3 had faint arterial color signal over one frontal ramus of the echogenic stripes (Fig 1C). The remaining 10 cases had no color Doppler signal in that region.

The computed tomography or magnetic resonance studies performed in six patients showed no corresponding changes in the basal ganglia. One case was associated with congenital cytomegaloviral infection, two with metabolic acidosis, one with encephalitis, and the remaining two with head injury. Focal epileptiform discharges were found in only 3 of 14 electroencephalograms.

We divided our 586 infants into three groups by different causes as shown in Table 2. The LSV was found in 16 (40%), 5 (14%), and 13




Fig 3. The color Doppler sonographic pattern of the usual lenticulostriate arteries.

A, Normal gray-scale appearance. The parasagittal view showed no vascular echogenicity in the basal ganglia.

B, Color Doppler appearance of the same patient and at the same plane as in A. Color signals were demonstrated in the basal ganglia with similar distribution and ramification as in the gray-scale echogenic stripes.

(3%) patients of group I (perinatal causes), II (acquired causes), and III (nonspecific causes), respectively. LSV was an uncommon finding; it was observed in 34 (5.8%) of the infants studied, and 24 of these had a documented cause of the vasculopathy. Conditions occurring during or before the perinatal period had a higher chance of developing into sonographic LSV than those that happened after the perinatal period (group I versus group II, $\chi^2 = 5.22$, $P = .0226$).

Discussion

Sonographic LSV in infants has been associated with intrauterine infection (eg, cytomegaloviral infection, rubella, and syphilis), trisomy 13, maternal drug use, neonatal asphyxia, and neonatal bacterial meningitis (3-15). We exam-

TABLE 2: Number of patients with and without sonographic lenticulostriate vasculopathy (SLV)

	With SLV	Without SLV	Total
Group I: Perinatal causes	16 (40%)	24 (60%)	40
Intrauterine infection	6	4	10
Cytomegalovirus	3	2	5
Rubella	1	1	2
Syphilis	2	1	3
Trisomy 13	3	0	3
Trisomy 21	...	3	3
Maternal drug use	2	1	3
Methamphetamine	2	1	3
Neonatal asphyxia	...	4	4
Neonatal lupus	1	2	3
Neonatal hypoglycemia	1	3	4
Diabetic fetopathy	0	1	1
Inborn metabolic disorder	2	4	6
Hydrops fetalis	1	2	3
Group II: Acquired causes	5 (14%)	31 (86%)	36
Bacterial meningitis	2	12	14
Encephalitis	1	4	5
Head injury	2	15	17
Group III: Nonspecific causes	13 (3%)	497 (97%)	510
Respiratory distress syndrome	0	23	23
Uncomplicated prematurity	3	51	54
Apnea	0	2	2
Others	...	421	421
Unknown	10	...	10
Total	34 (5.8%)	552	586

ined eight patients with LSV who had these same diseases and five patients who had this vasculopathy from other causes such as neonatal lupus, neonatal hypoglycemia caused by maternal pancreatitis, uncomplicated prematurity, encephalitis, and head injury. The sonographic findings were all similar despite the different underlying causes.

In our series, 34 (5.8%) of 586 infants had sonographic LSV as determined by cranial sonographic examinations. The incidence of LSV is higher than the 2.6% and 1.9% in two other reports that included mostly newborn infants (10, 11). This may indicate our awareness of sonographic LSV when performing cranial sonographic examination.

An arterial pulse signal, elicited by focusing the Doppler tracer over the echogenic stripes in the basal ganglia, was reported in a few cases (6, 7, 9, 14). In our experience, in infants without gray-scale sonographic LSV the detection rate is 100% of arterial Doppler signals over the region of basal ganglia. The low detection rate of Doppler signals in 3 of our 13 patients with echogenic stripes suggests that the process of vasculopathy results in stenosis or obstruction

of the lenticulostriate arteries. The stenotic or obstructed lumina and the possible changes in the wall of these lenticulostriate arteries cause echogenic stripes on the gray-scale sonographic study.

Summing all 130 patients of the series in the literature and ours, 85 cases belonged to group I, 9 to group II, and 36 to group III (Table 1). Basal meningitis with involvement of deep perforating vasculature has been reported to cause basal ganglionic, thalamic, or putaminal encephalomalacia (1, 2); however, no similar change was found in our 2 cases of neonatal meningitis. Encephalitis with perivascular cuffing caused by lymphocyte accumulation has been reported to cause perivascular mineralization in a case of progressive rubella panencephalitis (16), but in our case of encephalitis there was no evidence of past or recent rubella infection. Traumatic lenticulostriate change without other abnormal findings was not found. We consider that in the group II cases with acquired causes, the sonographic vasculopathies are merely incidental findings unrelated to the patients' clinical problems. Concerning perinatal conditions, a fetal case with cytomegaloviral infection was found to have echogenic vessels in the thalami and basal ganglia in utero, using the transvaginal probe at 31 weeks gestational age (17). This evidence supports the probability that sonographic LSV occurs in the prenatal period. In the early weeks of fetal brain development, the germinal matrix regions near the caudothalamic grooves are active in rapid cellular mitosis. Because of the active proliferation occurring in these regions, the blood flow in the lenticulostriate arteries that supplying these regions must be very high (18, 19). Many factors, either exogenous or endogenous, influence the germinal matrix, and insults to the brain from hypoxia, ischemia, or other changes in these vessels may result. The prenatal insults resulting in LSV seem not to be highly teratogenic because there were only three cases combined with congenital structural malformation: two previously reported cases of meningomyelocele (11) and a case of holoprosencephaly in one of our patients. We assume that a trivial insult may produce vascular changes in the regions with relatively high blood flow, such as the basal ganglia; however, clinical symptoms do not occur because of the abundant blood supply to these regions. LSV is merely an indicator of

nonspecific early insults to the developing brain.

The sonographic diagnosis of LSV was found in the newborns both in reported cases (3–15) and in our patients who had their first cranial sonographic examinations soon after birth. In the other 23 patients included in our study after their neonatal periods, it was impossible to say whether their sonographic changes had existed before their first examination or whether this was a recent development.

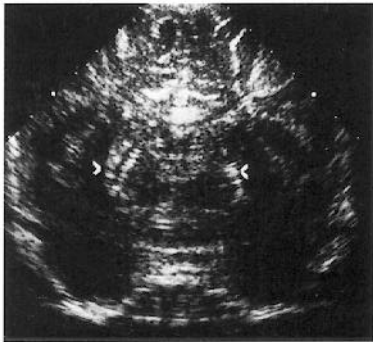
Another interesting finding is that the progression of the sonographic change of LSV occurred in as many as 85% of our patients, but there was no deterioration in the clinical course. We suggest that the progression demonstrated on sonograms does not have clinical significance, because most prenatal brain insults should be inactive after birth except in those cases with inborn errors of metabolism.

The neuropathologic finding of hypercellular arterial walls with perivascular mineralization in four patients reported by Teele et al was not found in the three patients of the series of Hughes et al (5, 11). It is clear that the controversy of perivascular mineralization can not be clarified without pathologic examination. The term *mineralizing lenticulostriate vasculopathy* may be misleading. We suggest that *sonographic lenticulostriate vasculopathy* is a more suitable name.

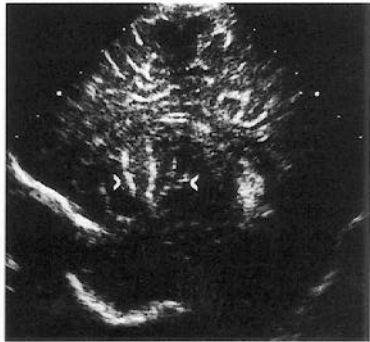
In conclusion, multiple causes, particularly the perinatal ones, may be associated with LSV as detected with sonography. We suggest that the intracranial hemodynamics in the fetus may play an important role in the pathogenesis of sonographic LSV. The clinical course of these cases was benign, despite the progression on the sonograms.

References

1. Naidich TP, Gusnard DA, Yousefzadeh DK. Sonography of the internal capsule and basal ganglia in infants, 1: coronal sections. *AJNR Am J Neuroradiol* 1985;6:909–917
2. Naidich TP, Yousefzadeh DK, Gusnard DA, Naidich JB. Sonography of the internal capsule and basal ganglia in infants, part II: localization of pathologic processes in the sagittal section through the caudothalamic groove. *Radiology* 1986;161:615–621
3. Rumack CM, Johnson ML. *Perinatal and Infant Brain Imaging*. Chicago: Year Book, 1984:197–199
4. Grant EG, Williams AL, Schellinger D, Slovis TL. Intracranial calcification in the infant and neonate: evaluation by sonography and CT. *Radiology* 1985;157:63–68
5. Teele RL, Hernanz-Schulman M, Sotrel A. Echogenic vasculature in the basal ganglia of neonates: a sonographic sign of vasculopathy. *Radiology* 1988;169:423–427
6. Toma P, Magnano GM, Mezzano P, Lazzini F, Bonacci W, Serra G. Cerebral ultrasound images in prenatal cytomegalovirus infection. *Neuroradiology* 1989;31:278–279
7. Ries M, Deeg K-H, Heininger U. Demonstration of perivascular echogenicities in congenital cytomegalovirus infection by colour Doppler imaging. *Eur J Pediatr* 1990;150:34–36
8. Donoghue V, Gillen J, Gormally S, King M. The “candlestick sign” on cerebral sonography: an indication of cerebral asphyxia. *Pediatr Radiol* 1990;20:379 (abstract)
9. Ben-Ami T, Yousefzadeh D, Backus M, Reichman B, Kessler A, Hammerman-Rozenberg C. Lenticulostriate vasculopathy in infants with infections of the central nervous system sonographic and Doppler findings. *Pediatr Radiol* 1990;20:575–579
10. Hahn JS, Ogino MT, Shew SB, Bejar R. Linear echodensities of the basal ganglia in newborn infants: etiological and electroencephalographic findings. *Ann Neurol* 1990;28:452 (abstract)
11. Hughes P, Weinberger E, Shaw DWW. Linear areas of echogenicity in the thalami and basal ganglia of neonates: an expanded association. *Radiology* 1991;179:103–105
12. Toma P, Mezzano P, Serra G. The “candlestick sign” on cerebral ultrasound. *Pediatr Radiol* 1991;21:319
13. Yamashita Y, Matsuishi T, Murakami Y, et al. Neuroimaging findings (ultrasonography, CT, MRI) in 3 infants with congenital rubella syndrome. *Pediatr Radiol* 1991;21:547–549
14. Ries M, Deeg K-H, Wölfel D, Ibel H, Maier B, Buheitel G. Colour Doppler imaging of intracranial vasculopathy in severe infantile sialidosis. *Pediatr Radiol* 1992;22:179–181
15. Weber K, Riebel Th, Nasir R. Hyperechoic lesions in the basal ganglia: an incidental sonographic finding in neonates and infants. *Pediatr Radiol* 1992;22:182–186
16. Townsend JJ, Stroop WG, Baringer JR, Wolinsky JS, McKerrow JH, Berg BG. Neuropathology of progressive rubella panencephalitis after childhood rubella. *Neurology* 1982;32:185–190
17. Estroff JA, Parad RB, Teele RL, Benacerraf BR. Echogenic vessels in the fetal thalami and basal ganglia associated with cytomegalovirus infection. *J Ultrasound Med* 1992;11:686–688
18. Pasternak JF, Groothuis DR. Regional variability of blood flow and glucose utilization within the subependymal germinal matrix. *Brain Res* 1984;299:281–288
19. De Reuck JL. Cerebral angioarchitecture and perinatal brain lesions in premature and full-term infants. *Acta Neurol Scand* 1984;70:391–395



A



B

23

23

C544 Δ
DEPTH= 120
Neo Head/V

PWR<100
0/0/V7
1/1
◆MOVE ID
PEAK \bar{V}



C

ECTOR SCAN 00TH-PEO

4.0. H

HCN 0

70

91/03/84

11:03:10

15

436484

50.48H

F 1.5.0MHz

80/070 00

A

F70

44000

F 1.5.0MHz

80/070 00

B

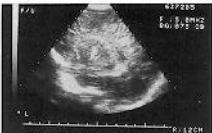F70

447200

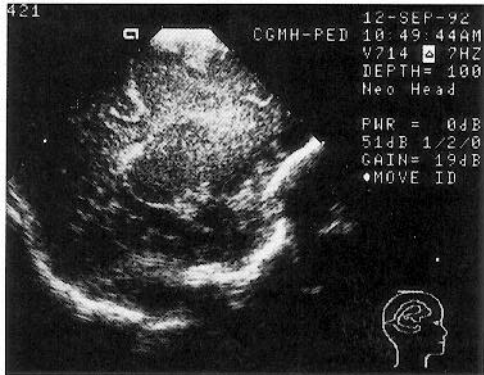
F 1.5.0MHz

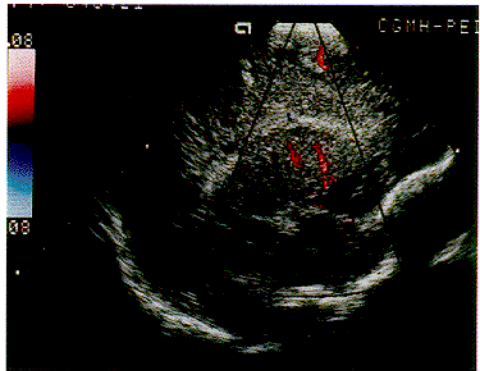
80/070 00

C



421





B