



**Providing Choice & Value**

Generic CT and MRI Contrast Agents



FRESENIUS  
KABI

CONTACT REP

**AJNR**

**Evaluation of subclavian steal with  
two-dimensional phase-contrast and  
two-dimensional time-of-flight MR angiography.**

J Drutman, A Gyorke, W L Davis and P A Turski

*AJNR Am J Neuroradiol* 1994, 15 (9) 1642-1645

<http://www.ajnr.org/content/15/9/1642>

This information is current as  
of July 30, 2025.

# Evaluation of Subclavian Steal with Two-dimensional Phase-Contrast and Two-dimensional Time-of-Flight MR Angiography

Jeff Drutman, Andrew Gyorke, Wayne L. Davis, and Patrick A. Turski

**Summary:** We describe two MR angiographic methods of diagnosing subclavian steal in each of three patients. By using phase-directional information from a single two-dimensional phase-contrast sequence, we were able to show that the direction of flow in the affected vertebral artery was reversed. The same vertebral artery showed no signal on a 2-D time-of-flight sequence with a concatenated presaturation pulse applied above each section.

**Index terms:** Subclavian steal syndrome; Arteries, vertebral; Magnetic resonance angiography (MRA); Magnetic resonance, flow studies

*Subclavian steal* refers to the retrograde flow of blood in a vertebral artery that supplies the ipsilateral shoulder and arm. It is usually caused by proximal subclavian artery stenosis or occlusion. In the presence of symptoms such as vertebrobasilar insufficiency or arm claudication, the condition is referred to as the *subclavian steal syndrome*. Atherosclerosis is the most common cause of subclavian steal (1, 2).

A recent report described the findings of subclavian steal on magnetic resonance (MR) angiography using the two-dimensional time-of-flight technique (3). The authors proved the diagnosis of subclavian steal by performing two MR angiographic sequences on each of three patients. They performed the first sequence with a spatial presaturation pulse applied above the acquisition (2-D sections) and the second with the same presaturation pulse applied below the acquisition sections. The vertebral artery with retrograde flow showed no signal on the first sequence and normal flow-related enhancement on the second sequence (3).

In this report, we demonstrate proximal subclavian artery stenosis and retrograde vertebral artery flow in three patients using 2-D phase-contrast MR angiography, which encodes veloc-

ity and therefore direction. The patients were initially examined with 2-D time-of-flight MR angiography with a superior walking (concatenated) spatial presaturation pulse. This moving presaturation pulse is used to saturate out venous flow that may interfere with the interpretation of internal carotid artery stenosis (4). In all three patients the standard 2-D time-of-flight sequence demonstrated apparent occlusion of one of the vertebral arteries.

All three patients had conventional angiograms, which showed proximal left subclavian artery stenosis or occlusion and retrograde flow in the ipsilateral vertebral artery. Two of the three patients presented with the subclavian steal syndrome. The patients were selected based on clinical symptoms and conventional angiographic findings.

## Case Report

### Patient 1

A 64-year-old white male smoker presented to the Veterans Administration Hospital with episodes of vertigo precipitated by exercise of the left arm. He had a remote history of left proximal subclavian artery stenosis requiring a prosthetic graft from the left common carotid artery to the left subclavian artery distal to the stenosis but proximal to the origin of the left vertebral artery. Physical exam showed systolic blood pressure to be 55 mm Hg less in the left arm than in the right arm. Conventional angiography showed occlusions of the proximal left subclavian artery and of the graft and retrograde left vertebral artery flow (Fig 1). There were also stenoses of both proximal internal and external carotid arteries.

We performed MR resonance angiography of the neck vessels. The 2-D time-of-flight technique using a superior walking presaturation pulse showed no signal in the left vertebral artery. Rather than performing an additional 2-D time-of-flight acquisition with the presaturation pulse applied below the acquisition volume to confirm retrograde

Received December 15, 1992; accepted after revision March 1, 1993.

From the Department of Radiology, University of Utah Medical Center, Salt Lake City (J.D., A.G., W.L.D.); and the Department of Radiology, University of Wisconsin Hospital and Clinics, Madison (P.A.T.).

Address reprint requests to Wayne L. Davis, MD, Department of Radiology, LDS Hospital, 8th Ave and C St, Salt Lake City, UT 84143.

AJNR 15:1642-1645, Oct 1994 0195-6108/94/1509-1642 © American Society of Neuroradiology



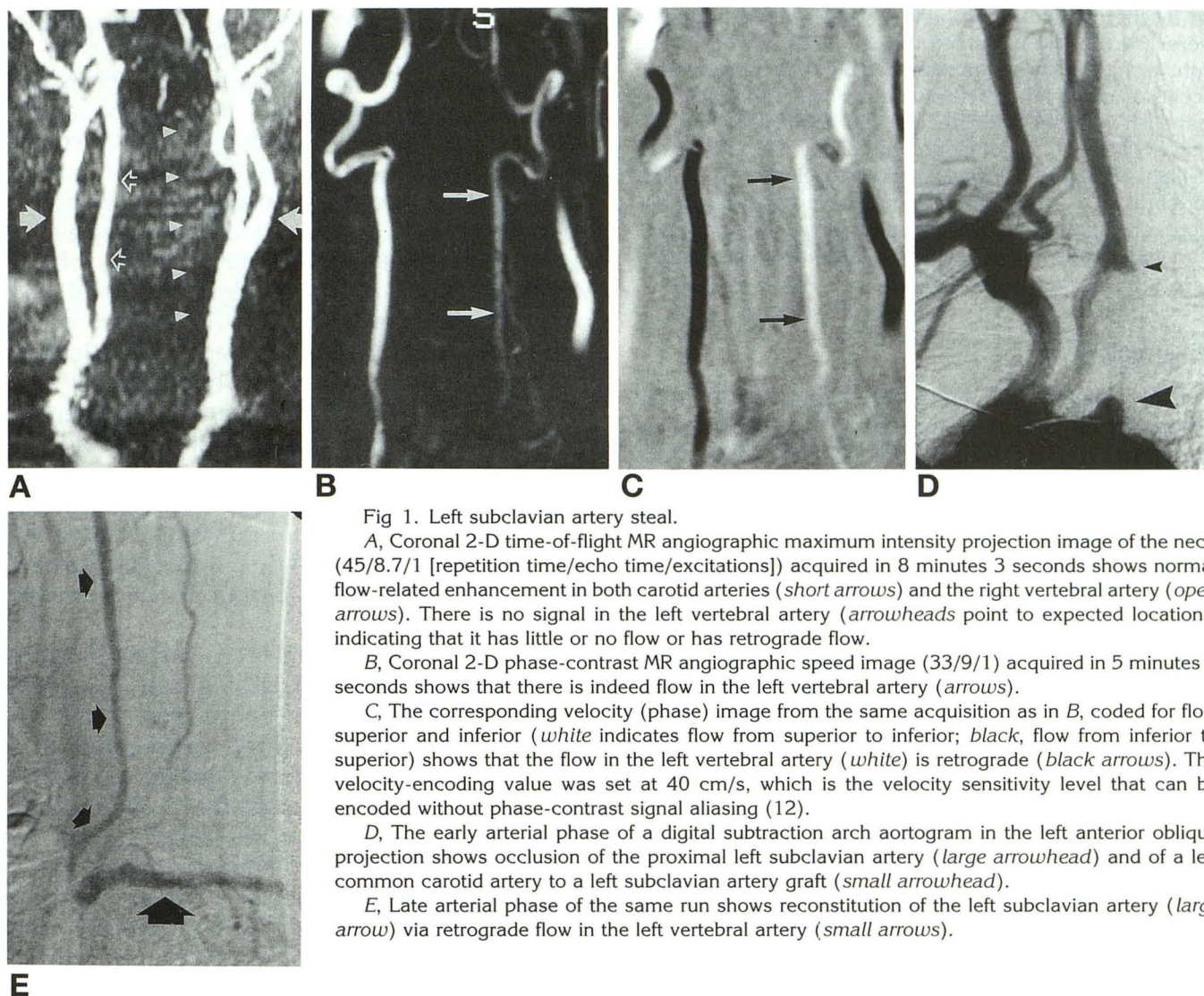


Fig 1. Left subclavian artery steal.

A, Coronal 2-D time-of-flight MR angiographic maximum intensity projection image of the neck (45/8.7/1 [repetition time/echo time/excitations]) acquired in 8 minutes 3 seconds shows normal flow-related enhancement in both carotid arteries (*short arrows*) and the right vertebral artery (*open arrows*). There is no signal in the left vertebral artery (*arrowheads* point to expected location), indicating that it has little or no flow or has retrograde flow.

B, Coronal 2-D phase-contrast MR angiographic speed image (33/9/1) acquired in 5 minutes 9 seconds shows that there is indeed flow in the left vertebral artery (*arrows*).

C, The corresponding velocity (phase) image from the same acquisition as in B, coded for flow superior and inferior (*white* indicates flow from superior to inferior; *black*, flow from inferior to superior) shows that the flow in the left vertebral artery (*white*) is retrograde (*black arrows*). The velocity-encoding value was set at 40 cm/s, which is the velocity sensitivity level that can be encoded without phase-contrast signal aliasing (12).

D, The early arterial phase of a digital subtraction arch aortogram in the left anterior oblique projection shows occlusion of the proximal left subclavian artery (*large arrowhead*) and of a left common carotid artery to a left subclavian artery graft (*small arrowhead*).

E, Late arterial phase of the same run shows reconstitution of the left subclavian artery (*large arrow*) via retrograde flow in the left vertebral artery (*small arrows*).

vertebral flow, we used 2-D phase-contrast MR angiography (phase-difference processing) (5). The phase-contrast angiograms were obtained with velocity encoding in all three orthogonal directions (anterior to posterior, superior to inferior, and right to left). The individual phase-based flow images were inspected to determine flow direction (6). This sequence (5 minutes 9 seconds) shows normal antegrade right vertebral artery flow and abnormal retrograde left vertebral artery flow on the same image (Fig 1).

#### Patient 2

A 72-year-old white male smoker presented to the Veterans Administration Hospital for evaluation of carotid stenosis diagnosed by duplex sonography 2 years ago. He denied ischemic cerebral symptoms or arm claudication. Physical exam showed bruits in both carotid arteries and the left subclavian artery. Segmental systolic blood pressure tracings measured 150 mm Hg in the right upper arm

and 100 mm Hg in the left upper arm where the wave forms were damped. Repeat duplex sonography of the neck showed proximal left subclavian artery occlusion and reversed flow in the left vertebral artery. Conventional angiography confirmed the duplex sonographic findings and more clearly defined the reconstitution of the left subclavian artery via the left vertebral artery.

Again, we performed both the 2-D time-of-flight and the 2-D phase-contrast MR angiographic techniques, which showed the apparent vertebral arterial occlusion and the retrograde flow in the left vertebral artery.

Because there were no symptoms, no surgical or angioplasty procedure was performed. The patient is being followed with serial duplex ultrasound scans for his moderate carotid stenoses.

#### Patient 3

A 58-year-old white male smoker presented to the Veterans Administration Hospital with drop attacks brought



on by the use of his left hand. Systolic blood pressures were 134 mm Hg in the left arm and 224 mm Hg in the right arm. Digital subtraction angiography documented occlusion of the left subclavian artery with retrograde flow in the left vertebral artery reconstituting the distal left subclavian artery. MR angiography using the 2-D time-of-flight technique showed apparent occlusion of the left vertebral artery. Two-dimensional phase-contrast MR angiography showed normal antegrade flow in the right vertebral artery and retrograde flow in the left vertebral artery.

## Discussion

Subclavian steal syndrome refers to the phenomenon of subclavian steal with symptoms of cerebral or arm ischemia (1, 3, 7-9). The most commonly reported symptoms of the subclavian steal syndrome are vertigo and limb paresis and paresthesias.

Conventional angiography is the definitive study to detect subclavian artery stenosis or occlusion and to show retrograde flow in the ipsilateral vertebral artery. Duplex scanning of the vertebral and subclavian arteries coupled with transcranial Doppler through the foramen magnum can provide accurate noninvasive information about the vertebrobasilar circulation (10).

MR angiography is quickly becoming one of the modalities of choice to study patients with cerebrovascular ischemia (11). The recognition of subclavian steal during the same diagnostic exam may be helpful in patient treatment decisions. MR angiography can provide information adequate to make the diagnosis of subclavian steal. At the same time, the anterior circulation also may be evaluated both extracranially and intracranially.

Retrograde flow in the vertebral artery may be inferred using 2-D time-of-flight MR angiography. Because flow-related enhancement and flow saturation are the major factors in time-of-flight imaging, lack of signal in a vertebral artery with a presaturation pulse applied above the acquisition volume suggests that flow is either absent or retrograde. A second time-of-flight sequence with the presaturation pulse applied below the acquisition volume would be needed to confirm the diagnosis. Two-dimensional phase-contrast MR angiography encodes flow direction (velocity) using bipolar gradients. The subtraction of two imaging data sets acquired with opposite bipolar gradient polarity removes the induced phase changes caused by factors

other than flow. The advantage of the phase-contrast technique over time-of-flight is that, in addition to a much shorter acquisition time, the former provides directional information about the flow in one acquisition (12-14). A major limitation to the phase-contrast technique is the user's obligation to preselect a velocity-encoding value. If the velocity-encoding value is not appropriate for the flow velocity of the vessel being imaged, ambiguous signal will occur in directional studies. To obtain accurate directional information and avoid aliasing, the velocity-encoding value should be set at a level to include all of the velocities of interest. A lower velocity-encoding value should be set when qualitative, anatomic information is needed. Most of the published phase-contrast MR angiography literature contains enough information about vessel flow velocities to enable one to choose an appropriate velocity-encoding value.

Lack of signal in the affected vertebral artery on 2-D time-of-flight MR angiography suggests retrograde flow, but the same also would be seen with no flow. Our three cases show that proximal subclavian artery stenoses or occlusion and resultant retrograde flow in the ipsilateral vertebral artery can be demonstrated on 2-D phase-contrast MR angiography using a single acquisition. These case reports suggest that 2-D phase-contrast MR angiography may be a faster, more definitive, noninvasive way to evaluate subclavian steal than 2-D time-of-flight MR angiography using inferior presaturation pulses.

## References

1. Fields W, Lemak N. Joint study of extracranial arterial occlusion, VII: subclavian steal: a review of 168 cases. *JAMA* 1972;222:1139-1143
2. Becker A, Becker M, Edwards J. Congenital anatomic potentials for subclavian steal. *Chest* 1971;60:4-13
3. Turjman F, Tournut P, Baldy-Porcher C, Laharotte J, Duquesnel J, Froment J. Demonstration of subclavian steal by MR angiography. *J Comput Assist Tomogr* 1992;16:756-759
4. Keller P, Drayer B, Fram E, Williams K, Dumoulin C, Souza S. MR angiography with two-dimensional acquisition and three-dimensional display, work in progress. *Radiology* 1989;173:527-532
5. Pelc N, Bernstein M, Shimakawa A, Glover G. Encoding strategies for three-direction phase-contrast MR imaging of flow. *J Magn Reson Imaging* 1991;1:405-413

6. Spritzer C, Pelc N, Lee J, Evans A, Sostman H, Riederer S. Rapid MR imaging of blood flow with a phase-sensitive, limited-flip-angle, gradient recalled pulse sequence: preliminary experience. *Radiology* 1990;176:255-262
7. Erbstein R, Wholey M, Smoot S. Subclavian artery steal syndrome: treatment by percutaneous transluminal angioplasty. *AJR Am J Roentgenol* 1988;151:291-294
8. Walker P, Paley D, Harris K, Thompson A, Johnston K. What determines the symptoms associated with subclavian artery occlusive disease?. *J Vasc Surg* 1985;2:154-157
9. Reivich M, Holling E, Roberts B, Toole J. Reversal of blood flow through the vertebral artery and its effect on cerebral circulation. *N Engl J Med* 1961;265:878-885
10. Schneider P, Rossman M, Bernstein E, Ringelstein E, Torem S, Otis S. Noninvasive evaluation of vertebrobasilar insufficiency. *J Ultrasound Med* 1991;10:373-379
11. Masaryk A, Ross J, DiCello M, Modic M, Paranandi L, Masaryk T. 3DFT MR angiography of the carotid bifurcation: potential and limitations as a screening examination. *Radiology* 1991;179:797-804
12. Dumoulin C, Hart H. Magnetic resonance angiography. *Radiology* 1986;161:717-720
13. Dumoulin C, Souza S, Walker M, Wagle W. Three-dimensional phase contrast angiography. *Magn Res Med* 1989;9:139-149
14. Dumoulin C. Phase-contrast magnetic resonance angiography. *Neuroimaging Clin North Am* 1992;2:657-676