



## Get Clarity On Generics

Cost-Effective CT & MRI Contrast Agents

 FRESENIUS  
KABI

[WATCH VIDEO](#)

# AJNR

## **Baló concentric sclerosis: MR diagnosis.**

J H Korte, E P Bom, L D Vos, T J Breuer and J H Wondergem

*AJNR Am J Neuroradiol* 1994, 15 (7) 1284-1285

<http://www.ajnr.org/content/15/7/1284>

This information is current as  
of August 20, 2025.

# Baló Concentric Sclerosis: MR Diagnosis

J. H. Korte, E. P. Bom, L. D. Vos, T. J. M. Breuer, and J. H. M. Wondergem

**Summary:** An antemortem MR diagnosis of concentric sclerosis was made. After corticosteroid therapy the patient's symptoms diminished, and repeat MR revealed a decrease in the size of the lesion.

**Index terms:** Demyelinating disease; Sclerosis; Brain, magnetic resonance

Concentric sclerosis is a rare demyelinating disease. It was first described by Marburg (1) in 1906 as "acute multiple sclerosis." In 1928 Baló (2) reported a case of a 23-year-old man with right hemiparesis, aphasia, and papilledema. At autopsy, multiple lesions with an unusual concentric pattern of demyelination were found in the white matter of the right cerebral hemisphere. Baló was the first to emphasize this concentric pattern. The characteristic pattern of demyelination of Baló concentric sclerosis has intrigued researchers since. Fewer than 50 cases have been published. Most cases of Baló concentric sclerosis were diagnosed at postmortem examinations. Gabern et al (3) reported a diagnosis by needle biopsy. Spiegel et al (4) reported a case of Baló concentric sclerosis based on magnetic resonance (MR) findings.

An antemortem diagnosis of concentric sclerosis by MR is presented in this case report. There is a striking resemblance between the MR appearances in our patient and the histopathologic features in the case reported by Baló in 1928.

## Case Report

A 25-year-old woman, 34 weeks pregnant, had progressive gait disturbances. Neurologic examination revealed a left hemiparesis, more marked in the leg. Abdominal reflexes were absent. There were no sensory disturbances. Cranial computed tomographic examination

revealed a focal, round, low-density lesion in the right parietal lobe.

Within 2 weeks, there was a rapid progression of the symptoms to complete left hemiparalysis and a left central facial palsy. At 36 weeks of pregnancy, she delivered a healthy son by cesarean section.

Repeat contrast-enhanced computed tomography revealed a larger hypodense lesion with rim enhancement (Fig 1A). A tentative diagnosis of an intracranial tumor led to cerebral angiography, which showed a hypovascular zone in the same area. Stereotactic needle biopsy revealed inflammatory tissue, possibly caused by multiple sclerosis.

Brain MR (0.5 T) revealed a 5-cm-diameter lesion with a concentric pattern in the white matter on the right side. There was no mass effect. An abrupt termination of the concentric rings was present where the lesion abutted on the gray matter of the brain. On T1-weighted images the lesion showed alternating intermediate- and low-signal bands with rim enhancement after intravenous administration of gadopentetate dimeglumine (Fig 1B). The lesion had a high signal intensity on both the proton density- (Fig 1C) and T2-weighted sequences. In the left cerebral hemisphere a few small oval hyperintense lesions were seen on proton density-weighted images. Based on these MR findings, the diagnosis of Baló concentric sclerosis was made.

With corticosteroid therapy the left hemiparesis markedly improved, and left central facial palsy completely resolved within a few weeks. Corticosteroid therapy was subsequently discontinued.

Repeat MR obtained 6 months later revealed a remarkable decrease in the size of the lesion (Fig 1D). The concentric pattern was still present. The lesion did not enhance after intravenous gadopentetate dimeglumine. At follow-up after 1 year, no neurologic symptoms were detected.

## Discussion

In the past, diagnosis of Baló concentric sclerosis was made only at postmortem examination. Autopsy specimens of this rare type of

Received December 8, 1992; accepted pending revision January 21, 1993; revision received February 8.

From Department of Radiology, Catharina Hospital, Eindhoven (J.H.K., E.P.B., L.D.V., J.H.M.W.), and Department of Neurology, St Anna Hospital, Geldrop (T.J.M.B.), the Netherlands.

Address reprint requests to Jan H. Korte, MD, Catharina Hospital, Department of Radiology, Michelangelolaan 2, PO Box 1350, 5602 ZA Eindhoven, The Netherlands.

AJNR 15:1284-1285, Aug 1994 0195-6108/94/1507-1284 © American Society of Neuroradiology



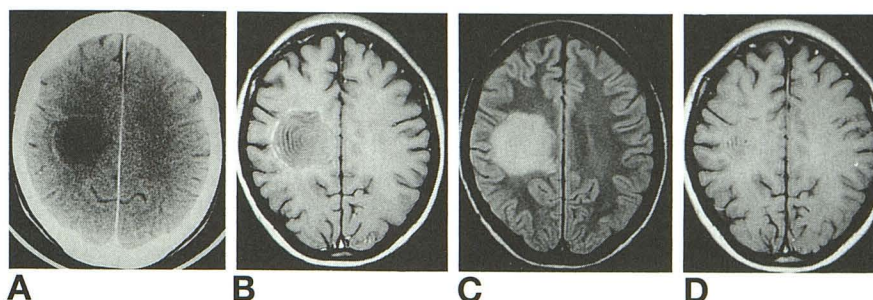


Fig 1. A, Postcontrast CT performed 2 weeks after the onset of the left hemiparesis shows a large hypodense lesion with rim enhancement in the right parietal lobe.

B, Postcontrast axial spin-echo T1-weighted (550/25/2 [repetition time/echo time/excitations]) image. The typical concentric architecture of the lesion is discernible, as is rim enhancement.

C, Axial spin-echo proton density-weighted (2371/25) image. The lesion has high signal intensity. Note that it does not invade the cerebral cortex.

D, Repeat postcontrast axial spin-echo T1-weighted (480/25) image, obtained 6 months after starting corticosteroid therapy. A marked decrease in the size of the lesion is observed. The typical concentric pattern is still present.

demyelinating disease revealed areas of focal demyelination in cerebral white matter. Some lesions had a characteristic concentric or lamellar pattern, consisting of alternating preserved myelinated and demyelinated bands. The characteristic concentric or lamellar configuration of demyelination can have various macroscopic presentations (5): (a) parallel rings with a storm center; (b) distorted rings, deformed by the adjacent cortex; (c) a rosetta or carnation pattern; (d) parallel bars; and (e) a segmental or quadrant pattern with a concentric storm center.

Baló concentric sclerosis is thought to be a variant of classic multiple sclerosis (Charcot type) or diffuse sclerosis, because transitional forms have been observed in both disorders (5, 6). Baló concentric sclerosis usually affects young adults; compared with the classic type of multiple sclerosis, Baló concentric sclerosis usually runs a more rapid progressive course (3, 5, 7). The survival period may be 3 to 5 years, but longer survival also has been reported. It is remarkable that our patient completely recovered and did not show any progression within 1 year.

The concentric demyelinating lesion never invades the cerebral cortex (Fig 1C), contrary to what sometimes is seen in multiple sclerosis plaques (5, 7). Other clinical aspects of Baló concentric sclerosis are: (a) the acute onset of the early manifestations; (b) earliest symptoms that frequently suggest a space-occupying lesion; and (c) marked motor symptoms in many of the cases (5).

In our case, the antemortem diagnosis of Baló concentric sclerosis was based solely on MR findings. There is a striking resemblance between the MR appearance and the histopathologic features in the case reported by Baló. Follow-up showed that the improvement of clinical symptoms, after corticosteroid therapy, coincided with regression of the lesion on MR.

Our case demonstrates that MR in Baló concentric sclerosis may reflect the concentric pattern reported on pathologic examination.

## References

1. Marburg O. Die sogenannte "akute multiple Sklerose" (Encephalomyelitis periaxialis scleroticans). *Jahrb Neuro Psychiatry* 1906; 27:213-312
2. Baló J. Encephalitis periaxialis concentrica. *Arch Neurol Psychiatry* 1928;19:242-264
3. Gabern J, Spence AM, Alvord EC. Baló's concentric demyelination diagnosed premortem. *Neurology* 1986;36:1610-1614
4. Spiegel M, Krüger H, Hoffmann E, et al. MRI study of Baló's concentric sclerosis before and after immunosuppressive therapy. *J Neurol* 1989;236:487-488
5. Courville CB. Concentric sclerosis. In: Vinken PJ, Bruyn GW, eds. *Handbook of Clinical Neurology*. Vol 9. Amsterdam: North Holland, 1970:437-451
6. Kuroiwa Y. Concentric sclerosis. In: Koetsier JC, ed. *Handbook of Clinical Neurology*. Vol 3. Amsterdam: Elsevier, 1985:409-417
7. Valk J, van der Knaap MS. Multiple sclerosis, neuromyelitis optica, concentric sclerosis, and Schilder's diffuse sclerosis. In: Valk J, van der Knaap MS, eds. *Magnetic Resonance of Myelin, Myelination, and Myelin Disorders*. Berlin: Springer-Verlag, 1989:179-205