



Get Clarity On Generics

Cost-Effective CT & MRI Contrast Agents



FRESENIUS
KABI

WATCH VIDEO

AJNR

Proton MR spectroscopy in patients with seizure disorders.

S N Breiter, S Arroyo, V P Mathews, R P Lesser, R N Bryan and P B Barker

AJNR Am J Neuroradiol 1994, 15 (2) 373-384

<http://www.ajnr.org/content/15/2/373>

This information is current as
of August 16, 2025.

Proton MR Spectroscopy in Patients with Seizure Disorders

Steven N. Breiter, Santiago Arroyo, Vincent P. Mathews, Ronald P. Lesser, R. Nick Bryan, and Peter B. Barker

PURPOSE: To evaluate the ability of proton MR spectroscopy to detect metabolic abnormalities in the seizure focus of humans with epilepsy. **METHODS:** Single-voxel MR spectroscopy and MR imaging was performed in a group of 13 patients with a variety of seizure disorders and in the temporal lobes of 14 healthy volunteers. Signals from choline, creatine, N-acetyl-L-aspartate, and lactate were quantitated in both the epileptogenic focus and the contralateral brain region. **RESULTS:** In normal temporal lobe, concentrations of choline, creatine, and N-acetyl-L-aspartate were 2.0 ± 0.7 , 7.8 ± 1.9 , and 11.0 ± 2.1 $\mu\text{mol/g}$ wet weight, respectively, with no detectable lactate. In all patients, a reduction in the N-acetyl-L-aspartate signal was observed in the electrically defined (scalp electroencephalogram) seizure focus compared with the mirror-image contralateral side. Lactate was elevated only in patients who had seizures during or immediately before the MR examination. Seven of 13 patients studied had normal MR examinations. **CONCLUSIONS:** Proton spectroscopy demonstrates alterations in N-acetyl-L-aspartate and lactate levels that can be used to locate the epileptogenic focus and may be a useful adjunctive diagnostic technique for the evaluation of patients with seizures who are eligible for resective surgery.

Index terms: Magnetic resonance, spectroscopy; Brain, metabolism; Brain, magnetic resonance; Brain, temporal lobe; Seizures

AJNR Am J Neuroradiol 15:373–384, Feb 1994

Epilepsy is a common disorder, affecting 0.27% to 0.64% of the American population at any given time with an incidence of 30.9 to 56.8 per 100 000 (1). Based upon the 1980 census, more than 1.4 million Americans have epilepsy. There is a multitude of causes of epilepsy, including tumors, vascular malformations, and developmental abnormalities, although perhaps most frequently the cause is unknown. The use of magnetic resonance (MR) spectroscopy for the

metabolic investigation of animal models of epilepsy was pioneered by the Yale group (2–7). There also have been reports of MR spectroscopy of humans with seizure disorders (8–12); interictally, seizure foci have been characterized as being alkalotic using phosphorus (^{31}P) MR spectroscopy, and this has been proposed as a means of lateralization of the seizure foci (9, 11, 12). However, the relatively coarse spatial resolution of ^{31}P MR spectroscopy ($\sim 30\text{-cm}^3$ voxel size for human brain studies at 1.5 T) limits the application of this technique to relatively large focal abnormalities. Proton spectroscopy has a considerable sensitivity advantage, which allows the acquisition of voxel sizes of less than 1 cm^3 (13). A report has been published on two patients with Rasmussen syndrome (who both had abnormal MR scans) using proton MR spectroscopy. Both patients showed decreased N-acetyl-L-aspartate, and the single patient who had seizures during spectral acquisition showed increased lactate (8). Because the N-acetyl-L-aspartate signal is believed to be solely of neuronal origin (14), the reduction in N-acetyl-L-aspartate has been attributed to neuronal loss within the seizure focus, which is also a common histologic finding (15–

Received December 10, 1992; accepted pending revision January 26, 1993; revision received February 22.

Presented in part at the 30th Annual Meeting of the American Society of Neuroradiology, St. Louis, Mo, May 30–June 5, 1992, and at the 11th Annual Meeting of the Society of Magnetic Resonance in Medicine, Berlin, Germany, August 8–14, 1992. This work was partially supported by the ASNR-Berlex Neuroradiology grant for 1991–1992 (to S.N.B.).

From the Departments of Radiology (S.N.B., R.N.B., P.B.B.) and Neurology (S.A., R.P.L.), Johns Hopkins University School of Medicine, Baltimore, Md. Dr Mathews is now at the Department of Radiology, Bowman Gray School of Medicine, Winston-Salem, NC.

Address reprint requests to Peter B. Barker, DPhil, Division of NMR Research, Department of Radiology and Radiological Science, The Johns Hopkins University School of Medicine, The Johns Hopkins Hospital, 600 N. Wolfe Street, MRI 110, Baltimore, MD 21287.

AJNR 15:373–384, Feb 1994 0195-6108/94/1502-0373

© American Society of Neuroradiology

18). This study was undertaken to evaluate the use of quantitative proton MR spectroscopy as an adjunctive diagnostic technique for the evaluation of epileptogenic foci in a group of patients with a variety of seizure disorders.

Materials and Methods

Thirteen patients, ages 22 months to 51 years (average 20.5 years, SD 19.5 years, six male and seven female), with either a primary diagnosis of intractable epilepsy or acute onset seizures were studied. All patients had scalp electroencephalogram location of the seizure focus by neurologists specializing in epilepsy (S.A. and R.P.L.) before MR spectroscopy. Spectroscopy voxels were localized based upon electroencephalographic findings (eg, S.N.B., V.P.M., or R.N.B. were aware of the lobe involved but not the side). Two of these patients had depth electrode confirmation of the seizure focus. Of the 13 patients, seven were diagnosed with idiopathic temporal lobe epilepsy, three with Rasmussen syndrome (1 pathologically proved), one with neuronal migration abnormality, one with Sturge-Weber syndrome; and one with acute herpes encephalitis. Eight of the 13 patients had complex partial seizures, and five patients had focal hemispheric seizures (see Table 2). The onset of the seizure disorder ranged from 7 months to 49 years before this investigation in 12 of 13 patients; the patient with herpes encephalitis developed status epilepticus 22 hours before the investigation but stopped approximately 2 hours before the MR examination. Electroencephalographic monitoring was not performed during the MR examination for any patient because of signal degradation related to the electroencephalogram leads.

All MR studies were performed on General Electric (Milwaukee, Wis) 1.5-T Signa scanners using the standard quadrature bird cage head coil. All patients underwent a routine spin-echo MR examination consisting of sagittal T1-weighted (500/20/1 [repetition time/echo time/excitations], 256 × 196 image matrix, 5-mm section thickness, 1.5-mm gap) and axial double echo (3000/30, 100/0.5–1.0, 256 × 196 image matrix, 5-mm section thickness, interleaved scan) images. Coronal fast spin-echo double-echo images (4500/21, 105/2; echo train 8, 512 × 256 image matrix, electrocardiogram-gated, 4-mm section thickness, 2-mm gap) were obtained in one patient (patient 1). Three-dimensional coronal spoiled gradient-recalled steady-state signal acquisition images (35/5/2; 45° flip angle, 256 × 256 image matrix, 1.5-mm section thickness, and ~1-mm in-plane resolution) were also acquired in three patients with temporal lobe seizures (patients 1, 3, and 6). T1-weighted coronal images (500/20/1, 256 × 196 image matrix, 5-mm section thickness, 2-mm gap) were acquired in another two patients with temporal lobe epilepsy (patients 2 and 7). Six patients were studied with axial T1-weighted images before and after administration of gadopentetate dimeglumine (patients 4, 8, 9, 10, 11, and 13).

In the five patients with coronal T1-weighted or 3-D spoiled gradient-recalled steady-state signal acquisition se-

quences, temporal lobe and hippocampal volumes were quantitated on a 3-D work station (ISG Allegro, Toronto, Ontario, Canada) (19–21). The boundaries of the temporal lobes and hippocampal formations were defined as follows: The most posterior section evaluated for volumetric determination of both the temporal lobe and hippocampal formation is the coronal section where the posterior commissure is present in the midsagittal plane. Anteriorly, the temporal lobe is completely surrounded by cerebrospinal fluid (CSF). The more posterior portions of the temporal lobe are circumscribed by CSF laterally, inferiorly, and medially. The superior boundary defining the temporal stem is disarticulated from the temporal lobe as described by previous investigators (20, 22, 23). The boundaries of the hippocampal formations were manually traced on each section. The superior margin of the hippocampal formation is easily separated from the CSF in the choroid fissure-temporal horn complex. The bright alveus serves as a distinguishable boundary to separate the hippocampus from the amygdala on more anterior sections. The lateral boundary is formed by the temporal horn. The inferior margin is bounded by the gray matter of the subiculum. The medial boundary is delineated by CSF of the uncus cistern. The separation of hippocampal subiculum from parahippocampal gyrus is determined by configuration rather than tissue contrast. Three neuroradiologists (S.N.B., V.P.M., and R.N.B.) evaluated the MR images for abnormal signal intensity, mass, or atrophy.

Local proton spectra were recorded with either the stimulated-echo acquisition mode (STEAM) (24) or point-resolved spectroscopy (25, 26) pulse sequences. Spectra were recorded from the electroencephalogram-defined seizure foci and from a mirror-image contralateral control volume in all patients. To record water-suppressed spectra, in the case of the STEAM sequence, single chemical shift selective pulses (27) were applied before the sequence and between the second and third section selection pulses of the STEAM sequence. The chemical shift selective pulses were single-lobe sinc functions of 15 msec duration, giving a saturation band width of $\Delta\nu_{1/2} \approx 140$ Hz. In the case of the PRESS sequence, three successive chemical shift selective pulses were applied before the sequence with a band width of 50 Hz (28). Typical acquisition parameters were 3000/270, 52-msec mixing time, 128 scans, and 8-cm³ voxel size. Spectra were processed with a line broadening of 3 Hz and convolution-difference filtering as described previously (29) and analyzed using a time-domain, nonlinear, least squares fitting program (30). The convolution-difference filter was applied to remove broad baseline signals, which would otherwise give rise to an overestimation of the metabolite signal intensities. Spectra with incomplete water suppression were also processed with a time-domain high pass digital convolution filter (31). Localized water signals (which were used as a reference for quantitation purposes) were recorded under fully relaxed, short-echo-time conditions (10/25/11, four scans) from the same voxels as the water-suppressed spectra in both the seizure focus and in the contralateral normal brain. The exact choice of spectroscopy pulse sequence and MR imaging

protocol depended on the details of the patient's disease (temporal versus nontemporal lobe) and the scanner available at the time of the examination. One patient was also evaluated using single-section, 2-D chemical shift imaging in the coronal plane. The acquisition parameters were 1700/270, 15-mm section thickness, 24 cm field of view, and $32 \times 32 \times 1024$ image matrix with a nominal voxel size of 0.8 cm^3 .

Calculation of absolute metabolite concentrations was performed using the cerebral water signal as an internal intensity reference as described previously (29). The water and metabolite signals were corrected for T1 and T2 relaxation (these corrections were virtually negligible for the water signals, which were recorded under long-repetition-time, short-echo-time conditions), and the metabolite signals were also corrected for the partial saturation effects of the water-suppression pulses. The water signal was corrected for the additional receiver attenuation, which was required to prevent overload of the spectrometer analog-to-digital recorder. Metabolite concentrations were then calculated from the ratio of the metabolite and water signals, assuming a cerebral water content of 43.0 mmol/g wet weight (32).

Proton spectra and MR images were also recorded from the temporal lobes of 14 healthy volunteers (ages 21 to 43 years, average 31.5, SD 6.5, nine men, five women) for comparison with patients with temporal lobe epilepsy. All spectra (patients and volunteers) were of sufficient quality to allow quantitative analysis.

Results

A representative spectrum from the temporal lobe of a healthy volunteer is shown in Figure 1. Typically, spectral line widths from the temporal lobe region were often larger than those found in other, more superior, regions of the brain. This resulted in proton spectra with poorer resolution and reduced water-suppression factors. Table 1 contains the mean and SD concentrations of N-acetyl-L-aspartate, creatine, and choline from the control population group. Lactate was not detectable in any of the healthy volunteers using the above protocols. Representative spectra from the epileptogenic foci and contralateral control voxels, and the associated MR images, from various patients are illustrated in Figures 2, 3, 4, 5, 6, and 7. Figure 8 illustrates the N-acetyl-L-aspartate levels from the seizure foci and contralateral region in all patients, and Figure 9 shows the ratio of N-acetyl-L-aspartate to creatine. Tables 2, 3, and 4 give the metabolite (choline, creatine, N-acetyl-L-aspartate, and lactate) concentrations and MR findings (normal/abnormal) for the same patients as in Figure 8.

N-acetyl-L-aspartate concentration was decreased, compared with the contralateral control

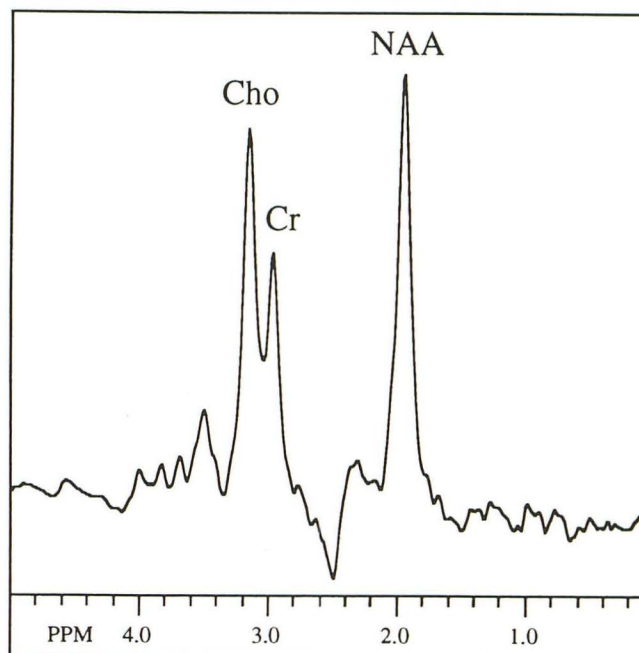


Fig. 1. Normal brain (volunteer). Proton spectrum from normal mesial temporal lobe recorded using the PRESS sequence. (See text for details.)

TABLE 1: Concentration of choline, creatine and N-acetyl-L-aspartate ($\mu\text{mol/g}$ wet weight) in frontal lobe white matter, thalamus, and temporal lobe of the normal brain

Region	n	Choline	Creatine	N-Acetyl-L-Aspartate
Frontal lobe white matter ^a	10	1.9 ± 0.5	10.6 ± 1.3	16.6 ± 2.3
Thalamus ^a	10	2.0 ± 0.4	11.6 ± 2.0	17.2 ± 1.3
Temporal lobe	14	2.0 ± 0.7	7.8 ± 1.9	11.0 ± 2.1

^a From Barker et al (29).

voxels, in the epileptogenic focus of all patients ($P < .0002$) (Table 5); 53.8% (7 of 13) of these patients had no detectable abnormality on MR. The difference was also statistically significant for the temporal lobe and nontemporal lobe subgroups, $P = .0135$ and $P = .0022$, respectively (Tables 3A and 3B). Temporal lobe N-acetyl-L-aspartate levels of the contralateral control voxels were consistent with the N-acetyl-L-aspartate levels determined in healthy volunteers (Tables 1 and 3A).

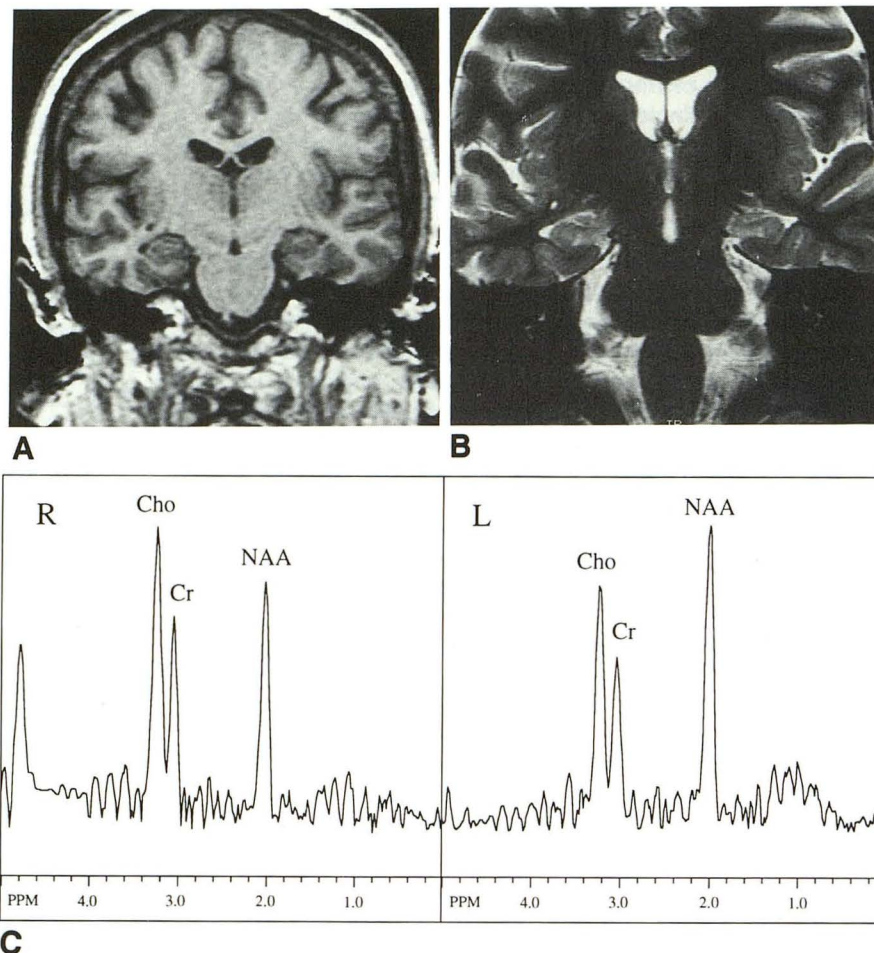
Lactate was increased in three patients; two of these had clinical symptoms of epilepsy partialis continua (Rasmussen syndrome proved pathologically in one and presumptive in the other), and the third was the patient with acute encephalitis, whose seizures stopped 2 hours before examination. The two patients with Rasmussen syndrome were the only patients who had seizures during

Fig. 2. Case 1: 28-year-old woman with intractable right temporal lobe seizures with normal MR scan.

A, Coronal T1-weighted, 3-D spoiled gradient-echo image (34/5/1).

B, Coronal fast spin-echo T2-weighted image (5000/105/2).

C, Proton spectra from 2-D chemical shift imaging data set reveals decreased N-acetyl-L-aspartate in the seizure focus on the right side.



the examination. Lactate was highest in the patient who had a temporal lobectomy and subsequent pathological verification of Rasmussen syndrome (patient 4). The third patient with epilepsy partialis continua (presumed Rasmussen syndrome, patient 12) did not have observable lactate but was not clinically having seizures at the time of examination. The remaining nine patients who were interictal and had no seizure activity for at least 24 hours before MR spectroscopy did not have observable lactate peaks. Lactate was not detected in the region contralateral to the seizure focus in any patient except patient 4. This patient was subsequently found to have bilateral temporal lobe abnormalities, as demonstrated by a shift in the electroencephalographic seizure focus to the right temporal lobe after left temporal lobectomy and subsequent left hemispherectomy.

Five of the seven patients with temporal lobe epilepsy had normal MR scans. Temporal lobe and hippocampal volumes were measured in four of these patients (Table 6). There was no significant asymmetry of the hippocampi demonstrated

by either morphologic appearance or volume measurement. Patient 5 had a normal routine MR without coronal images for specific hippocampal evaluation. One of the two patients with an abnormal MR scan had hippocampal atrophy evident as a small, irregularly shaped hippocampus on the side of epileptogenesis, which was confirmed by volume measurements (volume of the right hippocampus minus left hippocampus; difference in hippocampal formation volume = -0.31 cm^3) as the only finding (Fig 4). The other patient with an abnormal MR had Rasmussen syndrome with T2 prolongation, consistent with inflammatory changes, evident on the long-repetition-time sequences in the anterior temporal lobe (Fig 5). Anterior temporal lobe volume measurements did not reveal any statistically significant difference between right and left sides, although the range of difference measurements (right anterior temporal lobe volume minus left anterior temporal lobe volume) ($19\text{--}21$) was large (17.29 cm^3 to -8.75 cm^3). Individual difference measurements between right and left temporal lobes were not predictive of seizure lateralization

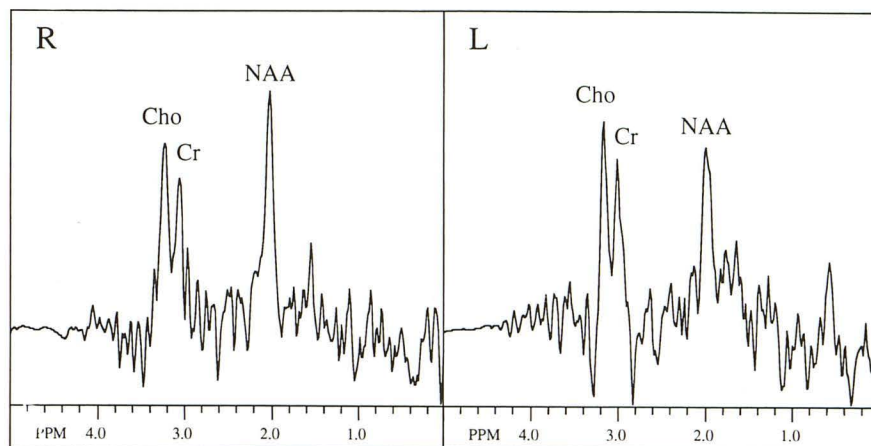


Fig. 3. Case 2: 35-year-old man with complex partial seizures of left temporal lobe origin with normal MR scan. Proton (STEAM) spectra show decreased N-acetyl-L-aspartate in the seizure focus (*left*) relative to the control side (*right*).

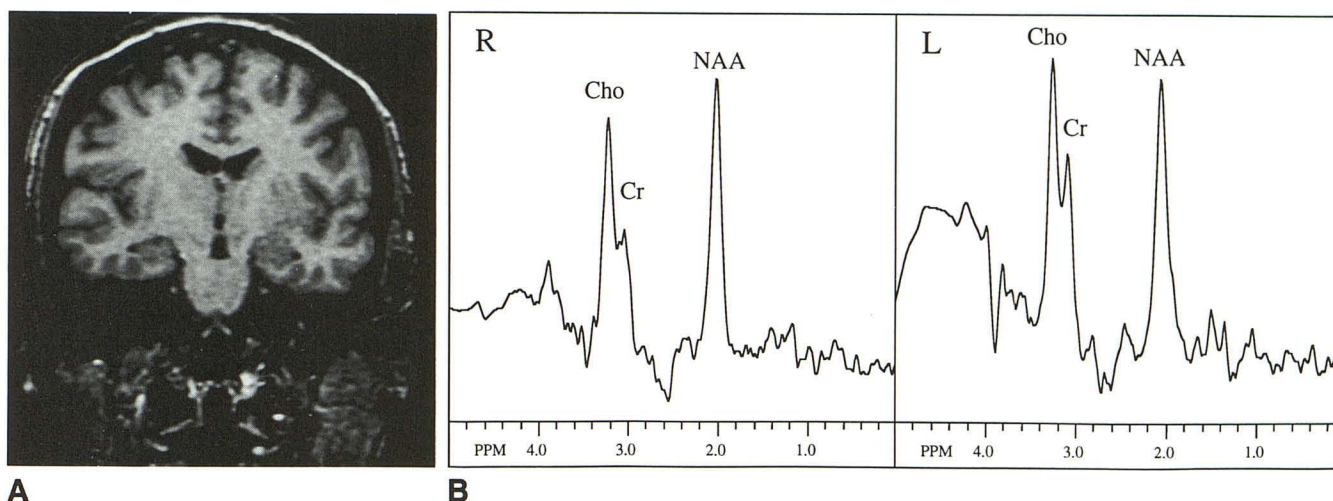


Fig. 4. Case 3: 46-year-old woman with complex partial seizures of right temporal lobe origin with right hippocampal atrophy. The hippocampus is small and irregular, but no signal abnormality is seen on long-repetition-time images.

A, Coronal T1-weighted, 3-D spoiled gradient-echo.

B, Proton (PRESS) spectra visually exhibit similar N-acetyl-L-aspartate levels; quantitation (Table 3A) reveals a small reduction of N-acetyl-L-aspartate in the seizure focus on the right (7.0 versus 9.6 mmol/g wet weight).

with smaller temporal lobes on the normal side in 2 of 5 patients.

Two of the six patients with nontemporal lobe epilepsy had normal MR scans; one patient had complex partial seizures of temporoparietal origin (patient 8), and the other patient had epilepsy partialis continua (presumptive Rasmussen syndrome) with the epileptogenic zone in the left central frontal region (Fig 6). Four patients with nontemporal lobe seizures had abnormal MR scans. The patient with Sturge-Weber syndrome (Fig 7) had right cerebral hemiatrophy, leptomeningeal enhancement after contrast injection consistent with cerebral angiomas, and cortical calcification on computed tomography. One patient had an occipital neuronal migration abnormality consistent with gray matter heterotopia. Another patient with epilepsy partialis continua

(presumptive Rasmussen syndrome) had white matter hyperintensity on the long-repetition-time sequences in the right parietal lobe (patient 12). The patient with acute herpes encephalitis had subtle cortical hyperintensity in the postcentral sulcus region on the left and no enhancement with gadopentetate dimeglumine.

Discussion

Normal temporal lobe N-acetyl-L-aspartate and creatine concentrations measured in this study are significantly lower than other regions of the brain, such as frontal lobe or thalamus (29). Choline concentrations in these three regions are equal, however. Inasmuch as there are regional variations in metabolite concentrations in normal brain, it is important that spectroscopic findings

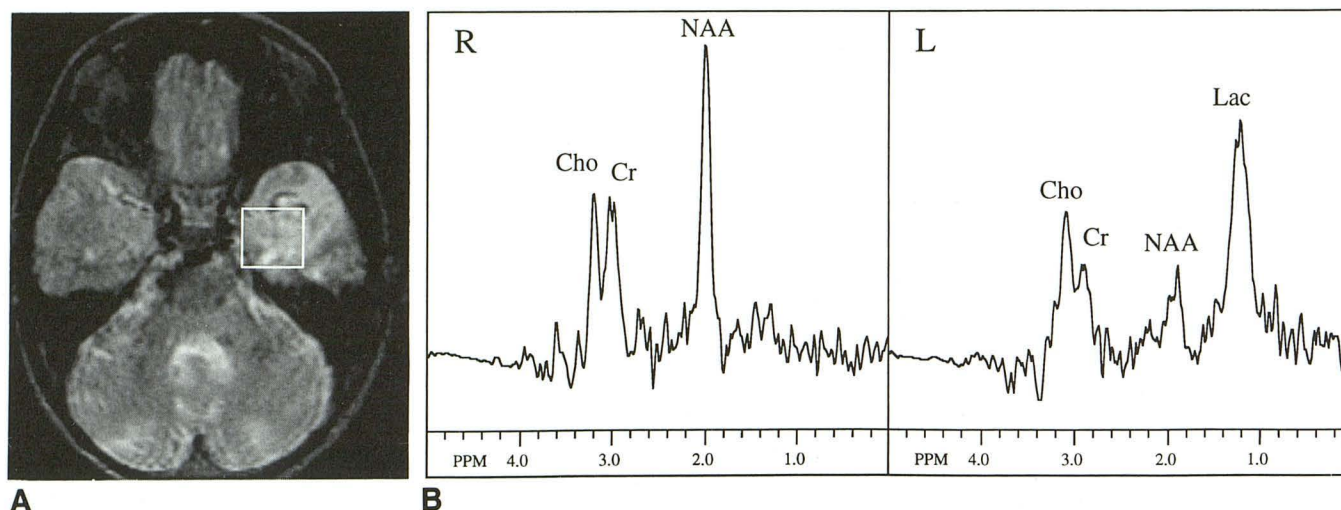
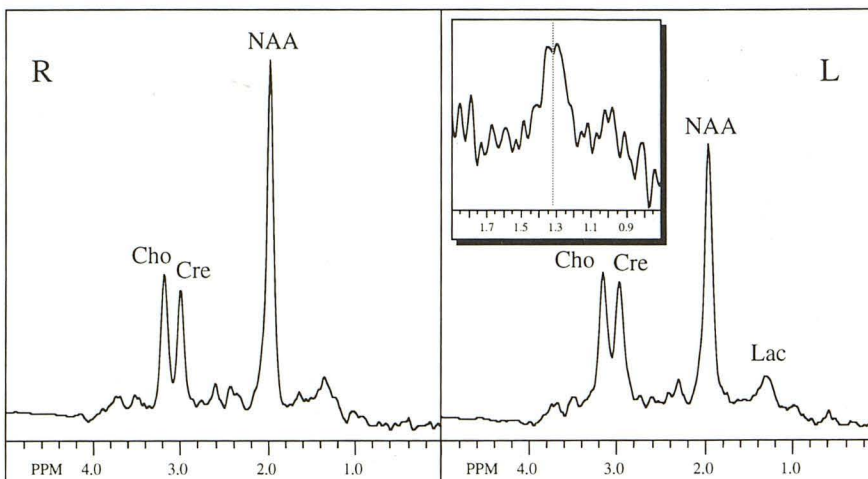


Fig. 5. Case 4: 6-year-old boy with Rasmussen syndrome and left temporal lobe complex partial seizures. Prolongation of T1 and T2 relaxation times in the left anterior temporal lobe. Normal right temporal lobe.

A, Axial T2-weighted image (3000/100/1).

B, Proton (STEAM) spectra show marked reduction in N-acetyl-L-aspartate in the left anterior temporal lobe along with marked increase in lactate. A small lactate peak in the right temporal lobe.

Fig. 6. Case 9: 5½-year-old boy with epilepsy partialis continua with left hemispheric seizures and normal MR scan. Seizure focus identified in the left central frontal area. Proton (PRESS) spectra reveal decreased N-acetyl-L-aspartate in seizure focus on the left. A small lactate peak is also visible at 1.31 ppm (the inset shows chemical shift and characteristic coupling patterns). No lactate is seen on the right side.



are compared with anatomically similar contralateral control voxels for the purpose of lateralization of the seizure foci. The increased water line width of the temporal lobe, compared with other brain regions, is presumably attributable to the magnetic susceptibility effect arising from the air-tissue interface at the petrous air cells. The increased line width gives rise to significantly worse resolution, water suppression and signal-to-noise ratios, and may be one of the limiting factors in the applicability of proton MR spectroscopy to temporal lobe epilepsy. Signal-to-noise ratios can be improved by use of the PRESS sequence, which has better sensitivity than STEAM (26).

A significant reduction of N-acetyl-L-aspartate in the epileptogenic focus was detected in all of our patients. A possible explanation for the reduction of the N-acetyl-L-aspartate signal is neuronal loss within the epileptogenic focus, because N-acetyl-L-aspartate is presumed to be a neuronal marker (14). However, the origin of the N-acetyl-L-aspartate signal in proton spectra is somewhat controversial, and there is a certain amount of contradictory evidence concerning its neuronal specificity. For instance, although there is some disagreement about the absolute concentration of N-acetyl-L-aspartate (as measured by MR) in normal brain, most in vivo MR-derived concentration values are somewhat higher than those

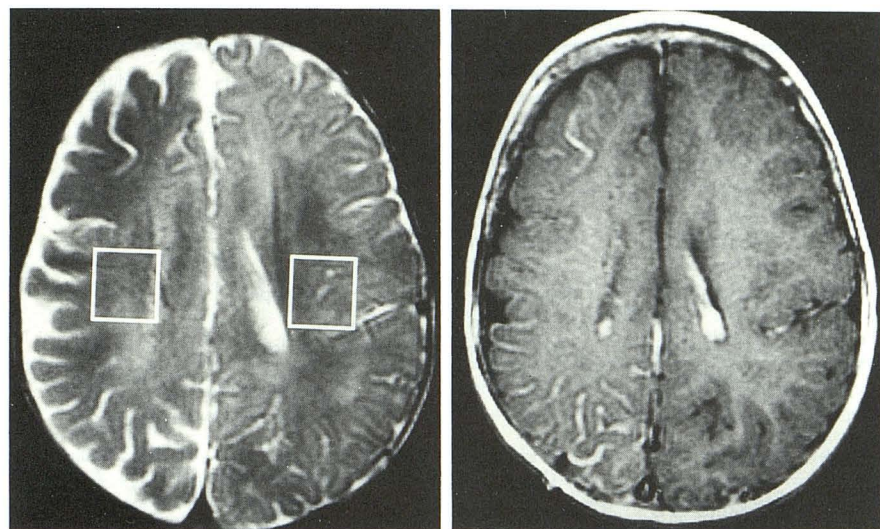


Fig. 7. Case 10: 22-month-old girl with Sturge-Weber syndrome and right hemispheric focal seizures. MR scan shows right cerebral hemiatrophy and leptomeningeal enhancement, with gadopentetate dimeglumine, consistent with cerebral angiomas.

A, Axial T2-weighted MR image shows right cerebral hemiatrophy without focal lesions (3000/100/1).

B, Axial T1-weighted, contrast-enhanced MR image (500/20/1).

C, Proton (STEAM) spectra reveal decreased N-acetyl-L-aspartate in the right cerebral hemisphere.

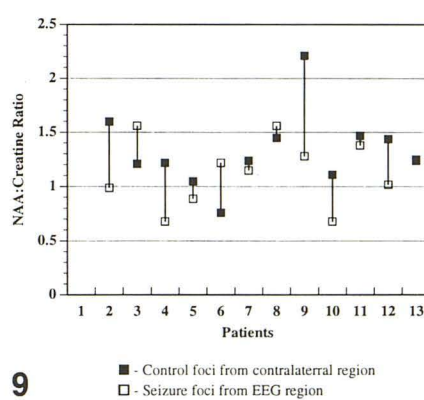
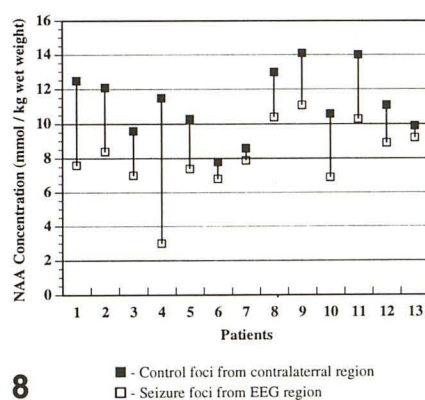
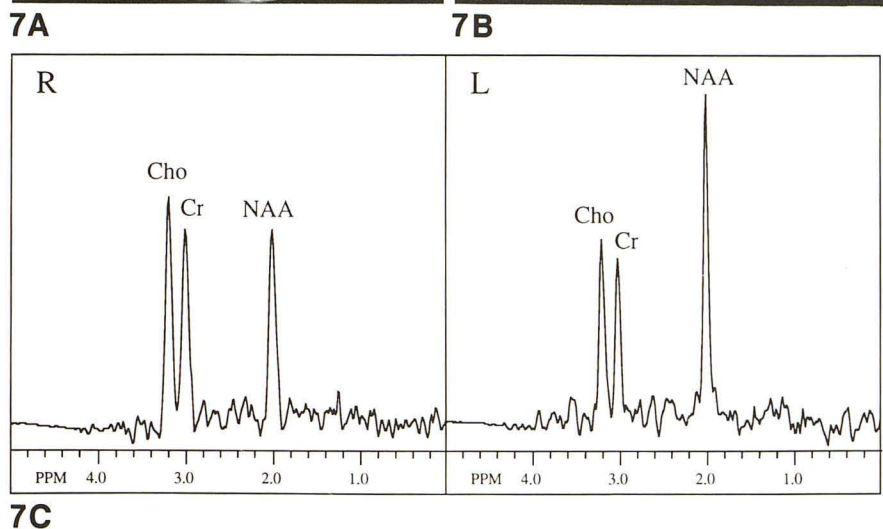


Fig. 8. N-acetyl-L-aspartate concentration from seizure and control foci in each patient.

Fig. 9. N-acetyl-L-aspartate-to-creatine ratios from seizure and control foci in each patient. (Note: creatine and choline signals could not be resolved in patient 1, so no N-acetyl-L-aspartate:creatine ratio was measured. EEG indicates electroencephalogram.)

obtained using normal biochemical techniques (33). This may indicate that other compounds, some of which may not be neuronally specific, contribute significant signal intensity to the peak

generally assigned to N-acetyl-L-aspartate. Possible contributions from glutamate/glutamine, N-acetyl-aspartyl-glutamate (34), and N-acetyl groups in membrane-associated sialic acid (N-

TABLE 2: Seizure patients

Patient	Sex	Age at Study (years)	Age at Seizure Onset (years)	Diagnosis	Seizure Location	MR Findings	Condition
1	F	28	13	Complex Partial Seizures secondary to anoxic injury	Right temporal lobe	Normal	
2	M	35	2	Idiopathic CPS	Left temporal lobe	Normal	
3	F	46	19	Idiopathic CPS	Right temporal lobe	Right hippocampal atrophy	
4	M	6	3.5	Rasmussen encephalitis	Left temporal lobe	Left temporal lobe T1 and T2 prolongation	Inflammatory changes of Rasmussen encephalitis
5	M	51	2	Idiopathic CPS	Left temporal lobe	Normal	No abnormality demonstrated
6	M	51	Late teens	Idiopathic CPS	Left temporal lobe	No significant abnormality	
7	F	22	19	Idiopathic CPS	Left amygdala	Normal	Microdysgenesis of neocortex
8	F	5	10 weeks	CPS secondary to meningitis	Left temporo-parietal	Normal	
9	M	5.5	5	Epilepsia partialis continua (Rasmussen encephalitis)	Left central frontal	Normal	
10	F	22 months	9 months	Surge-Weber-Dimitri syndrome	Right hemispheric	Right hemiatrophy, Jeptome nigeal enhancement, cortical calcification	
11	M	5	3	Neuronal migration abnormality	Left parieto-occipital	Left occipital neuronal migration abnormality	
12	F	4.5	3.5	Epilepsia partialis continua (Rasmussen encephalitis)	Left hemispheric	Right parietal T2 hyperintensity	
13	F	4.5	4.5	Herpes encephalitis	Left parietal lobe-post-central gyrus region	Left parietal cortical subtle T2 hyperintensity	

TABLE 3A: Metabolite concentration in patients with temporal lobe epilepsy

Patient	Seizure Focus					Control Focus					MR
	Cho	Cr	NAA ^a	Lac	NAA/Cr	Cho	Cr	NAA ^a	Lac	NAA/Cr	
1	^b	^b	7.6	0.0	^b	^b	^b	12.5	0.0	^b	—
2	2.4	10.8	8.4	0.0	0.8	3.7	9.7	12.1	0.0	1.3	—
3	1.6	5.2	7.0	0.0	1.4	2.2	9.1	9.6	0.0	1.1	+
4	1.5	5.5	3.0	11.2	0.6	2.0	12.0	11.5	1.3	1.0	+
5	3.1	10.6	7.4	0.0	0.7	2.9	12.5	10.3	0.0	0.8	—
6	1.9	6.3	6.8	0.0	1.1	1.5	11.7	7.8	0.0	0.7	—
7	1.7	8.8	7.9	0.0	0.9	1.7	8.8	8.6	0.0	1.0	—
Mean	2.0	7.9	6.9	1.6	.92	2.3	10.6	10.3	.2	.98	
SD	0.6	2.5	1.8	4.2	.29	0.8	1.6	1.8	0.5	.21	

Cho indicates choline; Cr, creatine; NAA, N-acetyl-L-aspartate; and Lac, lactate. Concentrations are in micromoles per g wet weight. MR findings: + indicates abnormal; and —, normal.

^a NAA seizure focus compared to control focus: $P = .0135$. No other comparison statistically significant.

^b Creatine and choline signals too poorly resolved to quantitate.

TABLE 3B: Metabolite concentration in nontemporal lobe epilepsy patients

Patient	Seizure Focus					Control Focus					MR
	Cho	Cr	NAA ^a	Lac	NAA/Cr	Cho	Cr	NAA ^a	Lac	NAA/Cr	
8	2.3	8.4	10.4	0.0	1.2	2.5	11.5	13.0	0.0	1.1	—
9	2.2	11.1	11.1	2.1	1.0	1.9	8.1	14.1	0.0	1.7	—
10	2.7	13.5	6.9	0.0	0.5	2.1	11.4	10.6	0.0	0.9	+
11	1.9	9.5	10.3	0.0	1.1	1.6	12.1	14.0	0.0	1.2	+
12	1.3	8.7	8.9	0.0	1.0	1.6	7.7	11.1	0.0	1.4	+
13	1.6	8.4	9.2	1.1	1.1	2.6	9.1	9.9	0.0	1.1	+
Mean	2.0	9.9	9.5	0.5	0.98	2.1	10.0	12.2	0.0	1.23	
SD	0.5	2.0	1.5	0.9	0.25	0.4	1.9	1.8	0	.28	

See Table 3A for abbreviations. Concentrations are in micromoles per g wet weight. MR findings: + indicates abnormal; and —, normal.

^a NAA seizure focus compared with control focus: $P = .0022$. No other comparison statistically significant.

TABLE 4: Metabolite concentrations in all 13 epilepsy patients

	Seizure Focus					Control Focus				
	Cho	Cr	NAA	Lac	NAA/Cr	Cho	Cr	NAA	Lac	NAA/Cr
Mean	2.0	8.9	8.1	1.1	0.95	2.2	10.3	11.2	.10	1.23
SD	.5	2.4	2.1	3.1	0.26	.6	1.7	2.0	.4	.27

See Table 3 for abbreviations.

TABLE 5: Table of P values

Comparison		P
NAA	Seizure control	.0002 ^a
Creatine	Seizure control	.132 ^b
Choline	Seizure control	.325 ^b
Lactate	Seizure control	.210 ^b
NAA/Cr	Seizure control	.126 ^b

^a Statistically significant difference.

^b Not statistically significant.

acetyl neuraminic acid) have been suggested (35). Also, although gray matter has a higher neuronal density than white matter, most proton spectra exhibit similar N-acetyl-L-aspartate levels in both tissue types (29) or slightly higher concentrations in white matter (13). It also has been observed that the N-acetyl-L-aspartate signal can be reduced or completely absent in other conditions known to involve neuronal loss, such as chronic infarcts or brain tumors (36, 37). Therefore, the question of the neuronal specificity of the N-acetyl-L-aspartate signal remains open.

Shrinkage or atrophy of certain brain structures (eg, the hippocampus), and an associated increase in the proportion of CSF within the localized volume, might also be expected to cause a reduction of N-acetyl-L-aspartate concentrations, as well as other metabolites (eg, creatine and choline). A general loss of cellularity (including neurons) also would be expected to be accompanied by a reduction of all metabolite concentrations (ie, N-acetyl-L-aspartate, creatine, and

choline). Global reductions in metabolite concentrations were observed in two patients with encephalomalacia (Barker PB, Breiter SN, unpublished data).

Regardless of the origin of the N-acetyl-L-aspartate signal reduction, it appears to be a good indicator of the location of the epileptogenic focus and could therefore be useful as an empirical diagnostic marker. The reductions in N-acetyl-L-aspartate were often quite small, especially in the patients with idiopathic temporal lobe epilepsy; however, the voxel sizes used in this study were relatively large, so that the spectra may contain appreciable contributions from normal brain. This contention is supported by a study of human cerebrum resected for seizure control that revealed normal temporal lobe tissue adjacent to mesial structures, which were presumed to have been the seizure focus (38). Spatial misregistration of the spectroscopy voxel and scalp electroencephalographic focus, that is, placing the spectroscopy voxel on the border of an epileptogenic zone rather than centered on it, is also a possible cause of the small differences in N-acetyl-L-aspartate. Higher resolution studies in conjunction with chemical shift imaging (13) promise to show larger metabolic differences between seizure foci and normal brain, because the voxel locations in chemical shift images can be moved to any desired location during postprocessing (39), and the smaller voxels obtainable with chemical shift

TABLE 6: Temporal lobe and hippocampal volume measurements in patients with temporal lobe epilepsy

Patient	Temporal Lobe Volume (cm ³)			Hippocampal Volume (cm ³)			Electroencephalographic Seizure Focus
	Right	Left	Difference ^a	Right	Left	Difference ^b	
1	39.54	40.47	-0.93	1.58	1.51	0.07	Right temporal
2	66.01	48.72	17.29	2.66	2.49	0.17	Left temporal
3	51.66	37.91	13.75	1.42	1.73	-0.31	Right temporal
6	62.95	71.70	-8.75	2.20	2.25	-0.05	Left temporal
7	47.09	44.08	3.01	^c	^c	^c	Left amygdala

^a Volume (right anterior temporal lobe minus left anterior temporal lobe).

^b Volume (right hippocampus minus left hippocampus).

^c Images not adequate for hippocampal volume measurement.

imaging will contain less contamination from normal brain tissue.

Although we suspect that absolute N-acetyl-L-aspartate concentrations are an important indicator of brain abnormality, the relatively small study group, along with the fact that single-proton spectrum voxels were used on each side, makes it impossible to define a definitive threshold concentration of N-acetyl-L-aspartate, between normal and abnormal brain. Most previous *in vivo* spectroscopy studies report ratios of metabolite intensities, often using the creatine signal as an internal reference. In our data, however, the difference among the ratio of N-acetyl-L-aspartate to creatine, between the seizure focus and the contralateral control volume, was not statistically significant (Table 5 and Fig 9). Comparison of anatomic mirror-image area signal intensities for N-acetyl-L-aspartate, as opposed to N-acetyl-L-aspartate/creatine ratios, improves the accuracy in identifying epileptogenic areas. However, normalization of measurements with regard to cerebral water signal is important because signal intensities can be perturbed by instrumental imperfections such as inhomogeneities in the B₀ and B₁ field strengths (40). Solving the uncertainties regarding the composition on the proton spectrum N-acetyl-L-aspartate peak, and collection of enough data to accurately delineate a threshold for N-acetyl-L-aspartate, is necessary to evaluate the patient with bilateral brain parenchymal abnormalities. This is particularly pressing in the patient with complex partial temporal lobe seizures and ambiguous electroencephalographic and imaging data. Without quantitation, therefore, the diagnostic specificity of proton spectroscopy is significantly reduced.

It has been documented that neuronal loss may increase with increased seizure onset (17, 18, 41); there also may be a relationship between N-acetyl-L-aspartate levels and the duration and

frequency of seizures. Although the sample size in this study did not permit a detailed analysis of this hypothesis, the patient with acute encephalitis had one of the smallest differences (reduction) in N-acetyl-L-aspartate levels between the seizure foci and the contralateral volume. However, several patients with chronic seizure disorders also had fairly small N-acetyl-L-aspartate differences, so there is clearly not a simple relationship between these two quantities.

In accordance with FDG positron emission tomography studies, which show reduced glucose uptake interictally in epileptogenic foci (42, 43) with elevated uptake only during seizures (44), lactate was detected only in two patients who were either status epilepticus at the time of examination (two patients with Rasmussen syndrome) or whose seizures had stopped immediately before the examination (the patient with encephalitis). It would therefore seem that the increased glucose uptake observed with positron emission tomography is predominantly metabolized anaerobically through pyruvate to lactate. It is not likely that the lactate observed with MR is caused by necrosis because no abnormal signal was seen on any of the long-repetition-time images, nor were any necrotic changes found on pathologic examination of tissue where available. Only one patient (with Rasmussen syndrome) had detectable lactate on the side contralateral to the epileptogenic foci. Interestingly, at the time of the examination the seizures were located with electroencephalogram in the left temporal lobe. After a left anterior temporal lobectomy and subsequent hemispherectomy, the patient continued to have seizures, but the electroencephalographic focus was now in the right temporal lobe. The small amount of lactate detected in the right temporal lobe (~1 μM/g wet weight) before hemispherectomy probably indicated a cerebral met-

abolic abnormality preceding any detectable clinical, electrical, or MR changes on this side.

The evaluation of the patient with intractable seizure disorder is multifaceted, especially when surgical resection of the epileptogenic focus of the brain is contemplated. Frequently, there is equivocal or discordant information regarding the location of this focus. MR is increasingly used for the evaluation of seizure disorders, not only for detection of signal abnormality but also volumetry. For instance, coronal high resolution 3-D spoiled gradient-echo imaging has been demonstrated to show hippocampal atrophy in patients with mesial temporal sclerosis (45). Also, small changes in water T2 relaxation times can be detected if careful, multiple-echo measurements are made (46–50). Although logistical limitations did not allow coronal 3-D studies to be performed in all patients, of the seven patients with temporal lobe epilepsy, five had normal MR examinations. One patient had hippocampal atrophy, and the other had Rasmussen syndrome. All 13 patients, including those with temporal lobe seizures, had lower N-acetyl-L-aspartate levels in the seizure focus than the contralateral control voxel. These data are therefore promising in that they indicate that metabolic changes may be detectable before changes in brain structure volumes or water relaxation time changes. This information may be used to identify or confirm the location of epileptogenesis in patients being evaluated for surgery. A study of a larger cohort of patients, which is being undertaken, with more detailed MR protocols, surgical confirmation of tissue pathology, and clinical follow-up is expected to increase the power of these observations.

Acknowledgments

We thank Dr Chrit Moonen (NIH In Vivo NMR Center, Bethesda, Md), Dr Peter van Zijl (Johns Hopkins University), and Dr Joe Gillen (Pittsburgh NMR Center, Pittsburgh, Pa) for the STEAM pulse sequence that was used to record some of the spectra in this study.

References

- Hauser W, Hesdorffer D. *Epilepsy: frequency, causes and consequences*. New York: Demos, 1990:1–51
- Petroff O, Prichard J, Behar K, Alger J, Shulman R. In vivo phosphorus nuclear magnetic resonance spectroscopy in status epilepticus. *Ann Neurol* 1984;16:169–177
- Petroff O, Prichard J, Ogino T, Avison M, Alger J, Shulman R. Combined ^1H and ^{31}P nuclear magnetic resonance spectroscopic studies of bicuculline-induced seizures in vivo. *Ann Neurol* 1986;20:185–193
- Young RS, Petroff OA, Novotny EJ, Wong M. Neonatal excitotoxic brain injury. Physiologic, metabolic, and pathologic findings. *Dev Neurosci* 1990;12:210–220
- Young R, Petroff O. Neonatal seizure: magnetic resonance spectroscopic findings. *Semin Perinatol* 1990;14:238–247
- Young RS, Chen B, Petroff OA, et al. The effect of diazepam on neonatal seizure: in vivo ^{31}P and ^1H NMR study. *Pediatr Res* 1989;25:27–31
- Young R, Cowan B, Petroff O, Novotny E, Dunham S, Briggs R. In vivo ^{31}P and ^1H nuclear magnetic resonance study of hypoglycemia during neonatal seizure. *Ann Neurol* 1987;22:622–628
- Matthews PM, Andermann F, Arnold DL. A proton magnetic resonance spectroscopy study of focal epilepsy in humans. *Neurology* 1990;40:985–989
- Hugg JW, Matson GB, Twieg DB, Maudsley AA, Sappey MD, Weiner MW. Phosphorus-31 MR spectroscopic imaging (MRSI) of normal and pathological human brains. *Magn Reson Imaging* 1992;10:227–243
- Younkin D, Dellivoria-Papadopoulos M, Maris J, Donlon E, Clancy R, Chance B. Cerebral metabolic effects of neonatal seizures measured with in vivo ^{31}P -NMR spectroscopy. *Ann Neurol* 1986;20:513–519
- Hugg JW, Laxer KD, Matson GB, Maudsley AA, Hustead CA, Weiner MW. Lateralization of human focal epilepsy by ^{31}P magnetic resonance spectroscopic imaging. *Neurology* 1992;42:2011–2018
- Laxer KD, Hubesch B, Sappey-Marini D, Weiner MW. Increased pH and inorganic phosphate in temporal seizure foci demonstrated by ^{31}P MRS. *Epilepsia* 1992;33:618–623
- Moonen C, Sobering G, van Zijl P, Gillen J, von Kienlin M, Bizzi A. Proton spectroscopic imaging of human brain. *J Magn Reson* 1992;98:556–575
- Birken DL, Oldendorf WH. N-acetyl-L-aspartic acid: a literature review of a compound prominent in ^1H -NMR spectroscopic studies of brain. *Neurosci Biobehav Rev* 1989;13:23–31
- Dam W. The density of neurons in the human hippocampus. *Neuro-pathol Appl Neurobiol* 1979;5:249–264
- Dam W. Epilepsy and neuron loss in the hippocampus. *Epilepsia* 1980;21:617–629
- Dam W. Hippocampal neuron loss in epilepsy and after experimental seizures. *Acta Neurol Scand* 1982;66:601–642
- Sagar H, Oxbury J. Hippocampal neuron loss in temporal lobe epilepsy: correlation with early childhood convulsions. *Ann Neurol* 1987;22:334–340
- Jack CR Jr, Gehring DG, Sharbrough FW, et al. Temporal lobe volume measurement from MR images: accuracy and left-right asymmetry in normal persons. *J Comput Assist Tomogr* 1988;12:21–29
- Jack CR Jr, Twomey C, Zinsmeister A, Sharbrough F, Petersen R, Cascino G. Anterior temporal lobes and hippocampal formations: normative volumetric measurements from MR images in young adults. *Radiology* 1989;172:549–554
- Jack C, Sharbrough F, Twomey C, et al. Temporal lobe seizures: lateralization with MR volume measurements of the hippocampal formation. *Radiology* 1990;175:423–429
- Naidich TP, Daniels DL, Houghton VM, Williams A, Pojunas K, Palacios E. Hippocampal formation and related structures of the limbic lobe: part I. *Radiology* 1987;162:747–754
- Bronen RA, Cheung G. MRI of the normal hippocampus. *Magn Reson Imaging* 1991;9:497–500
- Frahm J, Bruhn H, Gyngell ML, Merboldt KD, Hanicke W, Sauter R. Localized high-resolution proton NMR spectroscopy using stimulated echoes: initial applications to human brain in vivo. *Magn Reson Med* 1989;9:47–63
- Bottomley P. Selective volume method for performing localized NMR spectroscopy. *US Patent* 1984;4480228
- Moonen CT, van Zijl PCM, Gillen J, et al. Comparison of single-shot localization methods (STEAM and PRESS) for in vivo proton NMR spectroscopy. *NMR Biomed* 1989;2:201–208

27. Haase A, Frahm J, Hanicke W, Matthaei D. ^1H NMR chemical shift selective imaging. *Phys Med Biol* 1985;30:341-344
28. Moonen CTW, van Zijl PCM. Highly effective water suppression for in vivo proton NMR spectroscopy (DRYSTEAM). *J Magn Reson* 1990;88:28-41
29. Barker PB, Soher BJ, Blackband SJ, Chatham JC, Mathews VP, Bryan RN. Quantitation of proton NMR spectra of the human brain using tissue water as an internal concentration reference. *NMR Biomed* 1993;6:89-94
30. Barker PB, Sibisi S. Non-linear least squares analysis of in vivo ^{31}P NMR data (abstr). In: Book of Abstracts: Society of Magnetic Resonance in Medicine 1990. Berkeley, CA: Society of Magnetic Resonance in Medicine, 1990;1089
31. Marion D, Ikura M, Bax A. Improved solvent suppression in one- and two-dimensional NMR spectra by convolution of time-domain data. *J Magn Reson* 1989;84:425-430
32. Diem K, Lentner C. *Documenta Geigy: scientific tables*. 7th ed. Basel: Ciba-Geigy, 1970:519
33. Siegel G, Agranoff B, Albers PW, Molinoff P. *Basic neurochemistry*. 4th ed. New York: Raven, 1989:558
34. Frahm J, Michaelis T, Merboldt K-D, Hanicke W, Gyngell ML, Bruhn H. On the N-acetyl methyl resonance in localized ^1H NMR spectra of the human brain in vivo. *NMR Biomed* 1991;4:201-204
35. Hanstock CC, Rothman DL, Prichard JW, Jue T, Shulman RG. Spatially localized ^1H NMR spectra of metabolites in the human brain. *Proc Natl Acad Sci USA* 1988;85:1821-1825
36. Alger JR, Frank JA, Bizzi A, et al. Metabolism of human gliomas: assessment with H-1 MR spectroscopy and F-18 fluorodeoxyglucose PET. *Radiology* 1990;177:633-641
37. Bruhn H, Frahm J, Gyngell ML, Merboldt KD, Hanicke W, Sauter R. Cerebral metabolism in man after acute stroke: new observations using localized proton NMR spectroscopy. *J Magn Reson* 1989;9:126-131
38. Petroff OA, Spencer DD, Alger JR, Prichard JW. High-field proton magnetic resonance spectroscopy of human cerebrum obtained during surgery for epilepsy. *Neurology* 1989;39:1197-1202
39. Mareci T, Brooker H. High-resolution magnetic resonance spectra from a sensitive region defined with pulsed field gradients. *J Magn Reson* 1984;57:157-163
40. Freeman R. *A handbook of nuclear magnetic resonance*. New York: Wiley, 1988:101-224
41. Cavanagh J, Meyer A. Aetiological aspects of Ammon's horn sclerosis associated with temporal lobe epilepsy. *Br Med J* 1956;2:1403-1407
42. Engel J, Kuhl D, Phelps M, Crandall P. Comparative localization of epileptic foci in partial epilepsy by PCT and EEG. *Ann Neurol* 1982;12:529-537
43. Theodore W, Fishbein D, Dubinsky R. Patterns of cerebral glucose metabolism in patients with partial seizures. *Neurology* 1988;38:1201-1206
44. Engel J, Kuhl D, Phelps M, Rausch R, Nuwer M. Local cerebral metabolism during partial seizures. *Neurology* 1983;33:400-413
45. Free S, Cook M, Fish D, Shorvon S, Straughan K, Stevens J. Volumetric imaging in temporal and extratemporal epilepsies (abstr). In: Book of Abstracts: Society of Magnetic Resonance in Medicine 1992. Berkeley, CA: Society of Magnetic Resonance in Medicine, 1992;504
46. Jackson G, Connelly A, Gadian D, Duncan J. Detection of hippocampal pathology in temporal lobe epilepsy: increased sensitivity with T2 mapping (abstr). In: Book of Abstracts: Society of Magnetic Resonance in Medicine 1992. Berkeley, CA: Society of Magnetic Resonance in Medicine 1992;502
47. Brooks B, King D, Gammal T, et al. MR Imaging in patients with intractable complex partial epileptic seizures. *AJNR Am J Neuroradiol* 1990;11:93-99
48. Kuzniecky R, de la Sayette V, Ethier R, et al. Magnetic resonance imaging in temporal lobe epilepsy: pathological correlations. *Ann Neurol* 1987;22:341-347
49. Bronen R, Cheung G, Charles J, et al. Imaging findings in hippocampal sclerosis: correlation with pathology. *AJNR Am J Neuroradiol* 1991;12:933-940
50. Jackson G, Berkovic S, Tress B, Kalnins R, Fabinyi G, Bladin P. Hippocampal sclerosis can be reliably detected by magnetic resonance imaging. *Neurology* 1990;40:1869-1875