



## Get Clarity On Generics

Cost-Effective CT & MRI Contrast Agents

**FRESENIUS  
KABI**

[WATCH VIDEO](#)

# AJNR

### **Total intravenous anesthesia with propofol in pediatric patients for MR examination.**

N Colombo, E M Arosio, A Levati, G Savoia, M Gramegna, M Borroni, E Ego, G Scialfa and L Boselli

*AJNR Am J Neuroradiol* 1994, 15 (10) 1967-1968

<http://www.ajnr.org/content/15/10/1967.citation>

This information is current as  
of August 8, 2025.

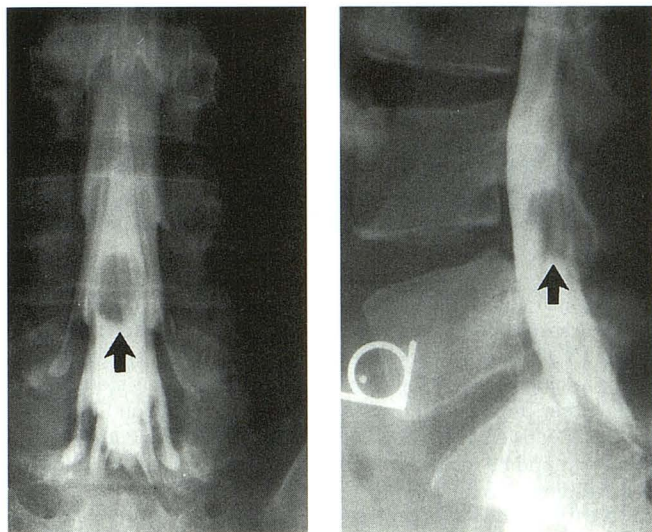


Fig 3. Anteroposterior and lateral radiographs from the myelogram demonstrating an intradural lesion at the L-4/L-5 level (black arrows).

The failure of MR to clearly detect the second lesion was significant for two reasons. Had this drop metastasis not been discovered, adjuvant radiation therapy may not have been given; and because the lesion was not seen on MR, it is unclear what imaging strategy should be used to follow the patient.

We agree with Epstein et al (1) that in a patient with a neurologic deficit and a negative or equivocal MR, a myelogram may be of value. Further, this case demonstrates that the drop metastases of myxopapillary ependymoma can have an MR appearance similar to cerebrospinal fluid, making them difficult to resolve.

Patrick J. Oliverio  
Lee H. Monsein

*Department of Radiological Science and Radiology*

Walter Royal III  
*Department of Neurology*

Alessandro Olivi  
*Department of Neurosurgery*

Manuel F. Utset  
*Neuropathology Laboratory, Department of Pathology*

Henry Brem  
*Department of Neurosurgery*

*Johns Hopkins Hospital  
Baltimore, Md*

## References

1. Epstein NE, Bhuchar S, Gavin R, Hyman R, Zito J. Failure to diagnose conus ependymomas by magnetic resonance imaging. *Spine* 1989;14:134-137.

## Total Intravenous Anesthesia with Propofol in Pediatric Patients for MR Examination

There is still no agreement among people dealing with sedation of pediatric patients undergoing a magnetic resonance (MR) examination, and the "ideal" drug that is safe, fast in onset, has a short recovery time, and has no collateral effects, is still not on the market. We have given propofol (Diprivan) intravenously to induce general anesthesia with spontaneous ventilation in 118 pediatric patients 14 days to 11 years of age who are either inpatients or outpatient undergoing MR study of the central nervous system.

Previous reports have described the use of intravenous propofol for anesthesia in minor surgical procedures (1, 2), for pediatric sedation during radiologic imaging studies (3), and for neurosurgical procedures. This drug is capable of reducing the cerebral metabolic rate of carbon dioxide and reducing intracranial pressure (4). Reported properties of propofol such as rapidity of action and speed of emergence from anesthesia justify the use of this drug for anesthesia in neuropsychiatric patients undergoing MR. Because in Italy the use of propofol is "inadvisable in children under 3 years of age" and it is "not licensed" in intensive care sedation of children, we prospectively recruited a group of 118 patients for our study after obtaining parental consent and approval of the hospital ethics committee. Anesthesia was induced by intravenous bolus or, more frequently, by fast drip of propofol in 68 patients, by propofol associated with neuroleptanalgesic intravenous drugs in 16 patients, by propofol and halothane in 14 patients, and by halothane with supplemental oxygen in 20 patients. Halothane alone was used for induction in younger children or when an intravenous access, necessary to inject propofol, was difficult to establish. Anesthesia was maintained by intravenous continuous infusion of propofol controlled through the use of an infusion pump in all patients who continued with spontaneous ventilation receiving supplemental oxygen (4 L/h) through a small tube. Variable individual mean doses of the drug were identified adapting the dosage from data reported in the literature. The sedation regimen we developed allowed anesthesia of adequate depth with spontaneous ventilation and complete immobility of all children during MR, so that all MR examinations were successfully completed.

No side effects occurred. However, we would like to stress that propofol is an "intravenous anesthetic," and its infusion requires the constant supervision of an anesthesiologist or a trained person and monitoring the patient's vital signs, including electrocardiogram, end-tidal CO<sub>2</sub>, pulse oximetry, respiratory frequency, pulse rate, and blood pressure, recorded from induction to complete recovery according to recommendations of the American Society of Anesthesiologists (ASA) and the Section of Anesthesiology of the American Academy of Pediatrics (AAP). As opposed to the Bloomfield study (3), in which 10% of the patients receiving propofol had sufficient disruption of ventilation to develop a pulse oximetry under 90%, in our experience the depressant effect on ventilation



of propofol was very low (1.9%). According to data previously reported in the literature (5, 6) in which propofol is reported to decrease arterial blood pressure markedly, our data revealed a tendency to cardiovascular instability in most patients mainly at the time of induction. However, drops of systolic arterial pressure were all transient, responded to temporary cessation of drug infusion, and did not cause any clinical sequela.

In conclusion, we believe that intravenous propofol is a good drug for anesthesia in pediatric patients undergoing MR. However, because of potential adverse side effects, we recommend careful selection of patients, continuous monitoring of vital signs, and constant supervision by an anesthesiologist or other trained person.

N. Colombo  
*Neuroradiology Department*

E. M. Arosio  
A. Levati  
G. Savoia  
M. Gramegna  
M. Borroni  
*Anesthesiology Department*

E. Ego  
G. Scialfa  
*Neuroradiology Department*

L. Boselli  
*Anesthesiology Department*  
*Ospedale Cà Granda-Niguarda*  
*Milano, Italy*

## References

1. Cockshott ID. Propofol (Diprivan) pharmacokinetics and metabolism: an overview. *Postgrad Med J* 1985;61(suppl):45
2. Puttick N, Rosen M. Propofol induction and maintenance in paediatric outpatients anaesthesia. *Anaesthesia* 1988;43:646-649
3. Bloomfield EL, Masaryk TJ, Caplin A, et al. Intravenous sedation for MR imaging of the brain and spine in children: pentobarbital versus propofol. *Radiology* 1993;186:93-98
4. Stephan H, Sunntag H, Schenk HD, Kohlhausen S. Effect of propofol on cerebral metabolism and on the response of the cerebral circulation. *Anaesthetist* 1987;36:60-65
5. Claeys MR, Gepts E, Camu F. Haemodynamic changes during anaesthesia induced and maintained with propofol. *Br J Anaesth* 1988;60:3-9
6. Short SM, Aun CST. Haemodynamics effects of propofol in children. *Anaesthesia* 1991;46:783-785

## Application of Stereoscopic Viewing to Maximum Intensity Projection Images Obtained in MR Angiography

The application of an old radiographic technique, stereoscopic viewing (1, 2), to either spiral computed tomographic angiography or magnetic resonance angiography

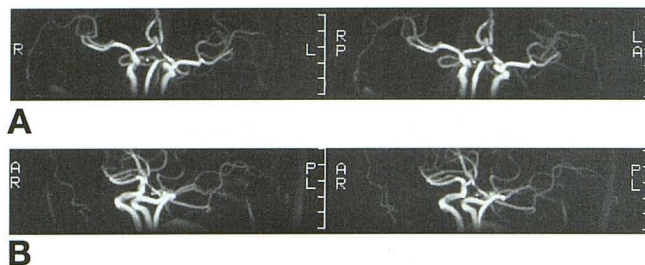


Fig 4. A and B, Maximum intensity projection image pairs of a three-dimensional phase-contrast (36/8 [repetition time/echo time], 15° flip angle, velocity encoding 40 cm/s) magnetic resonance angiogram are easily seen in three dimensions stereoscopically either by crossing ones eyes or by using a hand-held stereoscopic viewer. Note how well anterior communicating artery aneurysm and its relationship to surrounding vessels is evaluated in three-dimensional viewing.

maximum intensity projection algorithm images is easily accomplished and can significantly enhance both diagnostic detection and evaluation of lesions.

Stereoscopic viewing permits the judging of relative distances between structures and parts of the same structure and thus helps not only in locating a lesion but also in perceiving its shape, structure, and spatial relationships (3).

We have noted that our magnetic resonance scanner (GE 1.5 T) displays magnetic resonance angiography maximum intensity projection images in such a way, 20 images rotated 18° around a 360° axis, that every image pair is easily visualized stereoscopically. The additional information obtained may obviate the need to perform standard invasive angiography in some patients and add to the information obtained in these studies. Overlapping vessels can be clearly separated.

In the case shown—an incidental clinically silent anterior communicating artery aneurysm—stereoscopic viewing of multiple images as well as evaluation of magnetic resonance angiography source images and standard spin-echo coronal, axial, and sagittal images make standard invasive angiography unnecessary (Fig 4).

Stereoscopic viewing of chest radiographs, facial x-rays, arch arteriograms, and other radiographic studies has fallen into disuse in recent decades. However, with practice, these skills can be learned and should be applied to the optimal evaluation of maximum intensity projection magnetic resonance angiography and computed tomographic angiography images.

John F. Healy  
*Clinical Professor of Neuroradiology*

Wade H. M. Wong  
*Assistant Professor of Radiology*  
*University of California San Diego*