



Providing Choice & Value

Generic CT and MRI Contrast Agents



FRESENIUS
KABI

CONTACT REP

AJNR

**Effect of dose and field strength on enhancement
with paramagnetic contrast media.**

R O Lindsey, F Z Yetkin, R Prost and V M Haughton

AJNR Am J Neuroradiol 1994, 15 (10) 1849-1852

<http://www.ajnr.org/content/15/10/1849>

This information is current as
of July 30, 2025.

Effect of Dose and Field Strength on Enhancement with Paramagnetic Contrast Media

Robert O. Lindsey, F. Zerrin Yetkin, Robert Prost, and Victor M. Haughton

PURPOSE: To compare contrast enhancement per unit of dose of contrast medium in MR imaging at 0.5 and 1.5 T. **METHODS:** Contrast enhancement in images made at 0.5 and 1.5 T after 0.1 mmol/kg of gadopentetate dimeglumine and 0.3 mmol/kg of gadodiamide was measured and the degree of contrast enhancement in the cavernous sinus and pituitary gland compared. **RESULTS:** At both field strengths and both contrast medium doses, contrast enhancement was noted in the cavernous sinus, pituitary gland, infundibulum, maxillary sinus mucosa, falx cerebri, and choroid plexus on inspection of images. Enhancement was significantly and conspicuously less in the cavernous sinus and pituitary gland at 0.5 T (96% and 33%, respectively) than at 1.5 T (160% and 102%, respectively). No tissues were identified that enhanced only with the larger dose or higher field strength. **CONCLUSION:** In tissues that normally enhance after intravenous administration of gadolinium chelates, enhancement is greater at 1.5 T than at 0.5 T.

Index terms: Magnetic resonance, contrast enhancement; Magnetic resonance, tissue characterization; Magnetic resonance, technique

AJNR Am J Neuroradiol 15:1849–1852, Nov 1994

The enhancement from a paramagnetic contrast agent depends on the intrinsic relaxation measured in the absence of the agent. In principle, there is less contrast enhancement at lower field strengths, because the relaxation time of tissue is shorter at lower fields. To our knowledge the effect of field strength on contrast enhancement has not been emphasized; quantitative studies of contrast enhancement of normal central nervous system tissues have focused primarily on 1.5-T imagers (1–3). We measured the effect of field strength on contrast enhancement of normal tissues in patients receiving paramagnetic contrast media.

Materials and Methods

Seventeen patients who were referred for magnetic resonance (MR) imaging and were enrolled in a phase III drug

investigation protocol were the subjects for this study. With a computer-generated randomization schedule, patients were assigned to receive gadopentetate dimeglumine (Magnevist, Berlex Laboratories, Wayne, NJ) at a dose of 0.1 mmol/kg or gadodiamide (Omniscan, Sterling Winthrop Pharmaceuticals, New York, NY) at a dose of 0.3 mmol/kg. The patients and investigators were blinded to the drug used. The patients had a variety of intracranial disease, including cerebral tumors, arteriovenous malformations, and metastases. Some patients had normal MR findings. A 1.5-T Signa and a 0.5-T Signa unit (General Electric Medical Systems, Milwaukee, Wis) were used for imaging. T1-weighted images were obtained before and 5 minutes after an infusion over 1 minute of either gadopentetate dimeglumine (0.1 mmol/kg) or gadodiamide (0.3 mmol/kg) administration into an antecubital vein. The MR parameters were 400–600/10–20/2 (repetition time/echo time/excitations). The same planes of section to transmit and receive attenuation settings were used in the preinjection and postinjection images. Five-millimeter section thicknesses at 6-mm intervals with 25-cm fields of view were used in most patients. Axial, sagittal, or coronal planes were chosen depending on suspected clinical disease.

Images were examined, and signal intensity was measured by one investigator without knowledge of the contrast agent used. Normal tissues that demonstrated enhancement at each field strength and dose were tabulated. Contrast enhancement was measured in the pituitary gland and cavernous sinus. Contrast enhancement was

Received April 20, 1993; accepted after revision April 14, 1994.

From the Department of Radiology, Medical College of Wisconsin, Milwaukee.

Address reprint requests to: Victor M. Haughton, MD, Department of Radiology, Medical College of Wisconsin, Froedtert Memorial Lutheran Hospital, Milwaukee, WI 53226.

AJNR 15:1849–1852, Nov 1994 0195-6108/94/1510-1849

© American Society of Neuroradiology

Fig 1. Coronal (A) and sagittal (B) images obtained at 0.5 T (*above*) and 1.5 T (*below*) in a woman with an inhomogeneously enhancing pituitary gland. The cavernous sinus, sinus mucosa, choroid plexus, and straight sinus appear to enhance to a greater degree at 1.5 T than at 0.5 T.

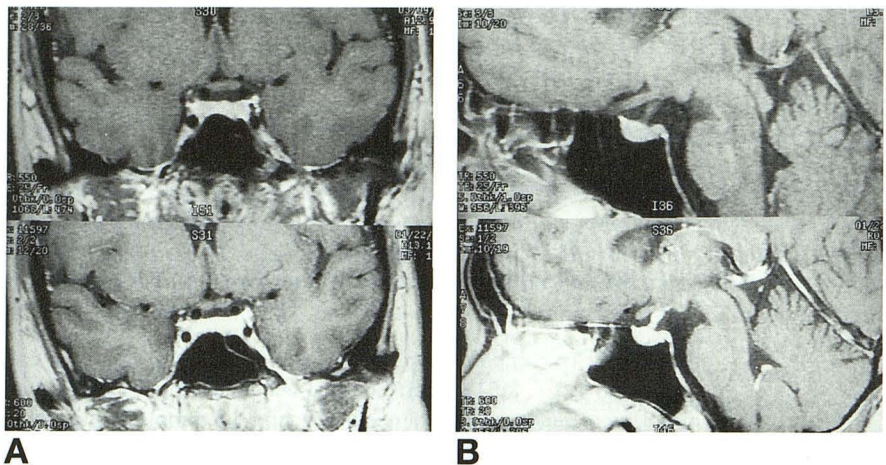
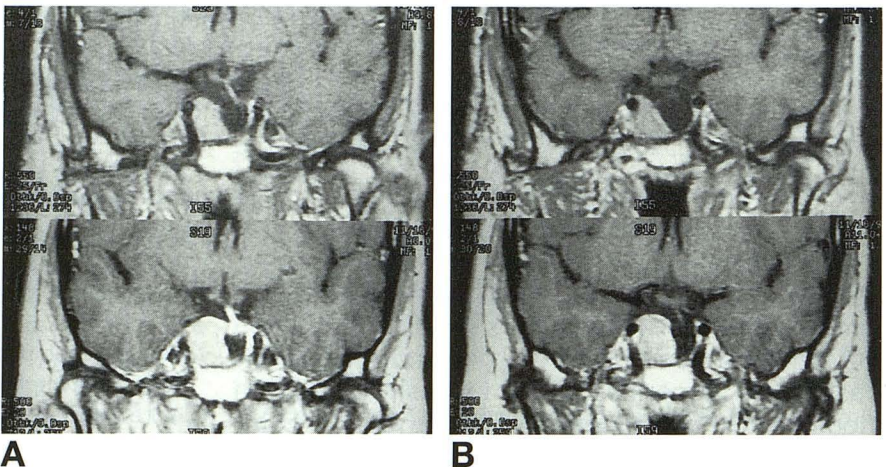


Fig 2. Contiguous contrast-enhanced coronal images in a patient with a partially resected pituitary adenoma. In the 0.5-T images (*above*) the pituitary gland and cavernous sinus seem to enhance less than at 1.5 T (*below*).



calculated from signal intensity measured with a region-of-interest cursor. The size and shape of the cursor were adjusted to maximize the sample to be measured while minimizing the partial volume error. The cursor dimension and location were the same in each preinjection and postinjection image. Enhancement was calculated as the difference between precontrast and postcontrast signal intensities divided by the precontrast intensity. The measurements were stratified by dose of contrast medium, tissue type, and field strength.

To illustrate this article, cases were selected at random from recently studied patients who had MR imaging of the sella at two field strengths: 0.5 and 1.5 T.

Results

Enhancement was noted in the normal cavernous sinus, infundibulum, pituitary gland, maxillary sinus mucosa, falx cerebri, and choroid plexus. Cerebrospinal fluid and cerebral gray and white matter had no enhancement vis-

ible with either gadopentetate dimeglumine or gadodiamide. Of the studies that included coronal sections through the cavernous sinus and pituitary gland suitable for measuring enhancement, four were at 1.5 T with 0.1 mmol/kg, five at 0.5 T with 0.1 mmol/kg, seven at 1.5 T with 0.3 mmol/kg, and one at 0.5 T with 0.3 mmol/kg. Contrast enhancement of the pituitary gland and infundibulum was conspicuously greater with the larger dose of contrast medium (Fig 1).

Six cases were identified from recent MR studies that had comparable images of the sella at both 1.5 and 0.5 T. The dose of contrast medium (0.1 mmol/kg) was the same in each study. The technical parameters and the planes of section were equivalent at the two field strengths. The images were filmed at identical windows. In each case, the enhancement of the pituitary gland and cavernous sinus appeared greater at 1.5 T than at 0.5 T (Figs 1 and 2).

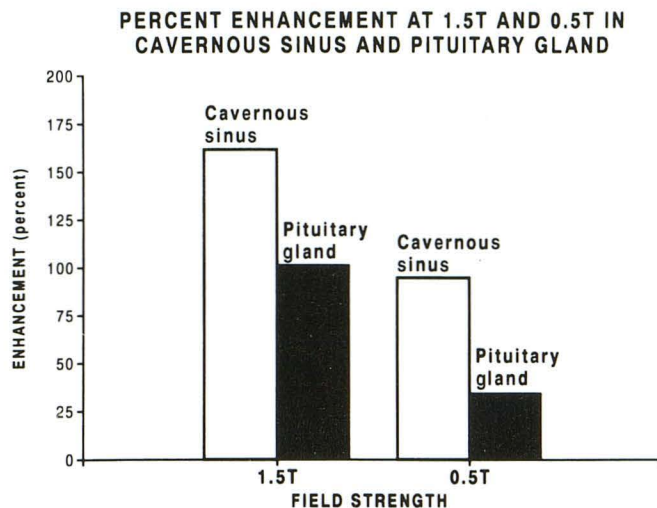


Fig 3. Enhancement (as a percent of baseline signal intensity) in the cavernous sinus and pituitary gland at 1.5 and 0.5 T after administration of 0.1 mmol/kg of gadopentetate dimeglumine.

Average contrast enhancement measurements for the 1.5- and 0.5-T imagers and the 0.1- and 0.3-mmol/kg doses are provided in Figure 3. In images made on the 1.5-T imager, the cavernous sinuses and pituitary glands enhanced, respectively, on average 162% and 102% (SD, 34% and 17%) with gadopentetate dimeglumine at 0.1 mmol/kg. In images made on the 0.5-T imager, these same structures enhanced 96% and 33%, respectively (SD, 42% and 19%) at the same dose. These structures enhanced 299% and 206%, respectively, with gadodiamide at 0.3 mmol/kg at 1.5 T. The differences in degree of enhancement at different doses and field strength were significant at the $P < .05$ level (Student's t test).

Discussion

Enhancement was noticeably and measurably greater for a given dose of contrast medium with the 1.5-T imager than with the 0.5-T imager. The relationship between field strength and contrast enhancement can be predicted from the relationship between T1 relaxation times and enhancement: $1/T1_{obs} = 1/T1_{tissue} + 1/T1_{contrast\ medium}$, where $T1_{obs}$ is the relaxation time of tissue to which contrast medium has been added; $T1_{tissue}$ is the relaxation time of the tissue without contrast medium; and $T1_{contrast\ medium}$ is the change in relaxation time caused by contrast medium. As the $T1_{tissue}$ in-

creases, the effect of contrast enhancement increases. Assuming the $T1_{contrast\ medium}$ is 500 milliseconds and the $T1_{tissue}$ is 500 milliseconds, adding contrast medium will reduce the $T1_{obs}$ by 50%. If the $T1_{tissue}$ is less, the effect of adding contrast medium will be less. For example, if the $T1_{tissue}$ is 100 milliseconds, the effect of adding a relaxing agent with a T1 of 1000 milliseconds will be to reduce the $T1_{obs}$ by 9%. Contrast enhancement has a greater effect when the intrinsic relaxation is slow.

The contrast enhancement measured with gadopentetate dimeglumine at 0.1 mmol/kg at 1.5 T in this study agrees with previously obtained results (1). Cerebrospinal fluid, gray matter, and white matter did not appreciably enhance quantitatively or qualitatively with gadopentetate dimeglumine in this study as in the previous study (1). Until two recently published reports on this subject (4, 5), few measurements of contrast enhancement at multiple field strengths have been published (6). Contrast enhancement as a function of time (7) and dose has been reported (8, 9).

Our measurements have some limitations, which do not invalidate the conclusions of the study. Precision in the measurements of contrast enhancement in this study was limited by partial volume averaging, by small variations in timing of the images with respect to injection, by individual variation, and by the small sample size. Studies can be designed in the future to achieve higher accuracy. A cross-over design, which would permit a more exact comparison of the gadodiamide and gadopentetate dimeglumine study, was not used, because the phase III trial was designed to obviate a second MR scan in each patient. The two contrast media used in the study differ little in relaxivity, plasma half-life, and renal excretion, but differ significantly in structure (ionic chelate versus nonionic chelate). Ion charge on the gadolinium chelate may be an important factor in the enhancement of cartilage (10) but probably not in other tissues.

References

1. Kilgore DP, Breger RK, Daniels DL, et al. Cranial tissues: normal MR appearance after intravenous injection of Gd-DTPA. *Radiology* 1986;160:757-761
2. Sze G, Brandt-Zawadzki M, Haughton VM, et al. Multicenter study of gadodiamide injection as a contrast agent in MR imaging of the brain and spine. *Radiology* 1991;181:693-699

3. Greco A, McNamara MT, Lantheiz P, Quay SC, Michelozzi G. Gadodiamide injection: non-ionic gadolinium chelate for MR imaging of brain and spine—phase II-III clinical trials. *Radiology* 1990;176:451–455
4. Elster AD. Field strength dependence of gadolinium enhancement: theory and implications. *AJNR Am J Neuroradiol* 1994;15:1420–1423
5. Chang KH, Ra DG, Han MH, Cha SH, Kim HD, Han MC. Contrast enhancement of brain tumors at different MR field strengths: comparison of 0.5 and 2.0 T. *AJNR Am J Neuroradiol* 1994;15:1413–1419
6. Haustein J, Laniado M, Niendorf HP, et al. Administration of gadopentetate dimeglumine in MR imaging of intracranial tumors: dosage and field strength. *AJNR Am J Neuroradiol* 1992;13:1199–1206
7. Ross JS, Balser S, Masaryk TJ, et al. Gd-DTPA enhancement of posterior epidural scar: an experimental model. *AJNR Am J Neuroradiol* 1989;10:1083–1088
8. Yuh WTC, Fisher DJ, Engelhen JD, et al. MR evaluation of CNS tumors: dose study with gadopentetate dimeglumine and gadoteridol. *Radiology* 1991;180:485–491
9. Giccometti AR, Luseph GL, Peterson JE, Davis PC. Comparison of full- and half-dose gadolinium-DTPA: MR imaging of the normal sella. *AJNR Am J Neuroradiol* 1993;14:123–127
10. Ibrahim MA, Haughton VM, Hyde JS. Enhancement of intervertebral disks with gadolinium complexes: comparison of an ionic and a nonionic medium in an animal model. *AJNR Am J Neuroradiol* 1994;15:1907–1910