



**Get Clarity On Generics**

Cost-Effective CT & MRI Contrast Agents



FRESENIUS  
KABI

WATCH VIDEO

**AJNR**

**Multiple sclerosis presenting as Parinaud syndrome.**

D J Quint, W T Cornblath and J D Trobe

*AJNR Am J Neuroradiol* 1993, 14 (5) 1200-1202

<http://www.ajnr.org/content/14/5/1200>

This information is current as  
of August 3, 2025.

# Multiple Sclerosis Presenting as Parinaud Syndrome

Douglas J. Quint,<sup>1,3</sup> Wayne T. Cornblath,<sup>2</sup> and Jonathon D. Trobe<sup>2</sup>

**Summary:** The authors report a patient presenting with a 1-week history of paresis of upward gaze as his initial manifestation of demyelinating disease. They stress that: 1) multiple sclerosis can *present* as Parinaud syndrome (paralysis of upward gaze); and 2) it is important to rule out a non-contour-deforming intraaxial midbrain lesion if a posterior third ventricle or pineal region mass is not identified on screening studies in these patients.

**Index terms:** Sclerosis, multiple; Demyelinating disease; Vision; Paralysis

Parinaud syndrome, also called the dorsal midbrain syndrome, sylvian aqueduct syndrome, and pretectal syndrome, includes multiple clinical signs, the most prominent of which is paralysis of upward gaze (1, 2). In mainstream imaging textbooks (3–7), this syndrome essentially is exclusively described in association with extraaxial pineal region masses. Other relatively common causes of this syndrome (hydrocephalus, intrinsic midbrain masses, and ischemic lesions) and rarer causes of this syndrome (metabolic, drug-induced, degenerative, infectious, and inflammatory) have been reported primarily in the neurology and ophthalmology literature (8).

## Case Report

A 49-year-old man presented with a 1-week history of headache, nausea, and vertical diplopia treated unsuccessfully with nonsteroidal antiinflammatory medication (piroxicam) for presumed myositis. Past medical history was unremarkable.

Neuroophthalmologic examination demonstrated 20/20 visual acuity with normal color vision. The pupils measured 7 mm on the right and 8 mm on the left. Visual fields and fundus examination were normal. Horizontal gaze was normal bilaterally. Downgaze and accommodation were normal. Upgaze was limited to 30% of normal with an associated convergence retraction nystagmus. Bilateral superior oblique pattern ocular muscle palsies were noted. Other

cranial nerves were normal. The remainder of the neurologic and physical examination was normal except for right leg hyperreflexia and a right extensor plantar reflex.

Lumbar puncture revealed an elevated cerebrospinal fluid protein of 63 mg/dL (normal <45 mg/dL) and a normal glucose of 65 mg/dL. Myelin basic proteins (2.2), immunoglobulin G (4.9), and the immunoglobulin G index (0.82) were within normal limits. Three oligoclonal bands were present in the cerebrospinal fluid with one in the serum consistent with an inflammatory central nervous system process.

Short repetition time (TR), short echo time (TE) T1-weighted magnetic resonance (MR) imaging (Fig. 1A) demonstrated no abnormality in the pineal region. However, on long TR, short TE (intermediate weighted) scanning (Fig. 1B) and long TR, long TE (T2-weighted) scanning, a 5-mm focus of abnormal signal without mass effect or contrast enhancement in the right periaqueductal region was identified. In addition, multiple ellipsoid supratentorial periventricular lesions characteristic of demyelinating disease were also seen (Fig. 1C).

A diagnosis of possible multiple sclerosis (MS) was made, and no specific treatment was instituted. Partial resolution of the upgaze paresis was noted over the following 2 months. During the next 18 months, the patient demonstrated additional signs and symptoms—including right hand numbness, right-sided hyperreflexia, and left facial numbness in the distribution of all three divisions of the trigeminal nerve—consistent with a diagnosis of clinically definite MS.

## Discussion

Parinaud syndrome most commonly involves paresis or palsy of upward vertical gaze, pupillary abnormalities, and various forms of nystagmus, though multiple other signs can be detected by an experienced examiner (8–10).

The posterior commissure of the midbrain is believed to be the anatomic structure most commonly involved in this syndrome (11). The fibers that control vertical gaze project from the paired paramedian rostral interstitial nuclei of the medial

Received June 22, 1992; revision requested September 14; revision received October 6 and accepted October 20.

<sup>1</sup> Department of Radiology and <sup>2</sup> Departments of Ophthalmology and Neurology, University of Michigan Hospitals, Ann Arbor, MI 48109-0030.

<sup>3</sup> Address reprint requests to Douglas J. Quint, MD, B1D530H, Neuroradiology, University of Michigan Hospitals, 1500 East Medical Center Drive, Ann Arbor, MI 48109-0030.



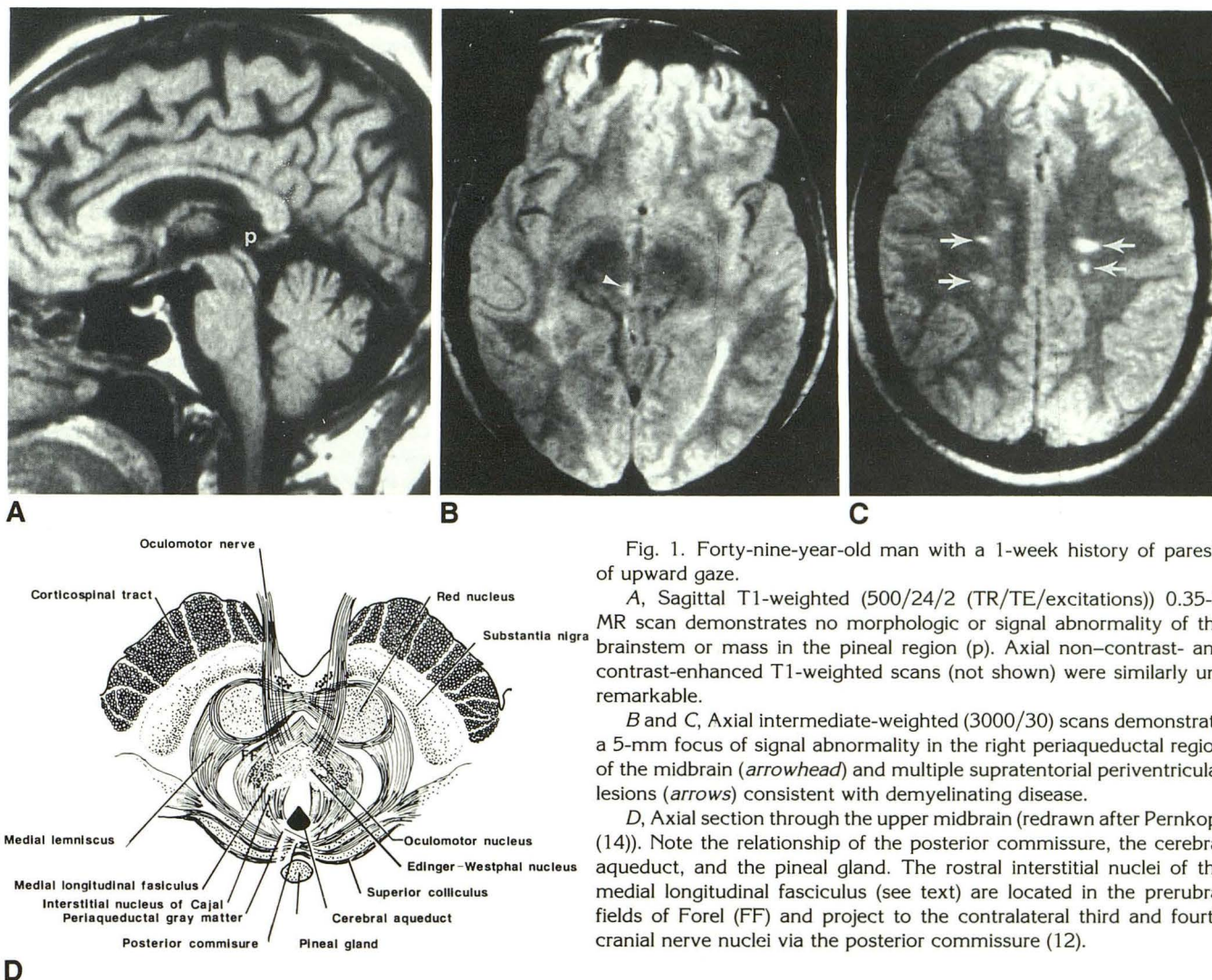


Fig. 1. Forty-nine-year-old man with a 1-week history of paresis of upward gaze.

A, Sagittal T1-weighted (500/24/2 (TR/TE/excitations)) 0.35-T MR scan demonstrates no morphologic or signal abnormality of the brainstem or mass in the pineal region (p). Axial non-contrast- and contrast-enhanced T1-weighted scans (not shown) were similarly unremarkable.

B and C, Axial intermediate-weighted (3000/30) scans demonstrate a 5-mm focus of signal abnormality in the right periaqueductal region of the midbrain (arrowhead) and multiple supratentorial periventricular lesions (arrows) consistent with demyelinating disease.

D, Axial section through the upper midbrain (redrawn after Pernkopf (14)). Note the relationship of the posterior commissure, the cerebral aqueduct, and the pineal gland. The rostral interstitial nuclei of the medial longitudinal fasciculus (see text) are located in the prerubral fields of Forel (FF) and project to the contralateral third and fourth cranial nerve nuclei via the posterior commissure (12).

longitudinal fasciculus posteromedially to cross the midline in the posterior commissure, which is located within the tectum of the midbrain between the cerebral aqueduct and the pineal gland (Fig. 1D) (8, 11–12). After crossing the midline, these fibers project to the contralateral third and fourth cranial nerve nuclei (12).

Frank destruction of, infiltration into, or simple mass effect upon either the posterior commissure or both rostral interstitial nuclei of the medial longitudinal fasciculus can result in dysfunction and Parinaud syndrome. The most common causes of this syndrome include: 1) pineal or posterior third ventricular region lesions with direct invasion or mass effect upon the posterior commissure region; 2) hydrocephalus of any etiology, which results in stretching of the posterior commissure; and 3) cerebrovascular disease resulting in ischemia or infarction in the

region of the posterior commissure (1, 13). However, many additional less common causes of this syndrome have been reported, including intrinsic midbrain lesions such as tumor, hemorrhage, degenerative change (eg, progressive supranuclear palsy), infection, and demyelinating disease.

MS previously has been reported as presenting with Parinaud syndrome (2), though CT scanning was negative and MR imaging was not performed in that case. As imaging is often performed early during the work-up of these patients, and as major radiology textbooks (3–7) appear to discuss this syndrome only in association with pineal region masses, this case emphasizes the importance of also considering intrinsic brainstem abnormalities in these patients. Therefore, in patients who present with Parinaud syndrome, in addition to ruling out masses in the pineal or posterior third ventricular regions, it is necessary



to evaluate the brain stem with proton-density and T2-weighted MR imaging to search for non-contour-deforming, non-contrast-enhancing lesions that might otherwise be missed if only CT scanning is performed.

## References

1. Keane JR. The pretectal syndrome: 206 patients. *Neurology* 1990;40:684-690
2. Slyman JF, Kline LB. Dorsal midbrain syndrome in multiple sclerosis. *Neurology* 1981;31:196-198
3. Kortman K, Bradley WG. Supratentorial neoplasms. In: Stark DD, Bradley WG, eds. *Magnetic resonance imaging*. St. Louis: Mosby, 1988:375-424
4. Berman SA, Hayman LA, Hinck VC. Cerebral vascular territories: anatomic-functional correlation with axial and coronal images. In: Latchaw RE, ed. *MR and CT imaging of the head, neck and spine*. 2nd ed. St. Louis: Mosby/Year Book, 1991:45-62
5. Atlas S. Intraaxial brain tumors. In: Atlas S, ed. *Magnetic resonance imaging of the brain and spine*. New York: Raven, 1991:223-326
6. Williams AL. Tumors. In: Williams AL, Haughton VM, eds. *Cranial computed tomography: a comprehensive text*. St. Louis: Mosby, 1985:148-239
7. Barkovich AJ, Edwards MSB. Brain tumors of childhood. In: Barkovich AJ, ed. *Pediatric neuroimaging*. New York: Raven, 1990:149-203
8. Leigh RJ, Zee DS. *Contemporary neurology series: the neurology of eye movements*. Vol 23. 2nd ed. Philadelphia: Davis, 1991:439-444
9. Costantino A, Black SE, Carr T, Nicholson RL, Noseworthy JH. Dorsal midbrain syndrome in multiple sclerosis with magnetic resonance correlation. *Can J Neurol Sci* 1986;13:62-65
10. Glaser JS, Bachynski B. Infranuclear disorders of eye movement. In: Glaser JS, ed. *Neuro-ophthalmology*. 2nd ed. Philadelphia: Lippincott, 1990:361-418
11. Buttner-Ennever JA, Buttner U, Cohen B, Baumgartner G. Vertical gaze paralysis and the rostral interstitial nucleus of the medial longitudinal fasciculus. *Brain* 1982;105:125-149
12. Lavin PJM. Conjugate and disconjugate eye movements. In: Walsh TJ, ed. *Neuro-ophthalmology: clinical signs and symptoms*. Philadelphia: Lea & Febiger, 1985:412-421
13. Poppen JL, Marino R. Pinealomas and tumors of the posterior portion of the third ventricle. *J Neurosurg* 1968;28:357-364
14. Pernkopf E. Cross section of the midbrain through the superior colliculi. In: Ferner H, ed. *Atlas of topographical and applied human anatomy. Head and neck*. Vol 1. 2nd ed. Baltimore: Urban and Schwarzenberg, 1980:plate 104