



## Discover Generics

Cost-Effective CT & MRI Contrast Agents



FRESENIUS  
KABI

[VIEW CATALOG](#)

# AJNR

## **Bilateral nasolacrimal duct mucocele, a rare cause of respiratory distress: CT findings in two newborns.**

M Castillo, D F Merten and M C Weissler

*AJNR Am J Neuroradiol* 1993, 14 (4) 1011-1013

<http://www.ajnr.org/content/14/4/1011>

This information is current as  
of September 1, 2025.

# Bilateral Nasolacrimal Duct Mucocele, a Rare Cause of Respiratory Distress: CT Findings in Two Newborns

Mauricio Castillo,<sup>1</sup> David F. Merten,<sup>1</sup> and Mark C. Weissler<sup>2</sup>

**Summary:** Two newborns presented with severe respiratory distress caused by nasal obstruction. CT showed bilateral soft-tissue masses located under the inferior turbinates at the level of the inferior meatuses. Histologic examination showed the lesions to be compatible with nasolacrimal mucoceles. The embryology and radiographic features of this rare anomaly are discussed.

**Index terms:** Mucocele; Nose, abnormalities and anomalies; Nose, computed tomography; Pediatric neuroradiology

Nasolacrimal duct mucoceles are rare lesions that may cause severe respiratory obstruction in newborns (1, 2). Computed tomography (CT) is the diagnostic method of choice in the evaluation of the newborn with nasal obstruction.

## Case Reports

### Case 1

A newborn boy, the product of a normal pregnancy and 39 weeks of gestation, presented with progressive nasal congestion and respiratory distress during the first day of life. A 5-F nasogastric tube was passed through both nares. CT performed with 3-mm sections oriented parallel to the hard palate showed bilateral cyst-like masses located caudally to both inferior turbinates (Figs. 1A and C). At surgery, palpation revealed the masses to be soft and they were totally removed with forceps. There was mucoid material inside the lesions. Histologic examination of the walls of the masses showed tissues composed of a fibrovascular stroma with mild inflammatory changes. A trichrome stain showed fibrosis but no glial elements. After surgery, the patient did well and required no further treatment.

### Case 2

A newborn boy, the product of a normal pregnancy and 40 weeks of gestation, developed severe nasal obstruction with a marked decrease in O<sub>2</sub> saturation (at room air) 3 hours after birth, requiring oral intubation. CT with 3-mm

sections parallel to the hard palate showed bilateral smooth soft-tissue masses contiguous with the lateral walls of the nasal cavity (Figs. 2A and 2B). With the patient under general anesthesia, the cysts were marsupialized and their walls were resected. Histologic examination revealed respiratory and squamous-type epithelium with underlying fibrocellular connective tissue, seromucous glands, and mild acute inflammatory changes. Two years after surgery, the patient is doing well.

## Discussion

In the newborn, masses that might obstruct the nasal passages include: hemangiomas, encephaloceles, nasal gliomas, neurofibromas, lymphangiomas, and nasolacrimal duct mucoceles (1). Bilateral nasolacrimal-duct mucoceles (NLDMs) are extremely rare. However, mucoceles involving the lacrimal sac bilaterally have been previously described (2).

NLDMs may be congenital or, less commonly, may develop secondarily to inflammation and/or edema (1). Other causes include abnormal folds in the mucosa and an abnormal development of cartilage and/or bone (3). Embryologically, canalization of the ectodermal lining of the nasooptic fissures begins in the third intrauterine month (4). Their proximal portions will form the canaliculi, which in turn join the puncta (tiny orifices) with the lacrimal sacs via the sinuses of Maier. The distal portions will form the nasolacrimal ducts. Canalization is completed anywhere from the sixth intrauterine month to several months postpartum (3). It is believed that an adequate respiratory effort and crying immediately after birth are factors that may collaborate in establishing the patency of the lacrimal duct (5). Although lack of lacrimal duct patency is believed to be present in 6% to 73% of newborns,

Received September 23, 1992; revision requested December 29, received January 19, 1993, and accepted February 8.

Department of Radiology<sup>1</sup> and the Division of Head and Neck Surgery,<sup>2</sup> University of North Carolina School of Medicine, Chapel Hill, NC 27599. Address reprint requests to M. Castillo, MD, Section of Neuroradiology, Department of Radiology, CB# 7510, University of North Carolina, Chapel Hill, NC 27599-7510.

AJNR 14:1011-1013, Jul/Aug 1993 0195-6108/93/1404-1011 © American Society of Neuroradiology



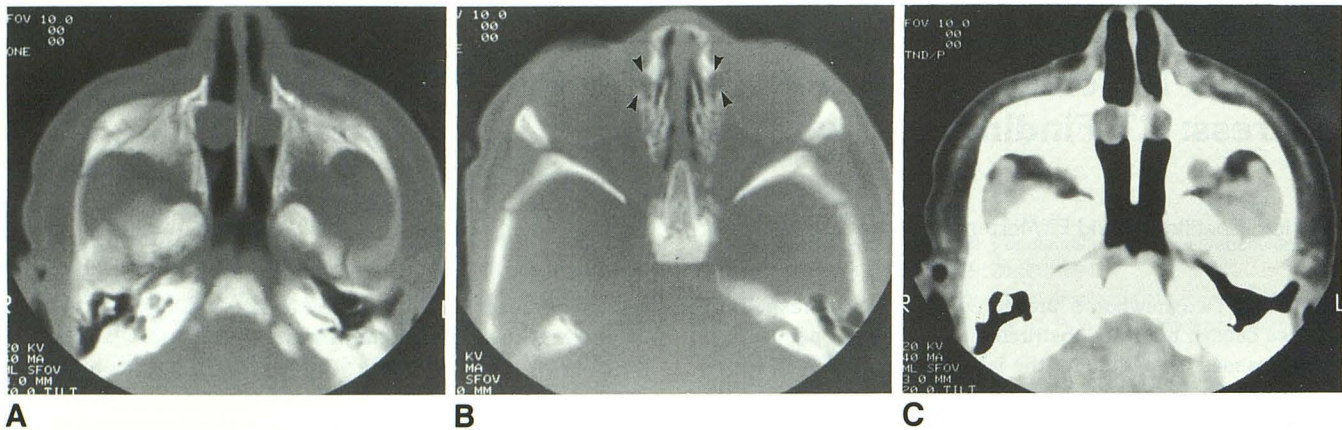


Fig. 1. Patient 1.

A, Axial CT section (bone settings) shows bilateral rounded, smooth, and well-margined masses located anteriorly and caudally to the inferior turbinates in the region of the inferior meatuses. Note that these masses completely obstruct the air passages.

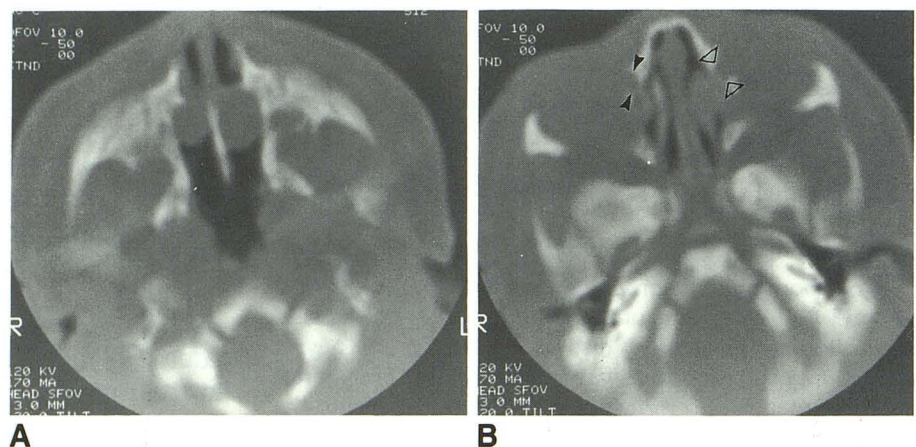
B, Axial CT section above that shown in (A) showing the normal appearance of the lacrimal fossae (*arrowheads*).

C, Soft-tissue window at the same level as that shown in (A) demonstrating that the masses are homogeneous and of low density, suggesting their cystic nature.

Fig. 2. Patient 2.

A, Axial CT section (bone settings) shows bilateral smooth soft-tissue density masses compatible with NLDM. There is complete occlusion of the nasal passages. Although septal bowing is seen with unilateral lacrimal duct mucocoeles, it was not present in our cases.

B, Axial CT section slightly above that shown in (A) showing normal configuration of the right lacrimal fossa (*solid arrowheads*) and questionable minimal enlargement of the left fossa (*open arrowheads*).



most ducts open spontaneously during the first year of life (1, 5). Obstruction at any level of the apparatus of nasolacrimal drainage may give rise to an accumulation of secretions with subsequent formation of mucocoeles. For example, proximal obstruction may produce a lacrimal sac mucocoele, whereas a more distal blockade may cause NLDMs. Lack of canalization resulting in obstruction of the valves of Hasner in the most distal portion of the nasolacrimal ducts is the basis for the development of NLDMs (Fig. 3). A mucocoele of the nasolacrimal apparatus may extend either superiorly or caudally; that is, mucocoeles of the lacrimal sac may protrude downward into the duct, or a mucocoele arising in the duct may extend upward to involve the lacrimal sac. All mucocoeles involving the lacrimal sac present clinically as medial canthal masses. In a series of four patients, all nasolacrimal-apparatus mucocoeles

presented with the characteristic triad of a cystic medial canthal mass, dilatation of the lacrimal duct, and a low, intranasal, submucosal mass located under the inferior turbinate (1). The skin overlying these mucocoeles may show a blue discoloration (3). Mucocoeles arising from the lacrimal sac are difficult to differentiate from amniocoeles, in which the sac is filled with amniotic fluid, immediately after birth (2, 3). Because both entities require similar treatment, it is not imperative to differentiate between them. All mucocoeles of the lacrimal apparatus may become infected (pyocoeles).

Our two cases are unusual not only because of the bilaterality of the process, but also because these mucocoeles were isolated to the distal nasolacrimal ducts. Moreover, the initial CT was obtained because these patients were thought to have choanal abnormalities. In both cases, CT



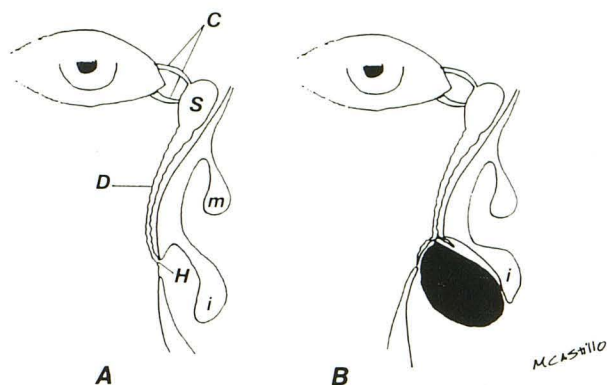


Fig. 3. The normal lacrimal apparatus (A) is formed by puncta, which open into the canaliculi (C). The canaliculi in turn empty into the lacrimal sac (S), which continues inferiorly with the lacrimal duct (D). The most distal aspect of the lacrimal duct opens into the inferior meatus (under the inferior turbinate [i]) via the valve of Hasner (H). *m* indicates middle turbinate. In the patient with a lacrimal duct mucocele (B), the valve of Hasner does not undergo normal canalization and is therefore occluded. Accumulation of secretions (*dark zone*) expands the distal duct, giving rise to a mass that displaces the inferior turbinate (i). Kinking of the thickened and inflamed mucosa in the upper portion of the mucocele prevents the extension of secretions into the proximal lacrimal apparatus.

showed well-marginated, round, cyst-like masses in the anteroinferior nasal cavities just below the inferior turbinates (Figs. 1A and 2A). The superior aspects of the lacrimal ducts and the sacs were

normal in both patients, and postoperative stenting was not required (Figs. 1B and 2B). Therefore, obstruction of the valves of Hasner was probably responsible for the formation of NLDMs in our patients. Because both of our patients were newborns, we believe that the inflammatory changes seen at histology probably occur postnatally and do not represent the primary cause for the formation of NLDM. Although both dacryocystography and ultrasound have been used to establish the cystic nature of these masses (2, 3, 6), we believe that CT is the diagnostic method of choice in the evaluation of the newborn with nasal obstruction.

## References

1. Rand PK, Ball WS, Lulwin DR. Congenital nasolacrimal mucoceles: CT evaluation. *Radiology* 1989;173:691-694
2. Divine RD, Anderson RL, Bumstead RM. Bilateral congenital lacrimal sac mucoceles with nasal extension and drainage. *Arch Ophthalmol* 1983;101:246-248
3. Scott WE, Fabre JA, Ossoining KC. Congenital mucocele of the lacrimal sac. *Arch Ophthalmol* 1979;97:1656-1658
4. Cassady JV. Developmental anatomy of nasolacrimal duct. *Arch Ophthalmol* 1952;47:141-158
5. Guerry D, Kendig EI. Congenital impatency of the nasolacrimal duct. *Arch Ophthalmol* 1948;39:193-202
6. Cibis GW, Spurney RO, Waeltermann J. Radiographic visualization of congenital lacrimal sac mucoceles. *Ann Ophthalmol* 1986;18:68-69