



Get Clarity On Generics

Cost-Effective CT & MRI Contrast Agents



FRESENIUS
KABI

WATCH VIDEO

AJNR

Noninvasive detection of increased glycine content by proton MR spectroscopy in the brains of two infants with nonketotic hyperglycinemia.

W Heindel, H Kugel and B Roth

AJNR Am J Neuroradiol 1993, 14 (3) 629-635

<http://www.ajnr.org/content/14/3/629>

This information is current as
of August 28, 2025.

Noninvasive Detection of Increased Glycine Content by Proton MR Spectroscopy in the Brains of Two Infants with Nonketotic Hyperglycinemia

Walter Heindel,^{1,3} Harald Kugel,¹ and Bernhard Roth²

Summary: Using localized ¹H-MR spectroscopy (¹H-MRS) an inborn error of metabolism within human brain could be demonstrated, while ¹H-MR imaging did not show any pathologic findings like demyelination. In two children suffering from nonketotic hyperglycinemia, the proton spectrum exhibited a large glycine signal at 3.55 ppm. In patient 1 (49-day-old girl), the pathologic signal of the inhibitory neurotransmitter glycine was of similar size in the parietooccipital white matter and in the basal ganglia region. In patient 2 (a 10-day-old girl), follow-up studies within the first 4 months of life revealed a time course of cerebral glycine content that differed from the course in plasma and cerebrospinal fluid. The continuing reduction of glycine in brain tissue corresponded more reliably with clinical findings than the stable values in plasma and cerebrospinal fluid. ¹H-MRS allows the noninvasive demonstration of glycine in patients with nonketotic hyperglycinemia. This new technique may be useful to control the effect of a sodium benzoate therapy by monitoring the cerebral glycine concentration directly.

Index terms: Magnetic resonance, spectroscopy; Brain, metabolism; Magnetic resonance, in infants and children

Nonketotic hyperglycinemia (NKH) is an autosomal recessive disorder of glycine metabolism characterized by elevated concentrations of glycine in plasma, cerebrospinal fluid (CSF), and urine (1, 2). NKH is classified into two forms of clinical presentation and onset: neonatal type and late-onset type. The neonatal type is more common, and clinical manifestations of glycine-induced encephalopathy include seizures, muscular hypotonia, lethargy, coma, and respiratory failure. Most patients with the neonatal form die within a few weeks, whereas the survivors show severe mental retardation.

The metabolic defect is located in the glycine cleaving system, a four-protein complex responsible for the interconversion of the amino acids, glycine and serine. The activity of this enzyme system is deficient in the liver and brain of affected patients (3, 4).

Proton magnetic resonance spectroscopy (¹H-MRS) has recently become available for clinical examinations of the human brain. This method opens the way to a noninvasive biochemical characterization of tissue by showing normal and pathologic metabolite patterns. Apart from metabolic information on tumors (5–9) or infarcts (10, 11), ¹H-MRS provides a new tool for examination of metabolic diseases that alter compounds visible in the spectrum like Canavan disease (12–14). This report shows that ¹H-MRS can be used as a means to measure glycine directly and noninvasively in vivo in the brain tissue of patients suffering from NKH.

Subjects and Methods

Patient 1

After delivery at 39 weeks of uneventful gestation a newborn girl developed lethargy, seizures, and respiratory distress on the third day of life. Her birth weight was 2,610 g. Since birth, the patient had muscular hypotonia, showed only a few spontaneous movements, and refused oral feeding.

The electroencephalogram showed a burst suppression pattern. Glycine level in the plasma was 1,105 $\mu\text{mol/L}$, and in the CSF was 161 $\mu\text{mol/L}$. These levels were determined with an interassay error of less than 5%. The ratio of CSF to plasma glycine concentration (CSF/P) was elevated with 0.14, and diagnostic for NKH. Ketoacidosis and organic acidemia could be excluded. On the 49th day of life, the infant was transferred to our hospital for ¹H-MRS.

Received December 18, 1991; accepted after revision September 2, 1992.

This study was supported by the Deutsche Forschungsgemeinschaft (DFG).

¹ Department of Diagnostic Radiology, University of Cologne, Köln, Federal Republic of Germany.

² Children's Hospital, University of Cologne, Köln, Federal Republic of Germany.

³ Address reprint requests to Priv-Doz Dr. Walter Heindel, Department of Radiology, University of Cologne, Joseph-Stelzmann-Str. 9, D-5000 Köln 41, Federal Republic of Germany.

Patient 2

A newborn girl presented after an uneventful gestation and spontaneous delivery at term on the third day of life with hypotonia, seizures, and respiratory distress. Her birth weight was 3,100 g. Electroencephalogram showed a burst suppression pattern. Glycine content in plasma was 1,904 $\mu\text{mol/L}$, and in CSF, was 407 $\mu\text{mol/L}$. The ratio of CSF to plasma glycine concentration was 0.21, and diagnostic for NKH. There were no findings indicating ketoacidosis, and organic acidemia could be excluded by gas chromatography-mass spectroscopy (Dr Lehnert, Children's Hospital, University of Freiburg, FRG, personal communication).

In healthy children, glycine levels in plasma have been determined as $209 \pm 46 \mu\text{mol/L}$, and in CSF, $5.2 \pm 2.0 \mu\text{mol/L}$. The normal ratio of CSF/P is 0.02 (15).

MR Examinations

Investigations were performed using a clinical 1.5-T whole-body MR system (Gyrosan S15, Philips Medical Systems, Best, The Netherlands) operating at 63.86 MHz for protons. Sedation was achieved by pentobarbital administered intravenously. The parents gave their informed written consent for the studies.

The standard 30-cm diameter ^1H mirror head coil, a linearly polarized coil equipped with a reflective radio-frequency screen at the cranial end, was used for imaging and spectroscopy. ^1H -MR imaging in two section orientations preceded spectroscopy to define the volume of interest (VOI). T1-weighted (300/15/2, TR/TE/excitations) and T2-weighted (1700/100/1) spin-echo sequences were used. Following volume-selective shimming to line widths of 4 Hz, spectra were taken from a VOI centered around the basal ganglia or located in parietooccipital white brain matter, using a spatially selective 90° - 180° - 180° Hahn double spin-echo sequence (16, 17). To suppress the water signal, a frequency-selective inversion pulse at the water resonance preceded the volume-selective spin-echo sequence (18) that started when the inverted water signal crossed the zero line. The zero-crossing time was adjusted individually for each spectrum and ranged from 565 msec to 595 msec.

Spin-echo times (TE) used were 136 msec. Two hundred fifty-six averages were obtained with a repetition time (TR) of 2 seconds, resulting in an acquisition time of 8 minutes 32 seconds for a spectrum. One thousand twenty-four data points were sampled with a sampling frequency of 1000 Hz, resulting in a spectral resolution of 0.98 Hz per point. Only the second half of the echo was acquired to allow a phase-sensitive evaluation.

A lorentzian line broadening of 2 Hz and zero order phase correction was applied to all spectra. In cases of suboptimal water suppression, the signals sit on the slope of the residual water signal. An interactive baseline correction reestablished a flat baseline in these spectra. Chemical shifts δ are expressed relative to tetramethylsilane (set to 0 ppm), using the signals of *N*-acetylaspartate (NAA) ($\delta = 2.02$ ppm) or choline ($\delta = 3.21$ ppm) as internal standards.

Spectra were evaluated by comparing signal intensities of the (real) resonance signals. Peak areas of the singulett signals were calculated using the product of peak and line width at half maximum, assuming lorentzian line shape. Peak heights were determined relative to a flat baseline drawn manually through the noise. Because of a not unequivocal definition of the baseline, the accuracy of area determination is limited to 5% to 10%.

Results

The prominent signals in a normal spectrum from infant brain originate from NAA at 2.02 ppm, creatine and phosphocreatine (Cr) at 3.04 ppm, and choline-containing compounds (Cho) at 3.21 ppm. As an example, Figure 1 gives the spectrum of a 5-week-old girl without known metabolic disorder. Whereas in adult brain the NAA causes the largest signal with an intensity ratio of NAA to Cho of about 2, here the NAA signal is smaller than the Cho signal. The NAA/Cho ratio increases with age (19).

Patient 1 was examined on the 49th day of life. MR imaging showed no pathologic findings like delayed myelination. One spectrum was taken from a volume of $5 \times 3 \times 5$ cm around the basal ganglia. It exhibited a signal at 3.56 ppm of about half the intensity of the creatine signal. On the basis of its chemical shift, this singulett was assigned to glycine (Gly/Cr = 0.53) (Fig. 2B). An inositol resonance near this frequency that originates from a coupled multiplett signal and can be detected at short echo times does not show up in spectra with TE = 136 (Fig. 1). In a second spectrum from a $2 \times 2 \times 2$ -cm cube located in

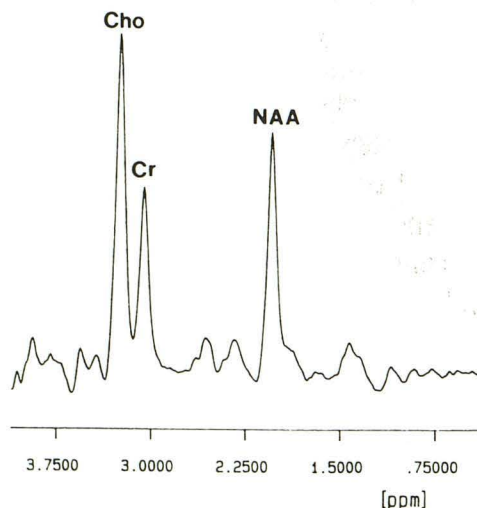


Fig. 1. Normal ^1H -MR spectrum from an 11-mL VOI around the left basal ganglia of a 36-day-old girl without metabolic disease.

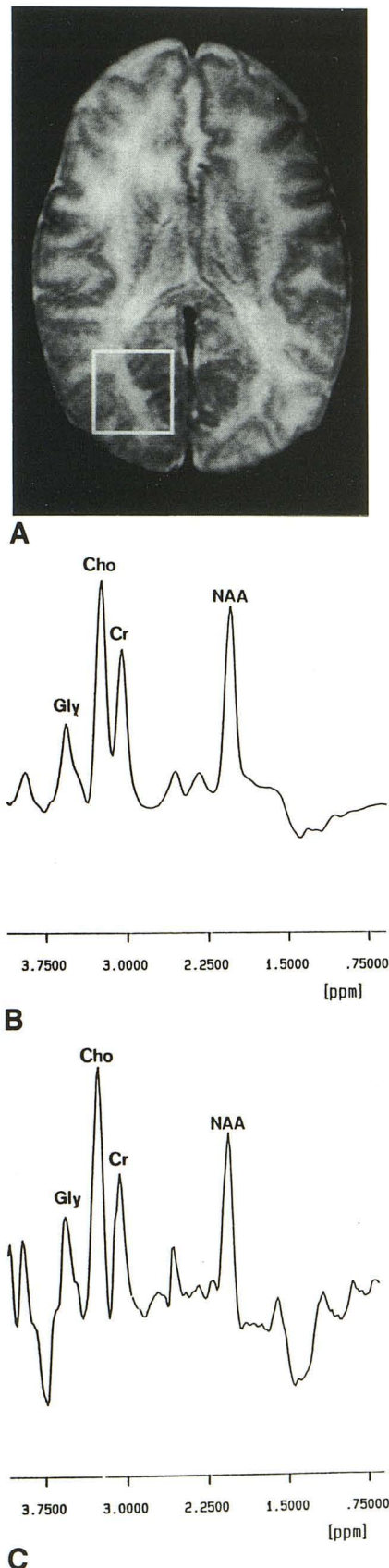


Fig. 2. A 49-day-old girl suffering from NKH (patient 1). A, Transverse T2-weighted spin-echo image showing normal

the parietooccipital region (Fig. 2A), a glycine signal of a slightly larger intensity was present ($\text{Gly/Cr} = 0.64$) (Fig. 2C). Glycine levels in plasma and CSF at that day were $852 \mu\text{mol/L}$ and $76 \mu\text{mol/L}$, respectively. At that time, the treatment was limited to protein restriction (1.2 g/kg body weight per day) and diazepam only.

Patient 2 was 10 days old when the first MR examination was performed. As in the first case, from a morphologic point of view there were no pathologic findings like an abnormal thin corpus callosum. Again the proton spectrum taken from a volume of $3 \times 3 \times 4 \text{ cm}$ around the basal ganglia (Fig. 3A) exhibited a glycine signal at 3.56 ppm of an intensity in the order of the creatine signal ($\text{Gly/Cr} = 0.99$) (Fig. 3B).

Subsequent measurements were performed at the age of 31 days, 45 days, and 105 days, positioning the VOI at the same location. The glycine signal showed a steady decrease of the signal intensity as compared with creatine (0.62, 0.42, 0.30) (Fig. 3B). Similarly, glycine decreased compared to the other metabolite signals visible in the spectra apart from the last spectrum taken at the 105th day. In this spectrum, the ratios Gly/Cho and Gly/NAA exhibited about the same value as in the spectrum from the 45th day, whereas Gly/Cr decreased, probably due to a significant increase of the Cr signal relative to the other signals.

Glycine levels in plasma and CSF showed a decrease from the 10th to the 31st day, similar to the MRS values (Table 1). After the 31st day, there was no significant change of these figures. The child was treated with a protein restriction diet (1.20 g/kg body weight per day), diazepam, and strychnine sulfate (0.6 mg/kg body weight per day). At the 31st day of life, sodium benzoate therapy was introduced with a dose of 150 mg/kg body weight per day and was enhanced to 300 mg/kg body weight per day at day 47. Subsequent gas chromatography-mass spectroscopy examinations on the 31st, the 45th, and the

myelination and no signs of cerebral atrophy. The location of the VOI ($2 \times 2 \times 2 \text{ cm}$) in the parietooccipital region is indicated.

B, ^1H -MR spectrum from a 75-mL VOI around the basal ganglia of this patient. Note the signal at 3.55 ppm assigned to glycine. The ratios of the peak intensities of Cho, Cr, and NAA correspond to this age group.

C, ^1H -MR spectrum from the 8-mL VOI in the parietooccipital region of the patient as indicated in A. A glycine signal of similar intensity can again be identified. The inverted signals at 1.3 ppm in both spectra probably originate from lactate, although there may be interferences from lipids.

TABLE 1: Clinical, biochemical, and ¹H-MRS data of two female infants suffering from the neonatal form of nonketotic hyperglycinemia

Age (days)	Sodium Benzoate (mg/(kg birth weight × day))	Glycine Concentration		Ratio CSF/Plasma	MRS Signal Intensity Ratios				Cerebral Glycine Concentration (mmol/L)	Clinical Findings
		Plasma (μmol/L)	CSF (μmol/L)		Gly/Cr	Gly/Cho	Cr/Cho	NAA/Cho		
Patient 1 49	0	852	76	0.09	0.53 0.64 ^a	0.36 0.41 ^a	0.67 0.65 ^a	0.91 0.77 ^a	4.0 4.8 ^a	Moderate hypertonic and hyperreflexive, seizures up to 10/day
Patient 2 10	0	2200	407	0.18	0.99	0.62	0.63	0.74	7.4	Comatous, ventilatory support, no spontaneous movements, severe hypotonia, no seizures recognized
31	150	1098	257	0.23	0.62	0.39	0.63	0.66	4.7	Spontaneous breathing, few movements, marked hypotonia
45	150	1386	273	0.20	0.42	0.29	0.68	1.10	3.2	Again ventilated, few spontaneous movements, moderate hypotonia, seizures up to 30/day
105	300	1141	190	0.17	0.30	0.28	0.95	0.81	2.3	Severe mental retardation, hypertonic, hyperreflexive, seizures up to 20/day

Note.—Cerebral glycine concentrations are calculated from signal intensities using creatine with an assumed concentration of 5 mmol/L as internal standard.

^a Occipital white matter.

105th day revealed plasma glycine concentration of 1,098, 1,386, and 1,141 μmol/L. From these values, CSF/P ratios of 0.23, 0.20, and 0.17 were calculated. The clinical course was characterized by a severe encephalopathy and respiratory failure during the first 5 weeks of life and the need for artificial ventilation for 13 days. When the patient reached the age of 3 months, the electroencephalogram pattern changed to hypsarrhythmia. Further details of the clinical course are given in Table 1.

Discussion

Glycine is a nonessential amino acid and acts as an inhibitory neurotransmitter at glycinergic receptor sites in the central nervous system, ie, spinal cord, brain stem, basal ganglia, and cerebral cortex (20). Furthermore, glycine is a coactivator at the excitatory *N*-methyl-D-aspartate receptor sites (21). In excessive concentrations, ie, nonketotic hyperglycinemia, a glycine-induced encephalopathy and neuropathy develops. The glycine cleavage system which catalyzes the transformation of glycine to CO₂, NH₃, and methylenetetrahydrofolate was found to be markedly diminished or absent in the liver and in the brain from patients suffering from NKH (1, 3); in ketotic hyperglycinemia, it is reduced in the liver tissue only.

Striking similarities exist between NKH and other aminoacidopathies on pathologic and MR examinations. MR findings of central nervous system atrophy and delayed myelination in patients with NKH are age-related and similar to those reported on pathologic examination. The cerebral atrophy, spongy myelinopathy, and retarded myelination demonstrated at pathology are seen also in methylmalonic and propionic acidemia, maple syrup urine disease, tyrosinemia, phenylketonuria, and hyperbetaalaninemia (22).

Both patients described in the paper were suffering from the neonatal form of NKH and presented with severe glycine-induced encephalopathy, although MR imaging at the time of examination did not yet show parenchymal volume loss.

In both patients, ¹H-MRS enabled one to quantify glycine content within the brain. The absolute concentration of glycine can be estimated using Cr as an internal standard:

Assuming a Cr concentration in the brain of about 5 mmol/L (5.2 mmol/L measured for a 6-month-old child (23)) and considering the fact that two protons contribute to the signal of glycine instead of three to creatine the measured glycine intensity in patient 2, a concentration of about 7.4 mmol/L at the first measurement, is indicated, provided the relaxation times of creatine and glycine are in the same order. Subse-

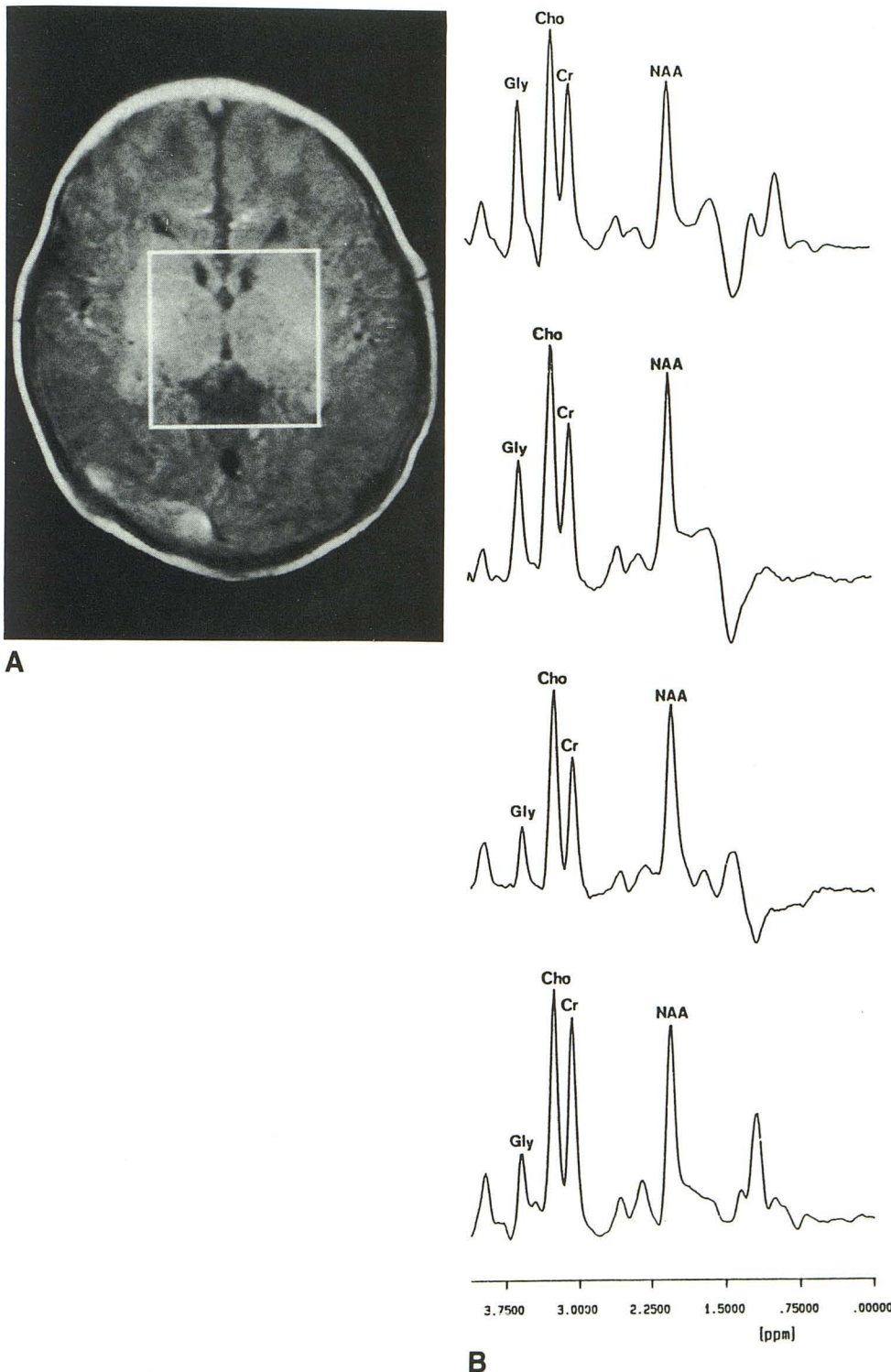


Fig. 3. Follow-up studies in a female infant (patient 2).

A, Transverse T1-weighted spin-echo image of the 10-day-old patient showing appropriate brain development. The VOI ($3 \times 3 \times 4$ cm) around the basal ganglia used for the first and all subsequent measurements is indicated.

B, ^1H -MR spectra from patient 2, taken at the 10th, 31st, 45th, and 105th day of life (top to bottom). Note the steady decrease of the glycine signal at 3.55 ppm. Unidentified structures are visible between 0.8 and 1.5 ppm and may originate from lipids. The inverted signals at 1.3 ppm in the first two spectra may indicate lactate.

quently this concentration falls to 4.7, 3.2, and 2.3 mmol/L, respectively, assumed that Cr concentration was unchanged during that time period. These concentrations are comparable to the glycine content determined from excised brain tissue (4.1 mmol/kg ww (wet weight) in the

cerebrum and 11.4 mmol/kg ww in the cerebellum in a case reported by Bachman et al (24), 3.55 mmol/kg ww and 4.24 mmol/kg ww in the occipital cortex in two cases reported by Perry et al (15)). In contrast to NKH, normal glycine concentrations in postmortem cerebral tissue of chil-

dren were found as 1.77 mmol/kg ww (24) to 2.09 mmol/kg ww (15). Assuming a cerebral water content of 80%, these values have to be multiplied by 1.25 to obtain the concentrations given in mmol/L.

The concentration values given here must be interpreted keeping in mind some possible sources of error. Whereas relative values can be given with the accuracy of the measurement of the peak area, absolute values depend on the assumption of similar relaxation times and the correct concentration assigned to the Cr signal used as internal standard. The increase of Cr relative to all other values in the spectrum of the 105th day possibly reflects an increase of Cr content rather than a further decrease of glycine. This interpretation would result in a glycine concentration of 3.2 mmol/L—as at the 45th day—and 7 mmol/L Cr instead of 5 mmol/L. An age-related increase of Cr is possible (19, 23) and may have occurred during the 60-day period between the third and fourth measurement. The ratios of the signal intensities of Cho, Cr, and NAA in the four measured spectra do not differ from the ratios measured in children of similar age without metabolic diseases (Kugel H, Heindel W, Roth B, unpublished data). In spite of these uncertainties, comparison of brain glycine concentrations with CSF and plasma concentrations show that CSF glycine levels are lower by more than an order of magnitude, while plasma concentrations are about 1/4 to 1/2 of cerebral tissue concentration.

For the first patient, glycine concentration can be estimated as 4.0 mmol/L in the basal ganglia and as 4.8 mmol/L in occipital white matter, provided Cr concentration is the same at both locations.

Although in patient 2 the glycine concentration in plasma and CSF after the first month of life were found relatively constant, the estimated glycine concentrations in the cerebral tissue show a further decline up to an age of 105 days. As it is shown in Table 1, cerebral glycine content determined by ^1H -MRS corresponds more reliably with clinical findings that glycine concentrations found in plasma or CSF. It seems unlikely that strychnine has any measurable influence on cerebral glycine content detectable by ^1H -MRS. On the other hand, the effect of sodium benzoate on glycine elimination from brain tissue has to be taken into account. The hepatic enzyme glycine acyltransferase (EC 2.3.1.13), absent in brain, catalyzes the conjugation of glycine and benzoate. Using considerable doses of sodium benzoate, Wolff et al (25) have achieved a decrease

of CSF concentrations of glycine. In patient 2, treatment with sodium benzoate was started after the 31st day of life and may have contributed to the decrease of glycine content in brain tissue of this patient determined by ^1H -MRS.

In conclusion, in one patient ^1H -MRS noninvasively demonstrates increased glycine levels in two different areas of the brain, while in the other patient, ^1H -MRS reveals a time course of glycine content in brain tissue that differs from the course in plasma and CSF. The continuing reduction of glycine in the tissue seems to correspond to the steady change in the clinical findings better than the stable values in plasma and CSF. Thus ^1H -MRS may be a useful tool to control the effect of glycine-reducing measures like sodium benzoate therapy by monitoring the cerebral glycine concentration directly.

References

1. Tada K, Hayasaka K. Non-ketotic hyperglycinemia: clinical and biochemical aspects. *Eur J Pediatr* 1987;146:221–227
2. Nyhan WL. Nonketotic hyperglycinemia. In: Scriver CR, Beaudet AL, Sly WS, Valle D, eds. *The metabolic basis of inherited disease*. 6th ed. New York: McGraw-Hill, 1989:743–754
3. Tada K, Narisawa K, Yoshida T, et al. Hyperglycinemia: a defect in glycine cleavage reaction. *Tohoku J Exp Med* 1969;98:289–296
4. Kikuchi G. The glycine cleavage system: composition, reaction mechanism, and physiological significance. *Mol Cell Biochem* 1973;1:169–187
5. Bruhn H, Frahm J, Gyngell ML, et al. Non-invasive differentiation of tumors with the use of localized H-1 MR spectroscopy in vivo: initial experience in patients with cerebral tumors. *Radiology* 1989;14:497–504
6. den Hollander JA, Luyten PR. Image-guided localized ^1H and ^{31}P NMR spectroscopy of humans. *Ann NY Acad Sci* 1987;508:386–398
7. Gill SS, Thomas DGT, van Bruggen N, et al. Proton MR spectroscopy of intracranial tumours: in vivo and in vitro studies. *J Comput Assist Tomogr* 1990;14:497–504
8. Arnold DL, Shoubridge EA, Villemure J-G, Feindel W. Proton and phosphorous magnetic resonance spectroscopy of human astrocytomas in vivo: preliminary observations on tumor grading. *NMR Biomed* 1990;3:184–189
9. Kugel H, Heindel W, Ernestus R-I, Bunke J, du Mesnil R, Friedmann G. Spectral patterns of human brain tumors as detected by localized ^1H NMR spectroscopy. *Radiology* 1992;183:701–709
10. Berkelbach J, van der Sprenkel JW, Luyten PR, van Rijen PC, Tulleken CAF, den Hollander JA. Cerebral lactate detected by regional proton magnetic resonance spectroscopy in a patient with cerebral infarction. *Stroke* 1988;19:1556–1560
11. Bruhn H, Frahm J, Gyngell ML, Merboldt KD, Hänicke W, Sauter R. Cerebral metabolism in man after acute stroke: new observations using localized proton spectroscopy. *Magn Reson Med* 1989;9:126–131
12. Grodd W, Krägeloh-Mann I, Petersen D, Trefz FK, Harzer K. In vivo assessment of *N*-acetylaspartate in brain in spongy degeneration (Canavan's disease) by proton spectroscopy (letter). *Lancet* 1990;2:437–438
13. Heindel W, Kugel H, Roth B. Proton spectroscopy reflects metabolic diseases. *Neuropediatrics* 1991;22:171

14. Grodd W, Krägeloh-Mann I, Klose U, Sauter R. Metabolic and destructive brain disorders in children: findings with localized proton MR spectroscopy. *Radiology* 1991;181:173-181
15. Perry T, Urquhart N, MacLean J, et al. Nonketotic hyperglycinemia: glycine accumulation due to absence of glycine cleavage in brain. *N Engl J Med* 1975;292:1269-1273
16. Ordidge RJ, Bendall MR, Gordon RE, Connelly A. Volume selection for in-vivo spectroscopy. In: Govil G, Khetrpal C, Saran A, eds. *Magnetic resonance in biology and medicine*. New Delhi, India: Tata McGraw-Hill, 1985:387-397
17. Bottomley PA. Spatial localization in NMR spectroscopy in vivo. *Ann NY Acad Sci* 1987;508:333-348
18. Patt SL, Sykes BD. T1 water eliminated Fourier transform NMR spectroscopy. *J Chem Phys* 1972;56:3182-3184
19. van der Knaap MS, van der Grond J, van Rijen PC, Faber JAJ, Valk J, Willemse K. Age-dependent changes in localized proton and phosphorus MR spectroscopy of the brain. *Radiology* 1990;176:509-515
20. Naas E, Zilles K, Gnahn H, Betz H, Becker C-M, Schröder H. Glycine receptor immunoreactivity in rat and human cerebral cortex. *Brain Res* 1991;561:139-146
21. Forster AC, Kemp IA. Glycine maintains excitement. *Nature* 1989;338:377-378
22. Press AG, Barshop BA, Haas RH, Nyhan WL, Glass RF, Hesselink IR. Abnormalities of the brain in nonketotic hyperglycinemia: MR manifestation. *AJNR: Am J Neuroradiol* 1989;10:315-321
23. Barker PB, Kumar AJ, Naidu S. ¹H NMR spectroscopy of Canavan's disease (abstr). In: Book of abstracts: Society of Magnetic Resonance in Medicine 1991. Vol 1. Berkeley, CA: Society of Magnetic Resonance in Medicine, 1991:381
24. Bachmann C, Mihatsch MJ, Baumgartner RE, et al. Nicht-ketotische Hyperglycinämie: perakuter Verlauf im Neugeborenenalter. *Helv Paediatr Acta* 1971;3:228-243
25. Wolff JA, Kulovich S, Yu A, Oiao C-N, Nyhan WL. The effectiveness of benzoate in the management of seizures in nonketotic hyperglycinemia. *Am J Dis Child* 1986;140:596